

# Osteoarthritis associated with osteopetrosis treated by total hip replacement arthroplasty

## *Report of a case*

CHET J. JANECKI, M.D.

CARL L. NELSON, M.D.

Department of Orthopaedic Surgery

IN 1904 Heinrich Albers-Schönberg,<sup>1</sup> a German radiologist, reported a case of generalized osteosclerosis and multiple fractures in a 26-year-old patient. The condition constituted a new disease entity which now bears his name. On the basis of the roentgenographic appearance of the bones, Albers-Schönberg described the disorder as "Marmor-Knochen Krankheit" (marble bone disease). The triad of findings considered to be pathognomonic were generalized osteosclerosis, anemia, and lymphadenopathy with hepatosplenomegaly.

Laurell and Wallgren,<sup>2</sup> in 1920, focused attention on the multiple pathologic fractures characteristic of marble bone disease and introduced the term osteosclerosis fragilis generalisata. Karshner,<sup>3</sup> in 1926, introduced the term osteopetrosis to describe the petrified nature of the affected bones. Since then the disease has been reviewed by several authors, and approximately 300 cases have been reported. In a number of instances another disease has been associated with osteopetrosis,<sup>4</sup> for example, leukemia, Hodgkin's disease, sarcoma, coarctation of the aorta, and rickets. However, there has been no detailed description of degenerative joint disease in association with osteopetrosis.

The fragile quality of the dense bone in osteopetrosis causes increased fractures, particularly of the femoral neck in the proximal third of the femoral shaft and the proximal third of the tibia. Despite this fragility and the variability of the healing of fractures, there is little information in regard to difficulties encountered in internal fixation of such fractures.<sup>4, 5</sup> The purpose of this report is to describe a total hip replacement arthroplasty in a patient with Albers-Schönberg disease, and to emphasize the technical difficulties and complications of internal fixation in such patients.

Osteopetrosis is world-wide in distribution.<sup>1</sup> It occurs at all ages, from the prenatal stages<sup>6</sup> through infancy,<sup>7</sup> childhood, and to the eighth decade.<sup>8, 9</sup> The disorder is hereditary and shows a strong familial tendency, as well as a high incidence in parental consanguinity.<sup>8</sup>

McPeak,<sup>8</sup> in 1936, described two different types of osteopetrosis on the

basis of clinical courses: the malignant, childhood form, and the benign, adult form. The malignant form is considered to be an autosomal recessive, the benign form is an autosomal dominant.<sup>10</sup> The common denominator in all cases is sclerosis of bone.

The effects of the osteosclerosis are threefold:<sup>4</sup> (1) invasion and reduction in bone marrow tissue, diminishing hematopoiesis, with resultant anemia, malnutrition and lowered resistance to infection; (2) invasion and reduction in the size of various cranial nerve foramina, occasionally causing complete or partial loss of cranial nerve function; and (3) overproduction of abnormally structured bone leading to fragility and a likelihood of fractures.

In the malignant form of osteopetrosis,<sup>10</sup> the onset is at birth or shortly thereafter. In addition to and secondary to the osteosclerosis of the bone, there may be hydrocephalus, severe anemia, cranial nerve impairment, hepatosplenomegaly, frequent fractures and resultant skeletal deformities. The infant usually is underdeveloped and survives only a few years.

The benign form occurs in adulthood. There may be a history of fractures from minor trauma or the patient may be entirely asymptomatic. Anemia is not common and hepatosplenomegaly is rare. Cranial nerve compression by bony overgrowth of the foramina is unusual. Osteomyelitis of the mandible occurs in about 10 percent of these patients. Patients with the dominant or benign form of this disease can be expected to survive to old age. Laboratory data usually are normal with the exception of an elevated acid phosphatase.

The roentgenographic findings vary with the severity and the extent of the disease.<sup>11</sup> The changes are nonspecific as to the benign or the malignant form.<sup>12</sup> The long bones show a homogeneous, chalky density, with a lack of differentiation between the cortex and the medullary cavity. Transverse and longitudinal striations at the metaphysial ends are frequently seen. The sites of previous epiphyses often contain central, dense nidi producing inner dense bony islands. Clubbing of the metaphysis occurs only in the moderately advanced stage, particularly in the proximal humerus and distal femur. When the skull is affected there is loss of the diploic space between the tables of the bone. The diameter of the skull does not increase, but the base of the skull becomes thickened and is prominent with or without encroachment upon the cranial nerve foramina. The iliac bone of the pelvis shows alternating dense and translucent zones, parallel to the iliac crest resembling growth rings in a tree trunk. In the vertebrae the upper and lower portions of the body show platelike condensations with a translucent zone bisecting the body horizontally, thereby producing a sandwich appearance. The posterior elements are much less involved. In the carpal and tarsal bones the mildest change consists of a dense central nidus resembling a bony island. The peripheral bone about the bony island is usually of normal density. This "bone within a bone"

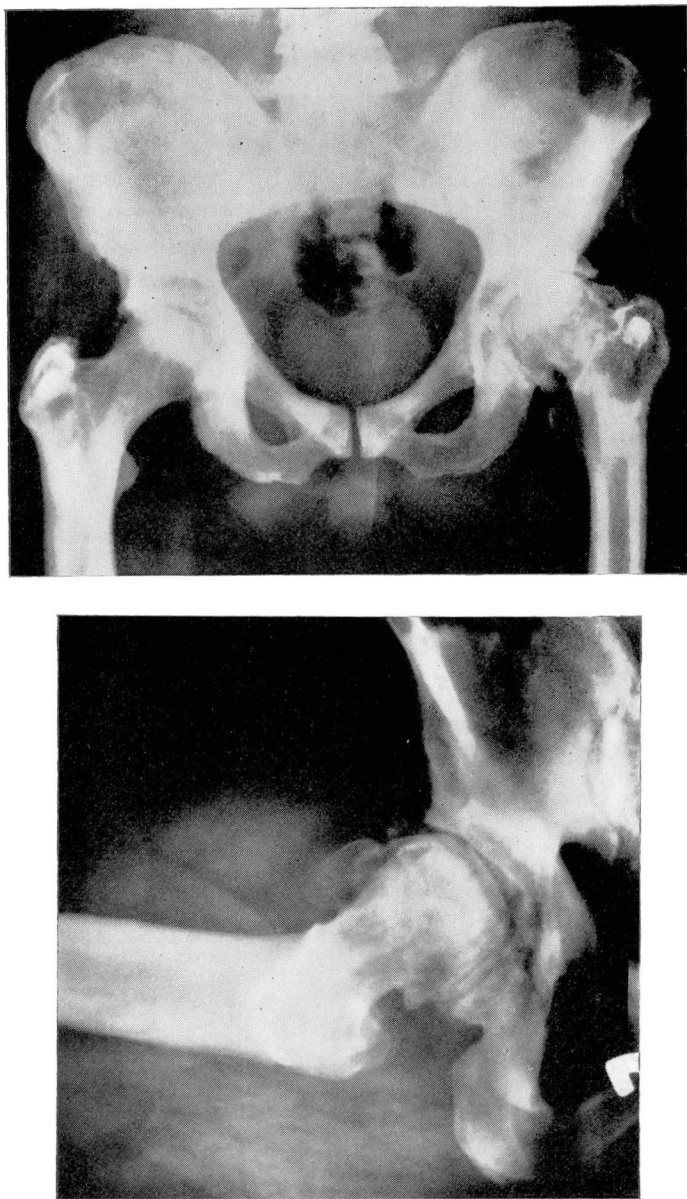

Fig. 1. A, *upper*, Roentgenogram of pelvis showing increased density and concentric sclerotic rings of the ilia and the features of osteoarthritis of the left hip. B, *lower*, Lateral roentgenogram of the left hip more clearly showing the classic changes of osteoarthritis.

appearance is best seen in the carpal bones, and is considered to be pathognomonic of the benign form of the disease.

Histopathologic studies<sup>10-13</sup> have led to a general agreement that the

bone is both increased in amount and abnormal in structure. The essential pathologic alteration is sclerosis of bone, increased trabeculation and irregular bony architecture. There is hypercalcification of cartilage with a persistence of calcified cartilage. The marrow space is decreased or obliterated. Any residual cavity is of a myeloid type with evidence of fibrous rather than lipoid deposition. A severe loss of fibrils of bone is seen, which is especially noticeable in the cortex. Most observers believe that normal numbers of osteoblasts and osteocytes are present.

### Report of a case

A 44-year-old man with a history of benign osteopetrosis was first examined in January 1971 because of pain in the left hip. In 1963, the patient began to experience pain in the left knee after prolonged weight bearing. At that time, results of tests and roentgenograms evaluated by his local physician led to the diagnosis of mild degenerative arthritis of the left hip joint. The patient's symptoms of pain with activity and decreased range of motion of the left hip progressively worsened over a seven-year period. Approximately six weeks before examination, the intensity of the pain prevented the patient from continuing employment, and he was referred to the Cleveland Clinic for evaluation and treatment of the hip disease.

The patient's medical history disclosed that he had sustained a fracture of his left foot in 1946. Roentgenograms of that foot, and later a skeletal survey were consistent with osteopetrosis. This patient had no other fractures, no anemia, no cranial nerve symptoms, and no history of osteomyelitis, of osteopetrosis in the family, or of parental consanguinity. The patient had no children. Orthopaedic examination revealed that the patient had an abductor limp, an antalgic gait, and Trendelenburg's sign was present on the left side. There was marked decrease in the range of motion of his left hip. Laboratory data including a hemogram, calcium, phosphorus, alkaline phosphatase and urine hydroxyproline

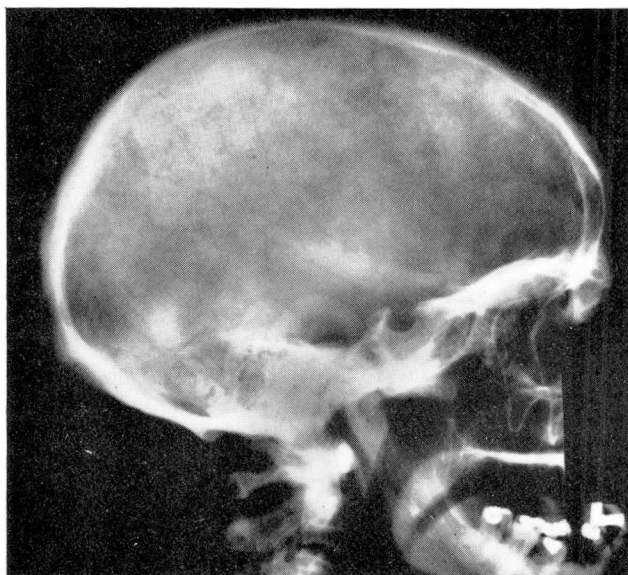
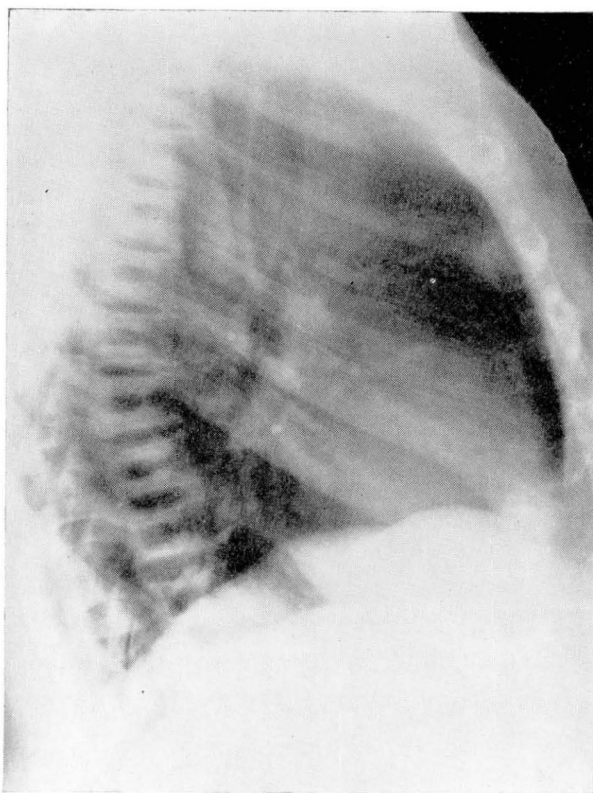


Fig. 2. Roentgenogram showing the change of the base of the skull.





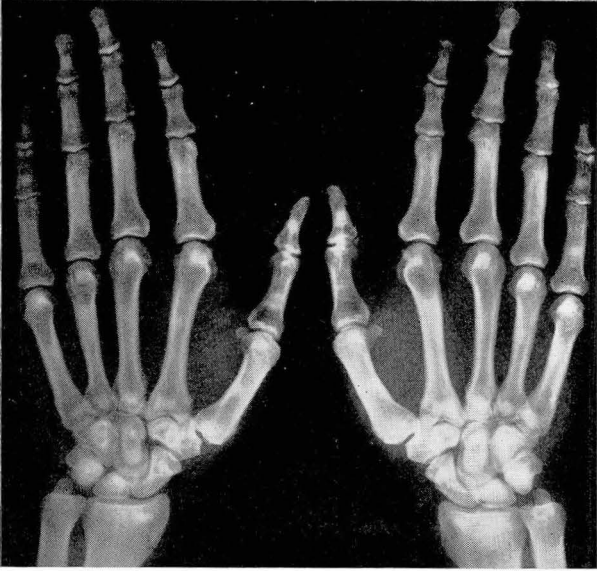**Fig. 3.** Lateral roentgenogram of the thoracic vertebrae showing the typical sawdust-like appearance.

were within normal limits. Acid phosphatase was 58.5 mU per milliliter. Roentgenograms of the pelvis, hips, skull, hands, vertebrae and femur are seen in *Figures 1 through 5*.

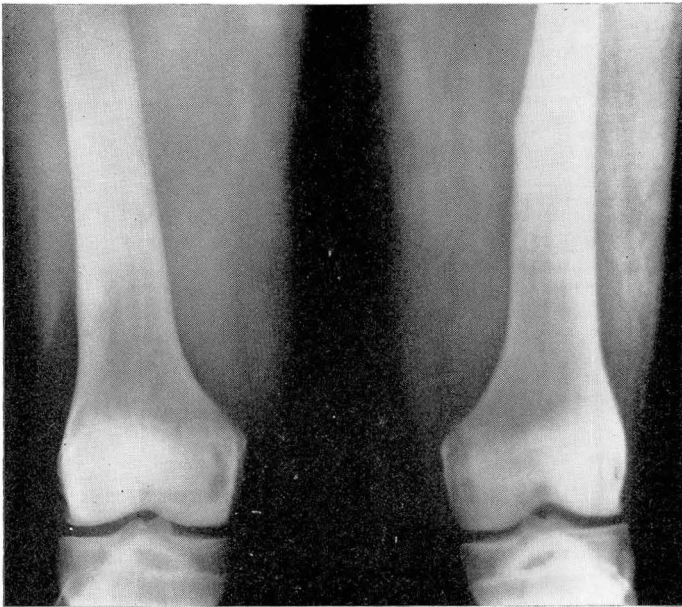On February 21, 1971 the patient underwent operation for a left total hip replacement with a Charnley Muller prosthesis. At the time of operation difficulty arose secondary to the patient's dense but fragile bones. The neck of the femur was the first cut. It was extremely dense, but it was eventually cut with an air-pressure saw. The sclerotic acetabulum was reamed and drilled satisfactorily. The femoral shaft was exceedingly difficult to prepare for acceptance of the femoral component. The narrowness of the medullary cavity made the use of the femoral hand reamer unsatisfactory. The power drill was then used to widen the medullary cavity. This was accomplished slowly until a dense portion of bone was encountered adjacent to the lesser trochanter. At this point drilling was slowed considerably and consideration was then given to altering the femoral component by shortening its shaft. However, the sclerotic area was eventually penetrated and an acceptable tract fashioned. Although the lesser trochanter was cracked during this maneuver, the femoral and acetabular components were seated satisfactorily (*Fig. 6*). The patient had an excellent recovery, and was released from the hospital two weeks after the operation; he was walking with the aid of a cane. Histopathologic section of the portion of the femoral head removed at the time of operation is shown in *Figure 7*.

### Comment

The features of this case include many of the typical radiographic and clinical signs of osteopetrosis, with the added and unusual feature of



**Fig. 4.** Roentgenogram of the hands showing the "bone within a bone" appearance of the carpal bones.



**Fig. 5.** Roentgenogram of the distal femur showing metaphyseal clubbing.



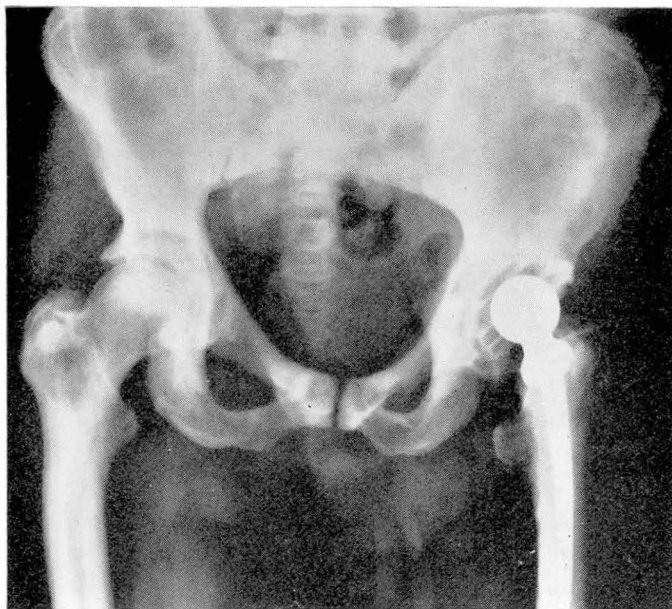

Fig. 6. Roentgenogram showing the Charnley Muller total hip prosthesis in place. Note the fracture of the lesser trochanter.

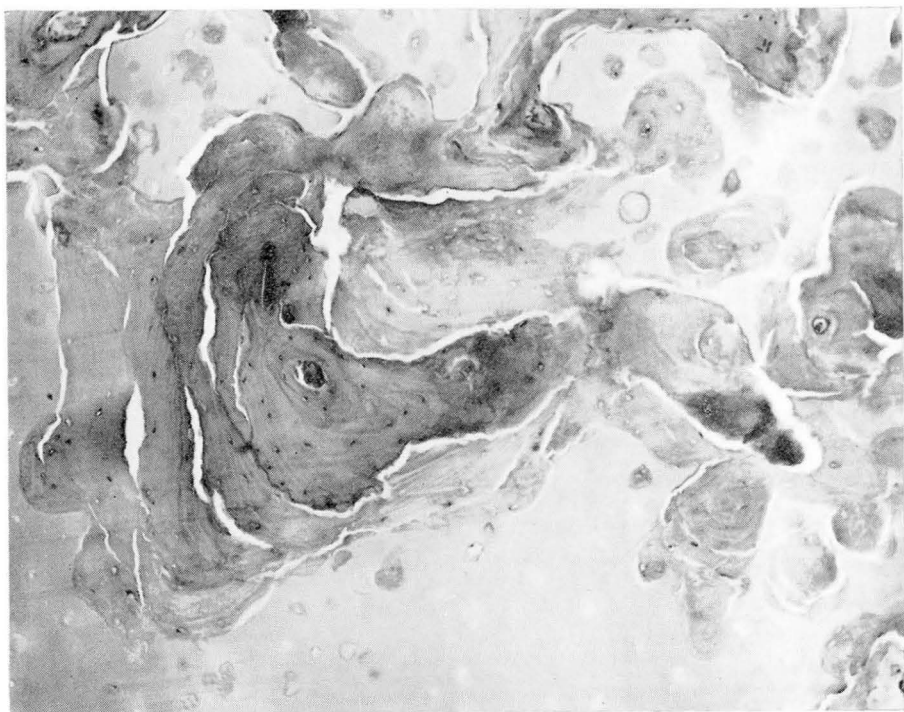


Fig. 7. Histopathologic section showing the increased trabeculation and irregular architecture of bone of the femoral head.

arthritic changes in the hip. The arthritis in this patient represents degenerative or osteoarthritic changes of the hip which are superimposed upon the basic bony abnormality of osteopetrosis. The features, both radiographically and histologically, show that "degenerative" arthritis can produce its classic features despite a basic abnormality of bony development. The metabolic and mechanical factors that produce arthritic changes are not affected by the pathomechanisms that produce osteopetrosis—the bone being able to respond and produce arthritic changes. It is interesting that the classic features of osteoarthritis are present in a disease in which the basic structure of bone development is markedly abnormal, whereas the articular cartilage is not affected by the disease process.

We have found no reports of the treatment of osteoarthritis of the hip in a patient with osteopetrosis and only a few in the orthopaedic treatment for injuries of the bones and joints. Treatment in the past has been empiric and evaluation of the results of treatment is based on little clinical evidence. The total hip replacement arthroplasty for osteoarthritis of the hip provides another form of treatment that is successful and substantiates the difficulty in the use of a surgical implant in this hard and exceedingly brittle bone. Total hip replacement arthroplasty replaces the parts of two individual components that are held rigidly in place by methyl methacrylate. This provides an opportunity to replace the entire joint and obviates use of the arthritic osteopetrotic bone as stock in reconstructive surgery of the hip. The successful total hip replacement in osteopetrosis is another indication for its use in reconstructive surgery of the hip.

## Summary

The case of a 44-year-old man with benign osteopetrosis and degenerative arthritis of the hip is presented. The clinical features of osteopetrosis and the treatment of osteoarthritis of the hip by total hip replacement arthroplasty are discussed, and six months postoperatively the results are satisfactory.

## References

1. Albers-Schönberg, H.: Röntgenbilder einer seltenen Knochenerkrankung. München Med. Wchnschr. **51**: 365, 1904.
2. Laurell, H., and Wallgren, A.: Untersuchungen über einen Fall einer ligenartigen Skeletterkrankung (Osteosclerosis fragilis generalisata). Upsala Lakaref. Forh. **25**: 309–340, 1920.
3. Karshner, R. G.: Osteopetrosis. Am. J. Roentgenol. **16**: 405–419, 1926.
4. Kleinberg, S.: Osteopetrosis. Am. J. Surg. **87**: 5–62, 1954.
5. Breck, L. W.; Cornell, R. C., and Emmett, J. E.: Intramedullary fixation of fractures of the femur in a case of osteopetrosis. J. Bone Joint Surg. **39-A**: 1389–1394, 1957.
6. Jenkins, E. L.; Pfisterer, W. H.; Latleier, K. K., and Martin, M.: A prenatal diagnosis of osteopetrosis. Am. J. Roentgenol. **49**: 455–462, 1943.
7. Keizer, D. P.: Osteopetrosis in a newborn infant. J. Bone Joint Surg. **28**: 332–333, 1955.



8. McPeak, C. N.: Osteopetrosis. Report of 8 cases occurring in 3 generations of a family. *Am. J. Roentgenol.* **36**: 816-829, 1936.
9. Pines, B., and Lederer, M.: Osteopetrosis—Albers Schönberg Disease. *Am. J. Pathol.* **23**: 755-775, 1947.
10. Johnston, C. C.; Lavy, N.; Lord, T.; Vellios, F., Merritt, A. D., and Deiss, W. P.: Osteopetrosis. *Medicine* **47**: 149-167, 1968.
11. Hinkel, C. L., and Beiler, D. D.: Osteopetrosis in adults. *Am. J. Roentgenol. Radium Ther. Nucl. Med.* **74**: 46-64, 1955.
12. Piatt, A. D.; Erhard, G. A., and Araj, J. S.: Benign osteopetrosis. *Am. J. Roentgenol. Radium Ther. Nucl. Med.* **76**: 1119-1131, 1956.
13. Zawisch, C.: Marble bone disease. *Arch. Pathol.* **43**: 55-75, 1947.