

Roentgenographic features of allergic bronchopulmonary aspergillosis

Report of a case

VIRGINIA C. POIRIER, M.D.*

RALPH J. ALFIDI, M.D.

Department of Hospital Radiology

ALLERGIC bronchopulmonary aspergillosis was described by Hinson, Moon, and Plummer¹ in 1952. Since that time most of the case reports and investigations have come from England.²⁻⁶ The disease affects patients who are specifically hypersensitive to aspergillus antigens and is characterized by recurrent episodes of localized pulmonary infiltrations, wheezing, productive cough, and eosinophilia.

The following case report presents some of the pulmonary findings in this disease together with rather unusual roentgenographic features.

Report of a case

A 12-year-old Caucasian boy was examined at the Cleveland Clinic in August 1969 because of abnormal findings on a chest roentgenogram made at another institution. The patient had been under the care of an allergist for the last five years for the treatment of asthma. He had known allergies to dust and ragweed, with worsening of allergic symptoms during the springtime. His asthmatic attacks consisted of wheezing, dyspnea, and a cough, which was occasionally productive of thick sputum. He had not required hospitalization for control of the symptoms. In between the asthmatic attacks, the patient had frequent upper respiratory infection with rhinitis and cough.

One year before examination at the Cleveland Clinic the patient had a chest roentgenogram that showed evidence of an infiltrate in the right upper lobe. The patient was asymptomatic at that time. Skin tests for histoplasmosis and tuberculosis at that time were negative. Therapy consisted of Tedral,[†] potassium iodide, and desensitization.

A second chest roentgenogram obtained two weeks before examination by us showed evidence of multiple infiltrates in both lungs. The patient was again asymptomatic with no recent history of fever, weight loss, dyspnea, cyanosis, or hemoptysis. The asthma had been in good control during the preceding year, and there had been no increased frequency of upper respiratory infections. The patient was referred to the Cleveland Clinic at that time for additional investigation.

On examination the patient was not in respiratory distress and the vital signs were normal. He was in the fifth percentile of height and weight for his age. The only abnormality noted was in the chest, and consisted of scattered rhonchi, most prominent in the upper portion of the right lung field.

The patient's initial chest roentgenogram (*Fig. 1*) revealed multiple oval and tubular densities radiating from the hilar region bilaterally into the upper and midlung fields. There also appeared to be a faint interstitial pattern in the lower portions of both lung fields. Chest laminagrams (*Fig. 2*) showed that these densities communicated directly with the hilum, and there was no evidence of cavitation or calcification.

* Fellow, Department of Hospital Radiology.

† Warner-Chilcott Laboratories.

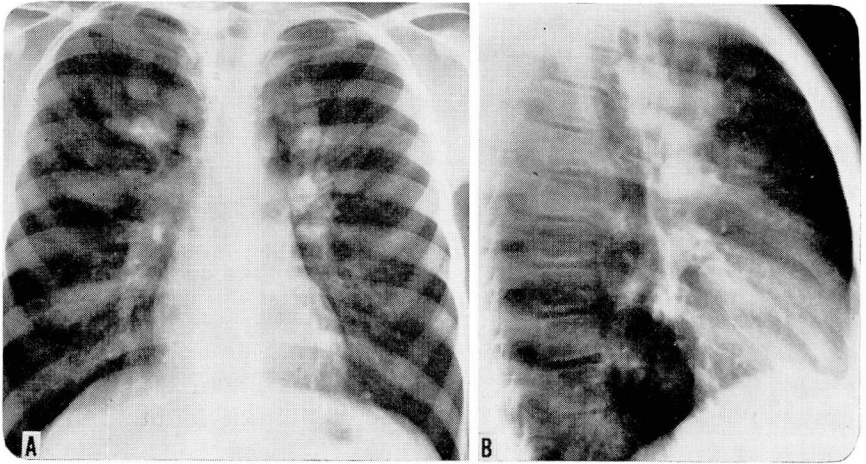


Fig. 1. Initial chest roentgenograms showing multiple oval and tubular densities radiating from the hilar region bilaterally into the upper and midlung fields.

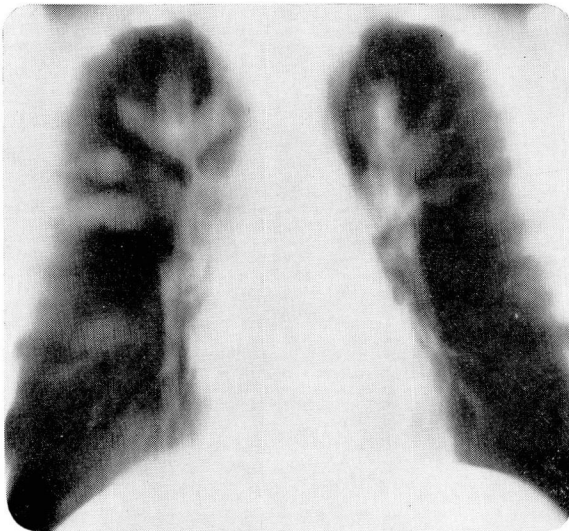


Fig. 2. Chest laminogram shows well-defined densities that communicate directly with the hilar region.

Initial laboratory studies were as follows: hemoglobin 13.9 g per 100 ml, leukocyte count 6,300 per cubic millimeter, and a differential count of 50 percent neutrophils, 10 percent eosinophils, 39 percent lymphocytes, and 1 percent monocytes. Total eosinophil count was 285 per cubic millimeter. Sweat iontophoresis was normal, as were skin tests for tuberculosis, histoplasmosis, and coccidiomycosis. Serum protein content was normal except for a slight elevation of the γ -globulin to 1.8 g per 100 ml (normal, 1.0 g per 100 ml).

The multiple densities in the lung were thought to represent abnormal vascular structures. However, pulmonary angiography revealed that the densities in both upper lung fields were neither pulmonary arteries nor veins and that there was no evidence of

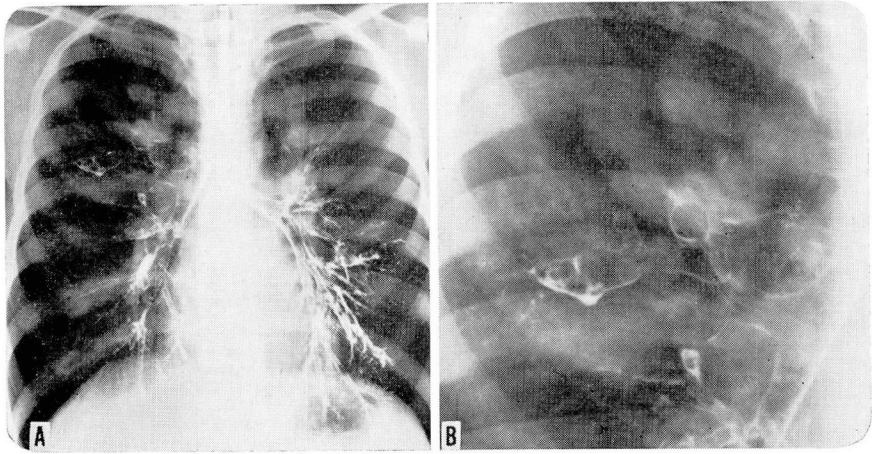


Fig. 3. A, Bronchogram demonstrates bronchiectasis of the posterior segment of the right upper lobe and anterior medial basal segment of the left lower lobe. In addition, there is no filling of a number of apical segments bilaterally which contain mucoid impactions. B, Enlargement of the bronchogram showing the greatly dilated bronchi with mucoid impaction in the right upper lobe.

bronchial artery communication with them. Bronchograms (Fig. 3) revealed a saccular type of bronchiectasis in the posterior segment of the right upper lobe and the anterior medial basal segment of the left lower lobe. In addition there was no filling of a number of apical segments bilaterally, and stenosis of the right middle lobe bronchial orifice. A moderate amount of secretion was seen at the time of bronchoscopy, and the upper lobe bronchi were dilated and plugged with thick bronchial casts.

Subsequently, sputum cultures produced *Aspergillus species*, and a diagnosis of allergic bronchopulmonary aspergillosis with mucoid impaction of the bronchi was established. Pulmonary function tests were normal for total lung capacity, vital capacity, and carbon monoxide diffusion capacity. The forced expiratory volumes were greatly diminished, indicating severe airway obstructive disease. There was some improvement after the use of a bronchodilator.

In an attempt to remove the bronchial plugs, the patient was treated with bronchial lavage: 500 ml of saline in each lung and then 500,000 units of nystatin intrabronchially. The patient was started on a program of pulmonary physiotherapy along with a mucolytic agent and nystatin via ultrasonic nebulization, potassium iodide, and parenterally administered adrenocorticotropin. While in the hospital he coughed up considerable amounts of yellow mucus. The patient was discharged from the hospital several days later. At examination two weeks later the patient still had a productive cough and bilateral wheezing. However, chest roentgenograms taken at that time revealed that there had been some regression of the bronchial densities.

Discussion

In recent years it has become apparent that allergic bronchopulmonary aspergillosis is one of the common causes of pulmonary eosinophilia and that it can cause permanent damage to the lung. The usual presenting symptoms are recurrent episodes of wheezing, and a productive cough sometimes associated with fever or pleuritic pain. During these episodes, radiography often shows evidence of transitory infiltrates in the lungs. During the acute attacks blood eosinophil counts are usually more than

1000 per cubic millimeter. In the sputum there are small plugs of firm consistence, composed mainly of inspissated mucus with many eosinophils and a small amount of aspergillus mycelia. Occasionally expectorated plugs show branching similar to that of bronchial subdivisions.

In the case presented it is thought that the shadows seen in the laminagrams were caused by mucous plugs in proximal branches of the affected bronchi. This was subsequently confirmed by bronchography, which showed a few of the greatly dilated bronchi, but did not demonstrate many of the apical bronchi because of the extreme degree of obstruction from mucoid impactions within them. The patient's eosinophil count was not so high as that reported in most cases of allergic aspergillosis, possibly because the patient was asymptomatic with respect to allergic symptoms at the time of examination.

Untreated, the pulmonary infiltrations seen in the acute episodes of allergic aspergillosis after persisting for a variable time of several weeks to months usually regress, sometimes after expectoration of a plug. Characteristically these episodes tend to recur after various intervals of time. The disease most often affects the upper lobes of the lungs, and the infiltrations are generally segmentally distributed. Bronchograms frequently demonstrate irregular dilatations in the proximal part of a bronchial branch, often with a normal pattern of small bronchial and bronchiolar filling beyond the grossly dilated proximal bronchi. The latter seems to be a special feature of the bronchiectasis associated with allergic aspergillosis. Scadding⁶ showed that most of the other diseases causing bronchiectasis, such as tuberculous or staphylococcal pneumonia, lead to an obliterative bronchiolitis, so that irreversibly dilated bronchi end blindly, losing the continuity with the alveoli normally in communication with them. This difference is not an absolute one, however.

In addition to the radiographic findings just mentioned, Spotnitz and Overholt⁷ described the association of mucoid impaction of the bronchi with allergic aspergillosis, similar to the findings in the case we present. These elliptic, round, or oval opaque impactions are located within greatly dilated bronchi and are most frequently found in segmental or second order bronchi, just distal to a bifurcation.⁸ These densities usually appear to be smoothly margined and are often V-shaped with the apex of the V towards the hilus. Many affected areas may be visible at the same time in different stages of development.

Among the patients with allergic aspergillosis there appear to be two clinical groups. The majority of patients are young and have a long history of asthma, with periodic exacerbation of symptoms, often associated with cough, mucopurulent sputum, and fever. The other group of older patients have no previous history of asthma until the onset of this disease. In this group of late onset, attacks are more frequent, plugs are a more prominent feature, and the radiographic appearance of the

infiltrates is segmental in distribution. Among the long-standing asthmatics, the infiltrates are patchy, mottled, or streaky, and often occur in already emphysematous lungs. In those with long-standing aspergillosis, progressive and permanent lung damage with fibrosis, bronchiectasis, and bullous changes tends to develop.

It has been postulated that the aspergillus mycelia contained in the plugs are the source of the antigens in this disease, and that micro-precipitates of antigen-antibody complexes in the bronchial wall at this site cause an Arthus type of tissue reaction that is responsible for the bronchiectasis.⁹ The consolidation that develops in the segment beyond the plug is probably an eosinophilic pneumonia, capable of complete resolution. It has been demonstrated that these patients show an immediate wheal and flare reaction on the skin in response to aspergillus extracts. In addition, bronchial challenge with these extracts produces an immediate transient increase in airway resistance, and serum precipitins for *Aspergillus* are discoverable in most patients with allergic aspergillosis.

In treatment of the active disease, steroids have been used widely to suppress the allergic reaction, and a variety of antifungal agents have been tried with various degrees of success.

Summary and conclusions

The roentgenogram of the chest of a 12-year-old boy with allergic bronchopulmonary aspergillosis revealed several oval and tubular densities. These densities were shown to be due to impacted secretions in areas of saccular bronchiectasis.

Allergic bronchopulmonary aspergillosis is a disease characterized by the following features: (1) episodic occurrence of wheezing and a productive cough, (2) eosinophilia, (3) demonstration of *Aspergillus species* in the sputum or mucous plugs, and (4) presence of serum precipitins against *Aspergillus*. The radiographic findings are: (1) transient segmental infiltrates in the lungs during the acute episodes; (2) bronchiectasis affecting the second order bronchi of the upper lobes with normal-appearing distal bronchi; (3) occasional mucoid impaction of the bronchi; and (4) apical pulmonary fibrosis in cases of long-standing disease.

References

1. Hinson, K. F. W.; Moon, A. J., and Plummer, N. S.: Broncho-pulmonary aspergillosis; a review and a report of 8 new cases. *Thorax* 7: 217-333, 1952.
2. Campbell, M. J., and Clayton, Y. M.: Bronchopulmonary aspergillosis; a correlation of the clinical and laboratory findings in 272 patients investigated for bronchopulmonary aspergillosis. *Amer. Rev. Resp. Dis.* 89: 186-196, 1964.
3. Goldberg, B.: Radiological appearances in pulmonary aspergillosis. *Clin. Radiol.* 13: 106-114, 1962.
4. Henderson, A. H.: Allergic aspergillosis: review of 32 cases. *Thorax* 23: 501-512, 1968.
5. Sanerkin, N. G.; Seal, R. M. E., and Leopold, J. G.: Plastic bronchitis, mucoid impaction

- of the bronchi and allergic broncho-pulmonary aspergillosis, and their relationship to bronchial asthma. *Ann. Allergy* **24**: 586-594, 1966.
6. Scadding, J. G.: The bronchi in allergic aspergillosis. *Scand. J. Resp. Dis.* **48**: 372-377, 1967.
 7. Spotnitz, M., and Overholt, E. L.: Mucoïd impaction of the bronchi associated with aspergillus; report of a case. *Dis. Chest* **52**: 92-96, 1967.
 8. Carlson, V., and others: Roentgenographic features of mucoïd impaction of the bronchi. *Amer. J. Roentgen.* **96**: 947-952, 1966.
 9. Warren, W. P., and Rose, B.: Hypersensitivity bronchopulmonary aspergillosis. *Dis. Chest* **55**: 415-421, 1969.