

# Posterior cerebral artery embolism: hemianopsia and median longitudinal fasciculus syndrome

## *Report of a case*

THOMAS W. WALLACE, M.D.

ANTONIO CULEBRAS-FERNÁNDEZ, M.D.\*

Department of Neurology

**M**UCH can be learned from acute neurologic signs even though pathologic correlation cannot be obtained. Stroke syndromes when carefully observed from the beginning are often of real diagnostic help. The case we are reporting demonstrates the value of attention to neurologic details in determining the localization and etiology of central nervous system malfunction.

### Report of a case

A 57-year-old man was admitted to the Cleveland Clinic Hospital on January 27, 1970, because of fever. During the previous seven years he had chest pain intermittently. Three years before admission to the hospital he apparently had an acute myocardial infarction in the anterior wall, and one year later a ventricular aneurysm was found. The patient remained reasonably well until the last month when fever developed and persisted despite antibiotic treatment.

At physical examination the patient's temperature was 101 F, pulse rate 95, and the blood pressure 130 mm Hg systolic, and 80 mm Hg diastolic. He appeared lethargic and confused. His skin was dry and the conjunctivae were injected. The cardiac impulse was paradoxical; a grade II holosystolic murmur was heard over the apex, and a pericardial rub was also present. Percussion and auscultation of the lungs disclosed no abnormalities; the abdomen was soft; the liver and spleen were not enlarged. The clinical impression was ventricular aneurysm with pericarditis, and probable subacute bacterial endocarditis.

The hemoglobin was 12.6 g per 100 ml, and the leukocyte count was 17,300 per cubic millimeter, with 86 percent neutrophils. An electrocardiogram demonstrated a healed infarction in the anterolateral wall. The chest roentgenograms revealed an enlarged heart.

On the third hospital day the patient had a sudden loss of consciousness for several minutes, without convulsions. A detailed neurologic examination performed 15 minutes later disclosed a semistuporous patient who was able to follow simple orders. The pupils were equal and reactive to light. The ciliospinal reflexes were present bilaterally. The optic disks appeared normal, and venous pulsations could be seen in both fundi. At times, spontaneous vertical nystagmus was noted. There was no obvious paresis of upward gaze. A striking finding was paralysis of convergence and, in addition, paresis of adduction with horizontal gaze to the right and left. Despite the semistuporous state, it was obvious that the patient neglected the left field of vision and the eyes tended to turn toward the right. Stimulation of the right ear with ice water, with the head raised to a 30° angle from the horizontal, elicited nystagmus of both eyes after 45 sec, with the fast component to the left. Stimulation of the left ear with ice water elicited a tardy and barely perceptible nystagmus.

The face was symmetric and the rest of the cranial nerves were normal. There was no nuchal rigidity; there were hypertonia and an increase of the deep tendon reflexes on the left. Plantar stimulation elicited flexor responses bilaterally. Spontaneous movement and

\*Fellow, Department of Neurology.

withdrawal responses to painful stimuli were normal. Sensation appeared to be preserved. Cheyne-Stokes respiration was noted when the patient was not being stimulated.

A lumbar puncture disclosed an opening pressure of 125 mm of water and a closing pressure of 80 mm after removal of 10 ml of clear and colorless cerebrospinal fluid, which contained no cells. The protein content was 41 mg per 100 ml. The VDRL was negative. The spinal fluid glucose value was 64 mg per 100 ml, with a simultaneous blood glucose value of 82 mg per 100 ml. Roentgenograms of the skull were normal.

The electroencephalogram was abnormal with background rhythms reduced on the right side, and bilateral shifting delta and theta activity in variable distribution. Two per second slow activity at nearly 100  $\mu$ v amplitude appeared maximally through the right posterior quadrant with bursts lasting up to 5 sec. Similar activity showed through the frontal regions, more from the right than the left side, but at times bilaterally.

Within 24 hours after onset of these acute neurologic symptoms, the left hemianopsia had disappeared, but the paralysis of convergence and of adduction on lateral gaze persisted. The fever continued for 11 days, in general ranging from 102 to 104 F, but at times approaching 106 F, and frequently preceded by chills. A cardiac catheterization performed on the eighth hospital day revealed an enormous aneurysm of the apex filled with mural thrombi. On the tenth hospital day a blood culture grew a gram-negative bacillus identified as *Salmonella* Group C<sub>2</sub>. Surgical correction of the aneurysm was performed on the eleventh hospital day. A culture of the thrombi lodged in the aneurysmatic cavity yielded the same organism. Postoperatively the patient received vigorous treatment with additional antibiotics. He became afebrile fairly promptly. By the fortieth hospital day neurologic examination revealed only a mild paresis of convergence.

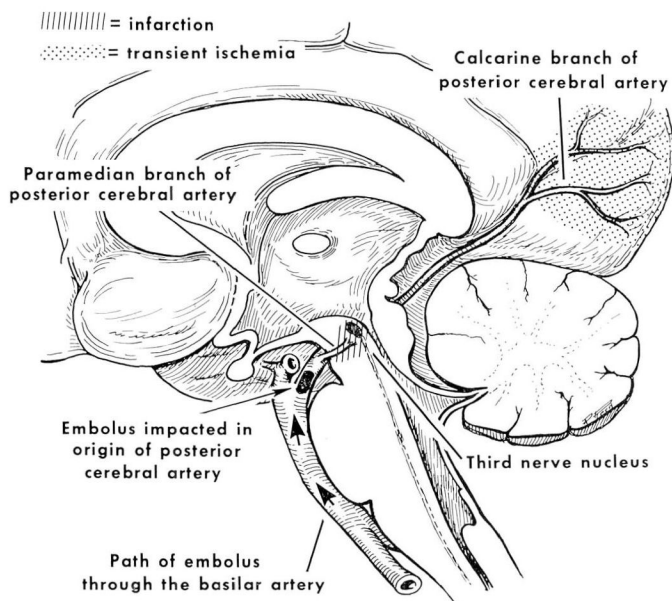
**Epicrisis.** The clinical impression upon admission to the hospital was ventricular aneurysm with a probable subacute bacterial endocarditis. This was confirmed later by the contrast studies and the operative findings and by the culture of *Salmonella* Group C<sub>2</sub> from both blood and thrombi lodged in the aneurysmatic cavity. Special interest in this case was prompted by the neurologic complications that developed. Subacute bacterial endocarditis is a well-known cause of emboli, and the brain is a frequent recipient of these emboli that travel via the carotid or the vertebrobasilar arterial systems.

In the present case the supposition is that an embolus originating in the ventricular aneurysm traveled through the aortic arch, entered one of the vertebral arteries and, on reaching the basilar artery, triggered a transient ischemic episode affecting the brain stem diffusely, thereby accounting for a short period of unconsciousness—perhaps the result of ischemia of the reticular activating system. The embolus continued rostrally and finally came to lodge in the right posterior cerebral artery, affecting the mesencephalic portion of the medial longitudinal fasciculi and the third nerve nuclei, possibly supplied by one of the proximal perforating branches, and in addition the right occipital lobe, which is also irrigated by the posterior cerebral artery. This was expressed clinically by a superior (or anterior) internuclear ophthalmoplegia and a left homonymous hemianopsia. The electroencephalogram confirmed malfunction in the subcortical structures and disclosed reduction of background rhythms on the right side, suggestive of a cerebrocortical disorder as well.

The left hemianopsia disappeared within 24 hours, probably because of prompt restoration of collateral circulation via the circle of Willis. The internuclear ophthalmoplegia slowly improved, and 40 days later had almost totally disappeared, there being only a partial paresis of convergence. Seemingly there had been transient ischemia affecting the occipital lobe, but infarction had been restricted to a small area of the midbrain in the distribution of one or more of the paramedian end artery branches from the origin of the right posterior cerebral artery.

## Discussion

Anatomic clinical correlation is often difficult in regard to brain stem vascular disease, because it is only in fatal cases that pathologic examination is possible and in those patients the infarctions are usually extensive and multiple.<sup>1</sup> Much remains to be learned about functional anatomy of this region, but enough is known to allow meaningful use of a few distinctive neurologic signs.



**Fig. 1.** Sketch of brain and brain stem sectioned in the median plane to show relationship of embolus lodged in posterior cerebral artery to the areas of ischemia causing the patient's symptoms. Crosshatched lines mark infarcted mesencephalon at the juncture of the third cranial nerve nucleus and MLF. This area receives its arterial blood supply from a paramedian branch of the posterior cerebral artery. Stippling marks the occipital lobe region that was affected so severely by ischemia as to produce a transient homonymous hemianopsia. This occipital lobe receives its blood supply mainly from terminal branches of that same posterior cerebral artery.

Internuclear ophthalmoplegia is often referred to as the median longitudinal fasciculus (MLF) syndrome. Malfunction of this pathway is a theoretic controversial matter in many respects,<sup>2</sup> but there is general agreement that the most definitive feature is adductor paresis on lateral gaze.<sup>2-5</sup> In addition to proprioceptive and vestibular fibers the MLF on each side carries fibers ascending from the parabducens nuclear regions in the pons crossing over to the cells of origin of the oculomotor fibers supplying the opposite medial rectus nuclei. It is in the caudal and medial junction of the oculomotor nuclei that ocular convergence is likely subserved. The MLF fibers run just anterior to the aqueduct of Sylvius in the mesencephalon and there, medial to these fasciculi, are the third nerve nuclei (*Fig. 1*). Thus, internuclear ophthalmoplegia with convergence paralysis must originate in the mesencephalon where both the oculomotor nuclei and MLF can be involved in a single lesion. This paramedian area is supplied by long narrow arterial branches of the posterior cerebral arteries just after they bifurcate from the rostral end of the basilar artery.<sup>6-8</sup>

An embolus lodged at the origin of the right posterior cerebral artery could

easily cover the orifice of origin of one or more of these end arteries, and this seems to have happened to cause infarction in the paramedian mesencephalic area in the patient whose case we report.

The posterior cerebral artery, after giving off these perforating branches, circumscribes the cerebral peduncle to supply branches to the temporal lobe and to the occipital lobe with its visual receptive area. Infarction or transient ischemia in this cortical region causes homonymous hemianopsia. Its brief duration is likely the result of only impaired blood flow with no infarction, compensation being provided by collateral circulation from the posterior communicating artery.

The initial loss of consciousness also favors brain stem ischemia with depression of the reticular activating centers. The electroencephalogram provided additional evidence for ischemia of the brain stem and of the occipital lobe.

The abrupt onset of these neurologic symptoms and the proved source for embolization is strong evidence for embolization rather than atherosclerotic thrombosis as cause for occlusion of that posterior cerebral artery—a favored site for temporary impaction from such clot fragments.

### Summary

A patient with fever, then sudden loss of consciousness, was found to have an anterior internuclear ophthalmoplegia and a transient homonymous hemianopsia shortly after regaining consciousness. Neurologic signs indicated occlusion at the bifurcation of the posterior cerebral arteries from the rostral end of the basilar artery. An infected clot in the left ventricle was the intracardiac source of embolization.

### References

1. Loeb, C., and Meyer, J. S.: Strokes Due to Vertebro-basilar Disease; Infarction, Vascular Insufficiency and Hemorrhage of the Brain Stem and Cerebellum. Springfield, Ill.: Charles C Thomas, 1965, 307 p.; p. 29–31, 92–94.
2. Christoff, N., and others: Problems in anatomic analysis of lesions of the median longitudinal fasciculus. *A.M.A. Arch. Neurol.* 2: 293–304, 1960.
3. Cogan, D. G.: *Neurology of the Ocular Muscles*, 2d ed. Springfield, Ill.: Charles C Thomas, 1956, 296 p.; p. 84–91.
4. Smith, J. L., and Cogan, D. G.: Internuclear ophthalmoplegia; a review of fifty-eight cases. *A.M.A. Arch. Ophthalmol.* 61: 687–694, 1959.
5. Van Allen, M. W.: Lateral gaze and convergence in internuclear ophthalmoplegia: a note on examination. *Neurology* 16: 362–363, 1966.
6. Haymaker, W.: *Bing's Local Diagnosis in Neurological Diseases*. St. Louis: The C. V. Mosby Company, 1969, 600 p.; p. 305.
7. Hiller, F.: The vascular syndromes of the basilar and vertebral arteries and their branches. *J. Nerv. Ment. Dis.* 116: 988–1016, 1952.
8. Hassler, O.: Arterial pattern of human brainstem; normal appearance and deformation in expanding supratentorial conditions. *Neurology* 17: 368–375, 423, 1967.