

Idiopathic hemochromatosis presenting as malabsorption syndrome

Report of a case

JOHN R. KRAMER, JR., M.D.*

RICHARD G. FARMER, M.D.

Department of Gastroenterology

HEMOCHROMATOSIS is a disease of altered iron metabolism, associated with parenchymal cell damage, particularly in the liver, pancreas, and myocardium. The triad of hepatic disease, hyperpigmentation of the skin, and diabetes mellitus is well known. Additional clinical findings such as testicular atrophy, congestive heart failure, portal hypertension, and hepatoma have also been reported.¹⁻³

The fundamental pathologic defect in idiopathic hemochromatosis is not known. There has been considerable controversy in the last decade⁴⁻⁹ as to whether or not the syndrome represents a clinical entity, or a variant of portal cirrhosis of the liver as suggested by MacDonald and associates.^{4, 6-8} It has been noted that an increase in ingestion of exogenous iron, in excess of iron loss, may lead to increased deposition of iron in tissues, with characteristic clinical features.¹⁰ In addition, there is a body of evidence indicating that hemochromatosis may be the result of a genetic defect—an autosomal dominant with incomplete penetrance. Studies of families have tended to support this view.^{9, 11}

A portion of the renewed interest in the pathogenesis and clinical features of hemochromatosis has been the result of improved therapeutic measures, largely due to the efficacy of repeated venesections.^{3, 12} Therefore, although rare, the syndrome of hemochromatosis has received somewhat disproportionate interest by clinical investigators.

Despite frequent involvement of the pancreas, pancreatic insufficiency rarely occurs with hemochromatosis. Postmortem examinations have revealed the parenchymal cell deposition of iron in the pancreas to be from 50 to 100 times normal. Fibrosis, acinar cell degeneration, and islet scarring also occur.^{2, 3} It has been suggested that there may be acinar dysfunction associated with these changes, but studies of pancreatic secretions in hemochromatosis give conflicting results.^{1, 2}

A review of the literature has yielded no clinical reports in which pancreatic insufficiency and malabsorption play a significant role in the

* *Intern, Cleveland Clinic Hospital.*

syndrome of hemochromatosis. Furthermore, no reports were found which indicated that hemochromatosis should be considered in the differential diagnosis of pancreatic insufficiency or of malabsorption. Recent reviews of the subject of malabsorption, including the spectrum of diseases that may cause steatorrhea, have mentioned hemochromatosis either only briefly or not at all.¹³⁻¹⁶ This association is theoretically possible with hemochromatosis (because of the increased iron in tissues and parenchymal cell damage in the liver and pancreas), and it did in fact occur in the case we report.

Report of a case

A 54-year-old Caucasian man was first seen at the Cleveland Clinic in November 1969 because of diarrhea and weight loss. He said he had been in good health until about one year before being seen by us when, at the time of routine physical examination by his local physician, a two-hour postprandial blood sugar determination was found to be elevated (142 mg per 100 ml of blood). He was given phenformin hydrochloride, one capsule daily.

In July 1969, he began to have five or six loose, light-brown bowel movements per 24 hours. This continued for approximately one month, when the bowel movements became yellow, greasy, and foul smelling. A provisional diagnosis of malabsorption syndrome was made by his family physician and the patient was started on a gluten-free diet, without subsequent improvement. He lost approximately 25 lb. in two months. There was no rectal bleeding, melena, abdominal pain, or fever. His symptoms remained about the same for the next two months. There was no history of abdominal pain or other findings suggestive of pancreatitis in the past. He had consumed one or two alcoholic beverages each day. He had had no blood transfusions nor had he ingested iron. He had no dermatitis, no increased pigmentation of the skin, no bleeding tendencies, no night blindness, no numbness, no paresthesias, or arthralgias. There was no history of abdominal surgery. The only medications he had taken in the preceding six months were a short course of pancreatin and phenformin hydrochloride.

On initial physical examination by us he appeared chronically ill. There were no abnormalities of the skin and specifically there was no hyperpigmentation, dermatitis, or ecchymosis. There was no glossitis. The heart was not enlarged; there was no gallop rhythm; and there was no evidence of congestive heart failure. The liver was enlarged to 10 cm below the right costal margin, without tenderness or nodularity. The spleen was not enlarged; there was no testicular atrophy. Results of neurologic examination, proctosigmoidoscopic examination, and the remainder of the physical examination were normal.

Routine laboratory studies were normal. Blood hemoglobin was 14.4 g per 100 ml. The morphology of the peripheral blood was normal. Blood urea nitrogen, creatinine, and electrolyte values were normal, as were serum amylase, lipase, and calcium values. Prothrombin time was normal. Roentgenograms of the chest and abdomen and an electrocardiogram were normal.

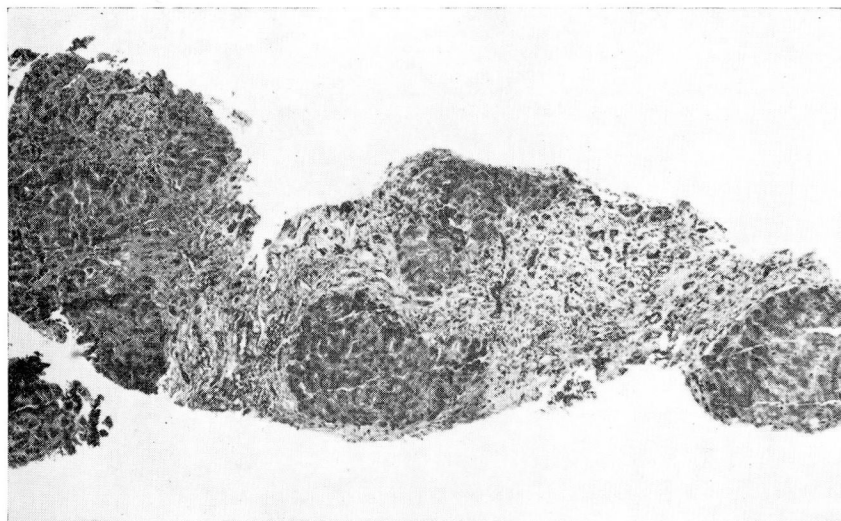
Tests of hepatic function indicated normal bilirubin concentration of 0.8 mg per 100 ml. Sulfobromophthalein retention was 0 percent in 45 minutes. Serum glutamic oxalacetic transaminase content was 100 units (normal value less than 40 units). The serum protein electrophoretic pattern and lipid profile were normal. Plasma carotene was 10 μ g per 100 ml (normal value more than 50 μ g). D-xylose tolerance test was normal (6.2 g excreted in 5 hours). An oral glucose tolerance test was abnormal (1-hour value, 206 mg per 100 ml; and 2-hour value, 250 mg per 100 ml). Total serum iron was 183 μ g per 100 ml (range of normal values, 50 to 150 μ g).

A roentgenogram of the esophagus, stomach, duodenum, and small intestine after ingestion of barium demonstrated nonspecific jejunal dilatation with a minor degree of segmentation. There was no evidence of regional enteritis. A roentgenogram of the colon after barium enema was normal.

The collection of a 72-hour stool specimen demonstrated significant steatorrhea: 106.2 g of fat were excreted in 72 hours (35.4 g per 24 hours) (normal value less than 7.5 g per 24

Table 1.—Pancreatic secretion studies of patient with idiopathic hemochromatosis

Factor	Basal value	Period of test, minutes			
		10	20	40	60
Volume, ml	34	41	74	87	33
Carbon dioxide, content, meq per liter	9.7	44.2	45.2	38.4	28.1

**Fig. 1.** Photomicrograph showing nodules of liver tissue margined by extensive bands of dense fibrous tissue, and bile ducts typical of pigment cirrhosis. Hematoxylin-eosin-methylene blue stain; magnification $\times 50$.

hours). A secretin study was diagnostic for pancreatic insufficiency (*Table 1*), with moderate decrease in volume and significant decrease in bicarbonate excretion. The highest value obtained was 45.2 meq per liter (normal value, more than 90 meq per liter). Percutaneous biopsy of the liver was characteristic for hemochromatosis (*Fig. 1 and 2*). Peroral small-bowel biopsy specimen (*Fig. 3*) was normal, and did not react with periodic acid—Schiff stain.

The patient's hospital stay was uneventful, except for moderate continuation of diarrhea. He was given a general diet and allowed activity as tolerated, pancreatin (three tablets, four times daily), and multiple vitamins. A course of phlebotomies was instituted. He was seen again in February 1970, by which time he had had a decrease in the number of bowel movements and an increase in strength and well-being. In April 1970 he was asymptomatic, and continued the course of pancreatin and phlebotomies.

Comment and summary

Steatorrhea secondary to pancreatic insufficiency has not been documented in association with idiopathic hemochromatosis. There appears to be no evidence that the steatorrhea in this case was directly associated with diabetes mellitus. Studies by Whalen, Soergel, and Geenen¹⁷ of five patients with steatorrhea and diabetes mellitus indicated that plasma

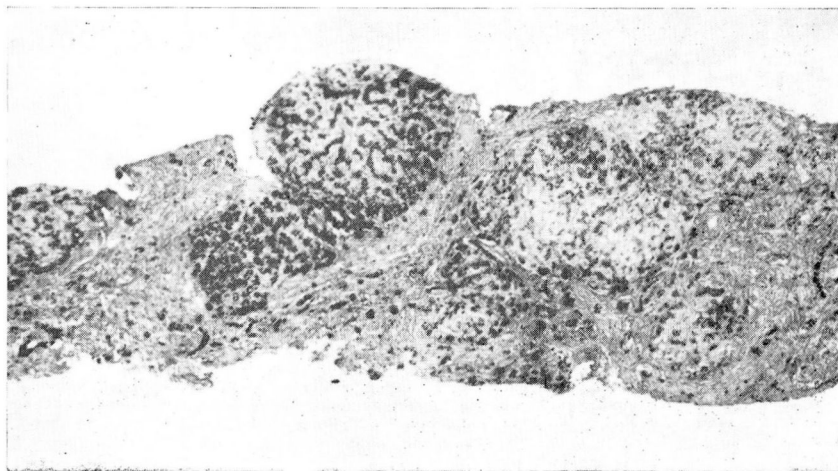


Fig. 2. Photomicrograph of section stained for iron showing abundant deposits within hepatocytes and bile ducts. Magnification $\times 50$.

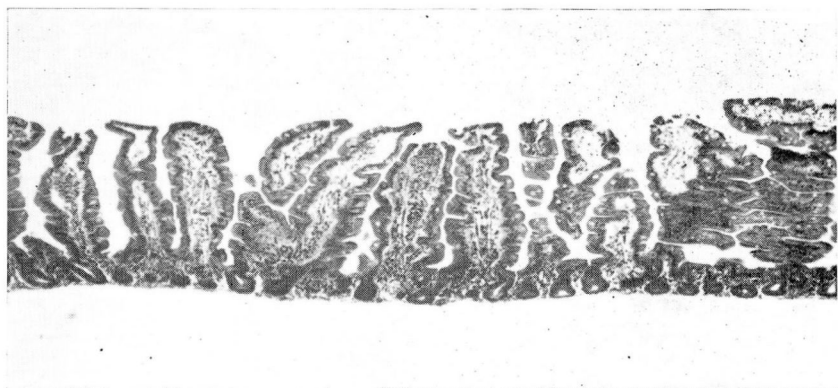

Fig. 3. Photomicrograph of small intestinal biopsy specimen demonstrating essentially normal mucosa. Hematoxylin-eosin-methylene blue stain; magnification $\times 50$.

carotene levels and tests of pancreatic exocrine function were normal. Furthermore, among patients with diabetes mellitus, diarrhea or steatorrhea, or both conditions, seem to be related to the severity and the duration of the diabetes mellitus.

Malabsorption with steatorrhea in a patient with hemochromatosis apparently is due to pancreatic insufficiency, with resulting deficient hydrolysis of long-chain triglycerides. It is tempting to hypothesize that the deposition of iron in the pancreas leads to cellular destruction, causing pancreatic insufficiency. However, the exact relationship of the deposition of iron in the pancreas and the development of diabetes mellitus or pancreatic insufficiency cannot be determined with accuracy.¹⁸ Similarly, there

is a peculiar relationship of pancreatic disease in general to iron absorption. It has been shown that in diseases causing pancreatic damage there is increased intestinal absorption of orally ingested iron, as there is in hemochromatosis.^{19, 20}

Idiopathic hemochromatosis remains a perplexing, unusual, and fascinating clinical syndrome. Despite a high incidence of pancreatic involvement in hemochromatosis, pancreatic insufficiency with steatorrhea is a rare occurrence. This perhaps is the first case of pancreatic insufficiency with steatorrhea presenting as malabsorption syndrome that is documented in association with hemochromatosis. Whether there is or is not a specific relationship between iron deposition in the pancreas and pancreatic insufficiency is at this time in the realm of speculation.

References

1. Sheldon, J. H.: Haemochromatosis. London: Oxford University Press, 1935; p. 40-45.
2. Bothwell, T. H., and Finch, C. A.: Iron Metabolism. Boston: Little, Brown and Company, 1962; p. 364-434.
3. Dubin, I. N.: Idiopathic hemochromatosis and transfusion siderosis; a review. *Amer. J. Clin. Path.* **25**: 514-542, 1955.
4. MacDonald, R. A.: Idiopathic hemochromatosis; a variant of portal cirrhosis and idiopathic hemosiderosis. *Arch. Intern. Med.* **107**: 606-616, 1961.
5. Finch, C. A., and Bothwell, T. H.: Editorial. The syndrome of hemochromatosis. *Arch. Intern. Med.* **107**: 807-810, 1961.
6. MacDonald, R. A.; Becker, B. J. P., and Pechet, G. S.: Iron and liver disease in South Africa. *Arch. Intern. Med.* **111**: 315-322, 1963.
7. MacDonald, R. A.: Idiopathic hemochromatosis; genetic or acquired? *Arch. Intern. Med.* **112**: 184-190, 1963.
8. MacDonald, R. A., and Pechet, G. S.: Tissue iron and hemochromatosis; comparative geographic studies in Ireland, Israel, Japan, South Africa, and the United States. *Arch. Intern. Med.* **116**: 381-391, 1965.
9. Williams, R., and Pitcher, C. S.: Iron metabolism and the liver with particular reference to the pathogenesis of haemochromatosis. *Postgrad. Med. J.* **39**: 193-204, 1963.
10. Heilmeyer, L.: Pathogenesis of hemochromatosis. *Medicine* **46**: 209-215, 1967.
11. Balcerzak, S. P., and others: Idiopathic hemochromatosis; a study of three families. *Amer. J. Med.* **40**: 857-873, 1966.
12. Crosby, W. H.: Treatment of haemochromatosis by energetic phlebotomy; one patient's response to the letting of 55 litres of blood in 11 months. *Brit. J. Haemat.* **4**: 82-88, 1958.
13. Badenoch, J.: Steatorrhoea in the adult. *Brit. Med. J.* **2**: 963-974, 1960.
14. Wollacger, E. E., and Scudamore, H. H.: Spectrum of diseases causing steatorrhea. *Arch. Intern. Med.* **113**: 819-825, 1964.
15. Kirsner, J. B.: Clinical observations on malabsorption. *Med. Clin. N. Amer.* **53**: 1169-1194, 1969.
16. Jeffries, G. H.; Weser, E., and Sleisenger, M. H.: Malabsorption. *Gastroenterology* **56**: 777-797, 1969.

17. Whalen, G. E.; Soergel, K. H., and Geenen, J. E.: Diabetic diarrhea; a clinical and pathophysiological study. *Gastroenterology* **56**: 1021–1032, 1969.
18. Balcerzak, S. P.; Mintz, D. H., and Westerman, M. P.: Diabetes mellitus and idiopathic hemochromatosis. *Amer. J. Med. Sci.* **255**: 53–62, 1968.
19. Kahn, I. J.: The pancreas and iron absorption. *Gastroenterology* **51**: 736–738, 1966.
20. Deller, D. J.: Iron⁵⁹ absorption measurements by whole-body counting: studies in alcoholic cirrhosis, hemochromatosis, and pancreatitis. *Amer. J. Dig. Dis.* **10**: 249–258, 1965.