

# Pathogenesis, diagnosis, and treatment of the tarsal-tunnel syndrome

THOMAS E. GRETTHER, M.D.

Department of Neurology

ALAN H. WILDE, M.D.

Department of Orthopaedic Surgery

**I**N recent years many peripheral nerve compression syndromes have been recognized. The carpal-tunnel syndrome, or compression of the median nerve at the wrist beneath the transverse carpal ligament, is the commonest nerve entrapment syndrome. Less familiar but no less important is the tarsal-tunnel syndrome. Since the first case reports of the tarsal-tunnel syndrome by Keck<sup>1</sup> and by Lam,<sup>2</sup> in 1962, this syndrome is being diagnosed with increasing frequency. Within the last two years 17 patients with the tarsal-tunnel syndrome have been treated at the Cleveland Clinic. Our report presents a review of the pathogenesis, diagnosis, and treatment of the tarsal-tunnel syndrome.

## Anatomy

The tarsal tunnel is a canal formed on the medial side of the foot and ankle by the medial malleolus of the tibia and the flexor retinaculum. The flexor retinaculum spans the medial malleolus of the tibia and the medial tubercle of the os calcis (*Fig. 1*). The space beneath the ligament is divided by septae into four compartments. Each compartment contains one of the four structures of the tarsal tunnel. These structures are the posterior tibial tendon, flexor digitorum longus tendon, posterior tibial nerve, artery and veins, and the flexor hallucis longus tendon. Each tendon is invested with a separate synovial sheath. The posterior tibial nerve supplies the skin of the sole of the foot and also the dorsum of the toes (*Fig. 2A and B*). The posterior tibial nerve usually divides into the medial plantar and lateral plantar nerves and the medial calcaneal branches as it passes beneath the flexor retinaculum. The medial and lateral plantar nerves usually supply the intrinsic muscles of the sole of the foot, which are chiefly responsible for flexion of the toes. These nerves supply sensation to the skin of the sole of the foot and to the distal portion of the toes. The medial calcaneal nerve supplies the sensation for the plantar surface of the heel.

## Pathogenesis

The posterior tibial nerve can be compressed by various local conditions. A lipoma, exostosis, a cyst or a tumor of the tendon sheath can develop

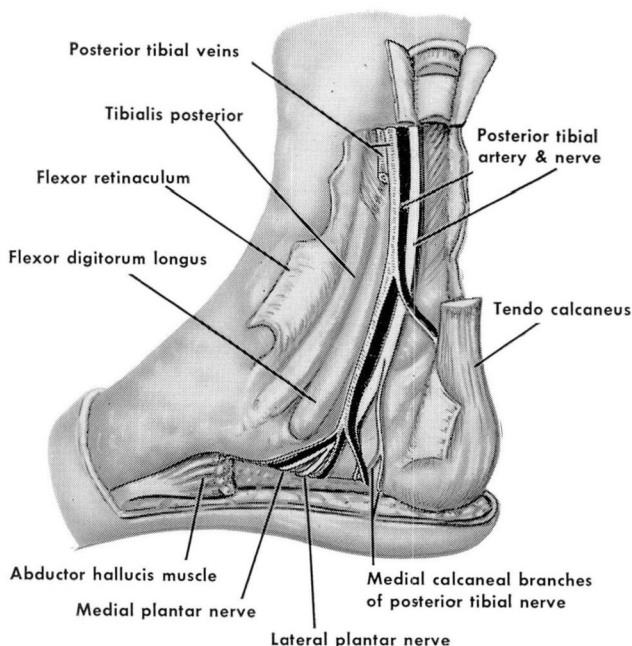
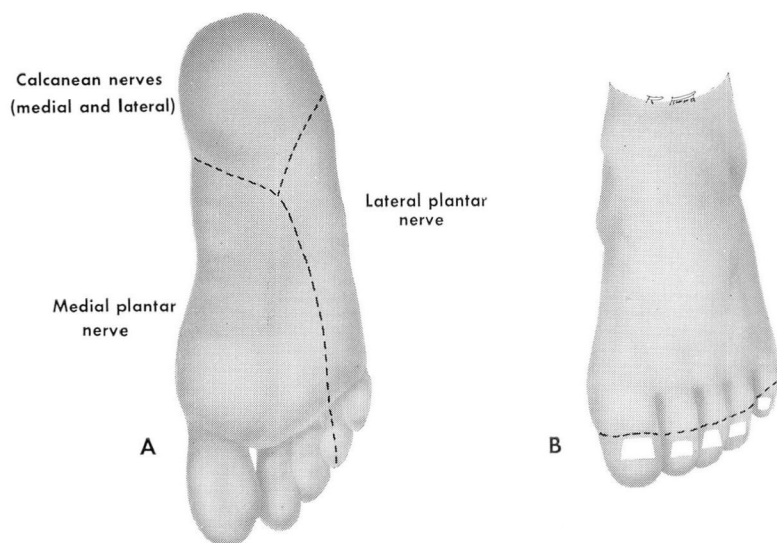


Fig. 1. The anatomy of the tarsal tunnel. The flexor retinaculum spans the medial malleolus of the tibia and the medial tubercle of the os calcis. Note that there are two posterior tibial veins. Each of the tendons resides in a separate compartment and is invested by synovium.

in this location and can compress the posterior tibial nerve. An accessory or hypertrophied abductor hallucis muscle may be present. This can be recognized by the presence of a soft tissue mass on the medial border of the foot. Contraction of this abnormal muscle can compress the posterior tibial nerve.<sup>3</sup> Synovitis of the posterior tibial, flexor digitorum longus, or flexor hallucis longus tendons has also been found in patients with the tarsal-tunnel syndrome. Tenosynovitis occurs in patients with rheumatoid arthritis, and we believe that it is the usual cause of the tarsal-tunnel-syndrome in patients with this disease.<sup>4</sup> Tenosynovitis may also develop in patients without rheumatoid arthritis, in which case it may be due to the patient's occupation or his use of the foot.

Engorgement of the posterior tibial veins has been seen in a number of patients at operation.<sup>1-5</sup> This may be the result of incompetence of the venous valves or of a proximal venous occlusion in the leg. Some of the pain in the leg of patients with chronic venous stasis from chronic thrombophlebitis may be due to pressure on the posterior tibial nerve.<sup>6</sup>

In all the local conditions listed above there seems to be one factor in common: localized pressure on the posterior tibial nerve from the flexor retinaculum. We believe that this results in a localized ischemia of the



**Fig. 2.** Sensory branches of the posterior tibial nerve. A, Plantar surface—the medial plantar nerve supplies the sensation for the medial two thirds of the sole of the foot and the medial three and one-half toes. The lateral plantar nerve supplies the sensation for the lateral third of the sole of the foot and the small toe and lateral half of the fourth toe. The calcaneal nerves supply the sensation of the skin of the plantar surface of the heel. The medial calcaneal nerve, a branch of the posterior tibial nerve, supplies the major parts of the skin of the heel. The lateral calcaneal nerve, a branch of the sural nerve, supplies the sensation on the lateral aspect of the plantar surface of the heel. B, Dorsal surface—the extremities of the toes and their nails are supplied by the medial and lateral plantar nerves.

posterior tibial nerve. Experimentally and clinically there is good evidence that arterial insufficiency is responsible for the sensory abnormalities in the carpal-tunnel syndrome.<sup>7, 8</sup> Anatomically the posterior tibial nerve and the median nerve are similar. They each possess a rich vascular supply. This implies that these nerves require more than an average amount of blood for their metabolism. A diminution in the blood supply interferes with the nutrition of these nerves and may be responsible for the production of symptoms. Additional evidence that ischemia is responsible for the production of the tarsal-tunnel syndrome is provided by the tourniquet test. Inflation of a tourniquet on the calf of the affected leg to a level sufficient to produce venous occlusion is likely to reproduce the clinical syndrome. Furthermore, tourniquet paralysis has been shown to be due to localized ischemia of the affected nerve.<sup>9</sup> We believe that the pathogenesis of the tarsal-tunnel syndrome, similar to that of the carpal-tunnel syndrome, is localized ischemia of the posterior tibial nerve at the ankle.

### Symptoms and signs

The major symptom of patients in our series with the tarsal-tunnel syndrome is a painful sensation of the *sole* of the foot. The symptoms

may be bilateral, and severity is determined by the site and duration of the compression. The pain is described as burning in character. It commonly involves the anterior portion of the sole of the foot but, occasionally, when the calcaneal branches are affected, the pain may be in the heel. The pain may develop and increase as the day progresses with use of the extremity. There may be pain that wakes the patient from a sound sleep, and relief from the pain is obtained by walking, or by rubbing or moving the foot. The pain may be severe and ascend the posterior aspect of the leg, and rarely into the thigh and buttock. It generally is not aggravated by coughing or sneezing. On other occasions the symptom is numbness or lack of sensation on the sole of the foot. Tenderness is sometimes noted by the patient beneath the medial malleolus. The patients occasionally have a long history of flat feet, painful arches, and cramps in the arches or the toes. Tight shoes tend to aggravate the pain. The symptoms may be intermittent at first and then become constant.

The physical signs are determined by the site and duration of the compression. The presence and distribution of sensory alteration of the foot is important to establish. The most common sensory involvement is the area innervated by the medial plantar nerve. This encompasses the anterior two thirds of the sole of the foot including the tips of the first three and one-half toes. The sensory loss may affect the entire posterior tibial innervation or one or more of its branches (*Fig. 2A and B*). Occasionally a discretely tender area is palpable at the margin of the medial malleolus. The presence of Tinel's sign, elicited by pressure on the posterior tibial nerve in the tarsal tunnel, with pain radiating into the sole of the foot is diagnostically helpful. Forcing the foot into eversion, stretching the nerve in the tarsal tunnel may also reproduce the symptoms. These findings are supported by those of other clinicians.<sup>1, 3, 6</sup>

Skin changes resembling reflex dystrophy have been reported<sup>10</sup> but we have not seen them in patients in our series. Mild weakness of the intrinsic muscles of the foot is difficult to detect. Some atrophy may be noted in the abductor hallucis muscle and can be recognized in later stages of compression. Hypertrophy of the abductor hallucis or an accessory muscle has been noted. The foot may have a pes planus appearance. Some patients have reported a recent gain in weight before the onset of symptoms.

## Diagnosis

Electromyography has been used in all cases to test the clinical diagnosis of tarsal-tunnel syndrome. The technic of determining nerve-conduction velocities using cutaneous electrodes has been described previously.<sup>11, 12</sup> Silver-disk surface electrodes are placed over the bellies of the abductor hallucis and the abductor quinti muscles. The posterior tibial nerve is stimulated through the skin just proximal to the flexor retinaculum. The interval between stimulation and the muscle response, expressed in milli-

seconds, is termed latency. According to results in our series, a latency in excess of 6.1 milliseconds for the medial plantar nerve, and 6.7 milliseconds for the lateral plantar nerve, is indicative of a compression neuropathy. This standard is supported by other investigators.<sup>10-12</sup> The use of electromyography is diagnostically helpful, but needle electrodes placed in the abductor hallucis and abductor quinti are extremely painful. The early appearance of denervation potentials, complex polyphasic potentials, and changes in the interference pattern representing a neuropathic pattern, support the diagnosis of posterior tibial nerve compression syndrome.

### Complicating diseases

The association of the tarsal-tunnel syndrome with other diseases is not yet fully established. A search should be made for the presence of other causes of peripheral neuropathies. In some patients we have noted vascular disease, venous stasis, occlusive peripheral vascular disease, diabetes mellitus, and rheumatoid arthritis. As with the carpal-tunnel syndrome, myxedema, pregnancy, amyloid deposition, and change in weight may be complications. This complex problem is being studied. The clinician should be aware of the presence of local compressive lesions and tenosynovitis. Differential diagnosis between radiculitis and the tarsal-tunnel syndrome is usually not difficult to establish.

Cases have been reported<sup>3</sup> in which there were peripheral neuropathy secondary to diabetes or other causes and the concurrent presence of tarsal-tunnel syndrome. Secondary symptoms have improved with treatment of the tarsal-tunnel compression.

### Treatment

After diagnosis of the tarsal-tunnel syndrome has been established by clinical and electroneuromyographic methods, the initial treatment should be conservative. Two or at the most three injections of 10 mg each of triamcinolone acetonide are given beneath the flexor retinaculum around the posterior tibial nerve. The nerve can be located by observing or palpating the pulsation of the posterior tibial artery just posterior to the medial malleolus of the tibia at the ankle joint. This drug may give transient relief, but if the diagnosis is correct, symptoms usually promptly recur.

For some patients, arch supports have been prescribed,<sup>3</sup> but these usually have increased the pain in cases of the tarsal-tunnel syndrome, and we have not advised their use.

When conservative treatment fails, surgical decompression of the posterior tibial nerve at the ankle joint should be performed. Our surgical technic is as follows. A curved incision is made beginning above and posterior to the medial malleolus of the tibia, and is continued along the



course of the posterior tibial nerve distally to the point where it passes beneath the abductor hallucis muscle. The flexor retinaculum is incised and the fibrous margin of the abductor hallucis muscle is released. The individual branches of the posterior tibial nerve are identified and are dissected to ensure that they are no longer compressed.

The previously mentioned local causes of the tarsal-tunnel syndrome are then sought. The tendon sheaths of the posterior tibial, flexor digitorum longus, and flexor hallucis longus tendons are then incised and inspected. Cysts, ganglions, lipomas, are removed if they are found. When there is proliferative tenosynovitis of these tendons, synovectomy is performed. A portion of the tendon sheath immediately posterior to the medial malleolus is preserved to prevent dislocation of the tendons postoperatively. The skin and subcutaneous tissue only are closed. Postoperatively, because of the necessary location of the incision, wound healing may be slow. Wound separation and marginal necrosis are not uncommon, but usually heal with conservative local wound care.

Shortly after the operation the patient usually experiences relief of the symptoms. This painlessness may be dramatic in some patients, whereas others may notice a gradual diminution in the symptoms over a period of weeks. This variation is probably related to the length of time that the posterior tibial nerve has been compressed and to the extent of changes present in the nerve at the time of operation.

## Summary

The tarsal-tunnel syndrome or posterior tibial nerve compression produces a painful or abnormal sensation in the sole of the foot. The posterior tibial nerve is compressed by the flexor retinaculum beneath the medial malleolus. We believe that compression of the posterior tibial nerves produces a local ischemia of the nerve, which is responsible for the clinical syndrome.

The diagnosis is confirmed by an increase in the latency times (medial plantar nerve more than 6.1 milliseconds, and lateral plantar nerve more than 6.7 milliseconds) of the branches of the posterior tibial nerve, and by electromyography. Initial conservative therapy consists of injection of 10 mg of triamcinolone acetonide in the tarsal tunnel. Failure of medication to relieve the symptoms is an indication for surgical decompression of the posterior tibial nerve.

## References

1. Keck, C.: The tarsal tunnel syndrome. *J. Bone Joint Surg.* **44-A**: 180-182, 1962.
2. Lam, S. J. S.: A tarsal tunnel syndrome. *Lancet* **2**: 1354-1355, 1962.
3. Edwards, W. G., and others: The tarsal tunnel syndrome; diagnosis and treatment. *J.A.M.A.* **207**: 716-720, 1969.

4. Wilde, A. H.: Surgery of the foot in rheumatoid arthritis. *Cleveland Clin. Quart.* **36**: 85-89, 1969.
5. Lam, S. J. S.: Tarsal tunnel syndrome. *J. Bone Joint Surg.* **49-B**: 87-92, 1967.
6. Kopell, H. P., and Thompson, W. A. L.: *Peripheral Entrapment Neuropathies*. Baltimore: The Williams & Wilkins Company, 1963, 171 p.; p. 25-33.
7. Fullerton, P. M.: The effects of ischaemia on nerve conduction in the carpal tunnel syndrome. *J. Neurol. Neurosurg. Psychiat.* **26**: 385-397, 1963.
8. Phalen, G. S.: The carpal-tunnel syndrome; seventeen years' experience in diagnosis and treatment of six hundred fifty-four hands. *J. Bone Joint Surg.* **48-A**: 211-228, 1966.
9. Denny-Brown, D., and Brenner, C.: Paralysis of nerve induced by direct pressure and by tourniquet. *Arch. Neurol. Psychiat.* **51**: 1-26, 1944.
10. Goodgold, J.; Kopell, H. P., and Spielholz, N. I.: The tarsal-tunnel syndrome; objective diagnostic criteria. *New Eng. J. Med.* **273**: 742-745, 1965.
11. Mavor, H., and Atcheson, J. B.: Posterior tibial nerve conduction. Velocity of sensory and motor fibers. *Arch. Neurol.* **14**: 661-669, 1966.
12. Johnson, E. W., and Ortiz, P. R.: Electrodiagnosis of tarsal tunnel syndrome. *Arch. Phys. Med.* **47**: 776-780, 1966.