

Heart transplantation—report of a case

RENÉ G. FAVALORO, M.D.

DONALD B. EFFLER, M.D.

LAURENCE K. GROVES, M.D.

Department of Thoracic and Cardiovascular Surgery

JOHN F. VILJOEN, M.D.

Department of Anesthesiology

IMPANTATION of a homograft heart offers a chance of survival to each one of a selected group of patients with severe and intractable cardiac disease. The significant experimental work done in the past by Dong and associates,¹ and by Lower, Dong, and Shumway,² and the recent successful clinical results obtained by Barnard³ have demonstrated the feasibility of cardiac transplantation and encourage further clinical application. Our report concerns our experience with the first patient in whom we performed a heart transplantation.

Report of a case

A 49-year-old Caucasian man was admitted to the Cleveland Clinic Hospital on March 20, 1968, because of severe cardiac dysfunction. He had a heart murmur since infancy, and was rejected by the United States Army during World War II because of what was thought to be rheumatic heart disease. He had engaged in heavy labor without distress until the last year (1967), when he began to experience dyspnea on exertion, orthopnea, and episodes of paroxysmal nocturnal dyspnea. In October of 1967 he experienced a half-hour episode of substernal chest pain which recurred several times. He was unable to work since that time. Physical examination revealed that the blood pressure was 100/70 mm Hg, and the pulse was 96 beats per minute and regular. The neck veins were flat when the patient was in a sitting position. The lungs were clear, and the heart showed an apical thrill, grades 3 to 6. There was a holo-systolic murmur at the apex radiating to the axilla, and grades 2 to 6 diastolic blow at the left sternal border, also heard at the apex. The peripheral pulses were normal, and there were no bruits heard at the neck. There was no hepatosplenomegaly. Results of the rest of the physical examination were normal.

An electrocardiogram showed sinus rhythm with premature ventricular contractions. Determinations of electrolyte values, blood urea content, and leukocyte count were normal. A roentgenogram showed that the heart was enlarged, with probably left ventricular, right ventricular, and left atrial enlargement. A complete cineangiographic study* of the left side and of the right side of the heart was performed on March 22, 1968. Coronary artery circulation was shown to be normal. The left ventriculogram revealed extensive and severe impairment of the left ventricular function, with increased end diastolic and end systolic volumes. Ventricular contraction was diffusely impaired. The

* The study was made by our colleagues in the Department of Cardiovascular Disease and Cardiac Laboratory.

mitral valve was normal; the left atrium was slightly dilated with elevation of the left atrial and pulmonary artery pressure because of left ventricular failure. The pulmonary artery pressure was 64/30 mm Hg. The aortic valve was slightly thickened and deformed, but not calcified; it was tricuspid with mild aortic stenosis and mild aortic insufficiency.

The final diagnosis was primary myocardial disease, with significant impairment of the left ventricular function, aortic valve disease possibly congenital, mild aortic insufficiency, and mild aortic stenosis. The patient was discharged on March 30, 1968, with the advice to follow a regimen of total bed rest, only $\frac{1}{2}$ gr dietary sodium daily, digitalis, restriction of fluid intake, diuretics, and minimal sedation.

On May 14, 1968, he was readmitted to the hospital because of cardiac distress. His blood pressure was 90/60 mm Hg, and pulse rate was 108. He appeared extremely pale and cyanotic with jugular venous distension. There were rales at both lung bases, and the liver was palpable two fingerbreadths below the costal margin. His condition appeared terminal. The laboratory data showed that the pH of blood was 7.17, carbon dioxide content 16.5 meq per liter, carbon dioxide tension 55 mm Hg, oxygen tension 35 mm Hg, and oxygen saturation 65 percent. He was given intensive medical treatment, and amazed us with his improved condition.

On May 25, 1968, an episode of hemoptysis with no significant respiratory distress occurred. The possibility of a pulmonary embolus was considered. On May 27, 1968, he was acutely dyspneic, and that evening suffered further episodes of acute pulmonary edema with associated hypotension. The serum glutamic oxaloacetic transaminase was 1140 U, lactate dehydrogenase 3800 U, and creatine phosphokinase 88 U. The prothrombin time was more than 50 sec (control, 12 sec) due to hepatic failure. A strict medical regimen was instituted and maintained, and he was discharged from the hospital on June 7, 1968, moderately improved. The patient remained at home at complete bed rest, but had several episodes of acute left ventricular failure.

On September 4, 1968, he was readmitted to the hospital, to undergo cardiac transplantation, which was performed the same day. The donor was a 25-year-old Caucasian woman who had died as a result of irreversible brain damage.

Operative technic

The heart of the deceased donor was removed surgically under standard operating conditions. In the meantime, the recipient had been brought to an adjoining operating room where the operating team first performed a cutdown in the groin, and a venous catheter was inserted into the inferior vena cava through the saphenous vein. A Rochester needle was inserted into the right femoral artery for the monitoring of the mean arterial blood pressure.

A median sternotomy was performed, while concurrently the left femoral artery was exposed for cannulation. Heparin was administered, and a large plastic cannula was inserted into the left femoral artery for arterial return from the pump-oxygenator. At that time, bradycardia and hypotension developed, which were controlled with an intravenous injection of atropine and isoproterenol. The vena cavae were quickly cannulated. One cannula was inserted directly into the superior vena cava through a purse-string suture in the middle of the intrapericardial portion. Another cannula was inserted in the inferior vena cava through a purse-string suture placed laterally at the junction with the right atrium. The left atrium was vented. Umbilical tapes were placed around the aorta and the pulmonary artery.

Mechanical cardiopulmonary bypass was started, and, with the patient

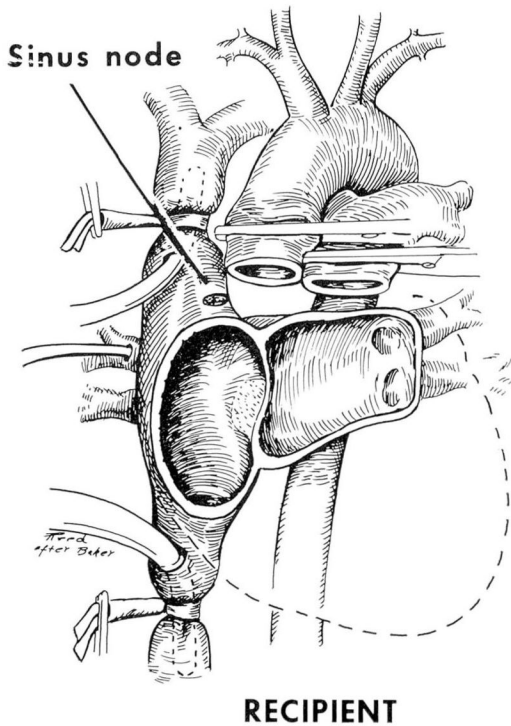
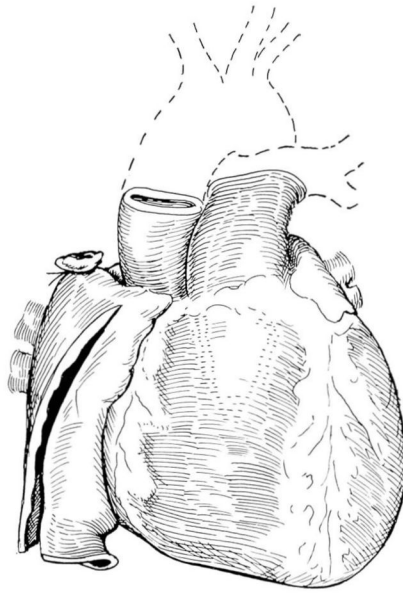


Fig. 1. Sketch showing the aorta and pulmonary artery after being divided (recipient was attached to the heart-lung machine). Most of the right and left atria are left intact.

on total bypass, the aorta and pulmonary arteries were clamped and transected close to the heart, leaving as much length of these vessels as possible to facilitate the subsequent anastomoses. The right atrium and left atrium were incised close to the atrioventricular grooves, leaving the major portion of the atrial chambers in situ. The interatrial septum was then divided (*Fig. 1*).

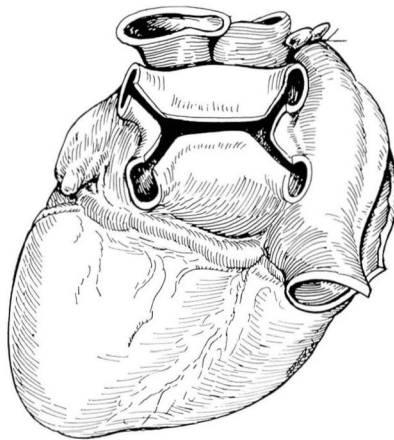
The donor heart, which had been brought to the operating room of the recipient, was prepared for implantation. In accordance with Barnard's³ suggestion, the donor right atrium was opened longitudinally, starting on the lateral wall of the inferior vena cava and going upward to the left atrial appendage, thus avoiding injury to the sinus node and sino-atrial pathway (*Fig. 2*). The left atrium was opened transversely between the pulmonary veins (*Fig. 3*).

The donor heart was held in position on the left side of the recipient pericardial space. The lateral wall of the left atrium was anastomosed first, and then the medial wall of the donor left atrium to the recipient septum (*Fig. 4*). The donor right atrium was anastomosed in the same fashion, the



DONOR

Fig. 2. Sketch showing that the superior vena cava is ligated. The right atrium is opened longitudinally up to the right atrial appendage to avoid injury to the sino-atrial node.



DONOR

Fig. 3. Sketch showing that the left atrium is open behind and between the pulmonary veins.

medial wall to the septum of the recipient and finally the lateral wall (Fig. 5). Next, an end-to-end anastomosis of the aorta was performed. The aorta of the donor heart was transected in an oblique plane, since it was small compared to that of the recipient aorta.

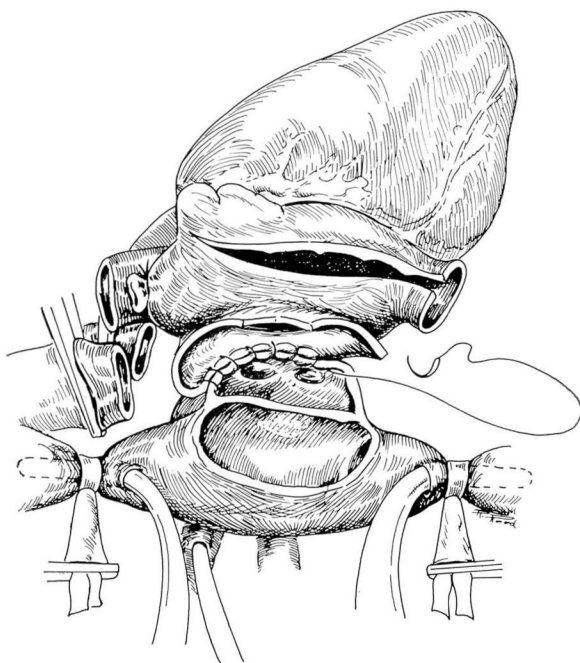


Fig. 4. Sketch showing that the left atrial chambers are anastomosed first, starting on the lateral wall. The medial wall is sutured to the septum.

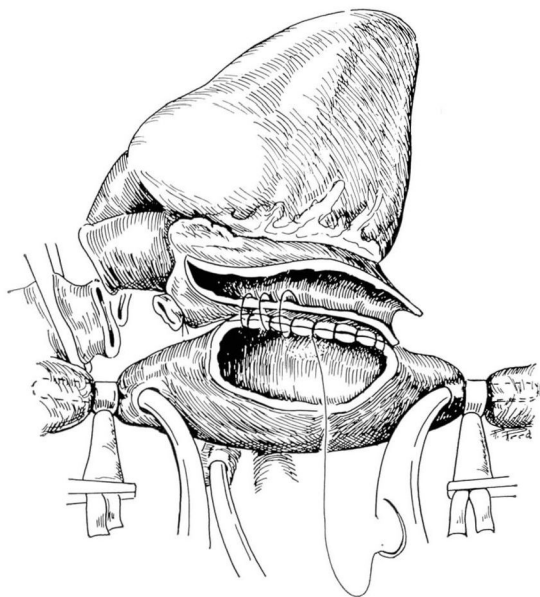


Fig. 5. Sketch showing that the right atrial chambers are anastomosed in the same order—the medial wall of the donor to the septum of the recipient, and the lateral walls of both recipient and donor.

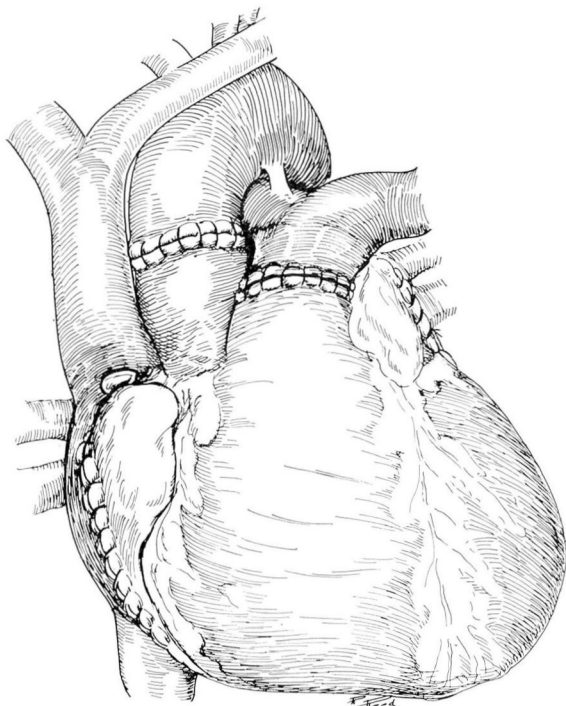


Fig. 6. Sketch showing the aorta and pulmonary artery anastomosed with running sutures.

After the anastomoses were completed, the aortic clamp was released for about three minutes. The anastomoses were reinforced as indicated. The aorta was again clamped and the pulmonary artery was anastomosed end to end (*Fig. 6*). All of the anastomoses were performed in the same fashion with running sutures of 4-0 Mersilene. Several small leaking points were reinforced with interrupted 4-0 silk sutures. The donor heart was kept without coronary perfusion under normothermic temperature. The cardiopulmonary bypass was also kept in normothermia. The total time for the anastomoses was 35 min, and the patient was on cardiopulmonary bypass for 47 min.

Spontaneous resumption of heartbeat occurred almost immediately after first unclamping the aorta, and sinus rhythm was quickly established. Hemodynamic stability prevailed. Routine decannulations were performed and protamine sulfate was given to neutralize the heparin previously administered. An electrode was placed on the anterolateral wall of the right ventricle for use, if necessary, to control postoperative arrhythmias by an external pacemaker. The median sternotomy was closed with wire sutures, and the patient was transported to an isolated room.

The operation started at 5:18 pm and was completed at 7:25 pm. Two

hours later the patient regained full consciousness, but the endotracheal tube was left in place until 7:30 am the next morning.

All vital signs remained stable until 24 hours postoperatively when the blood pressure started to fall coincidentally with bloody drainage from the chest drains. Blood loss was replaced by transfusion, and the mean systemic blood pressure remained between 80 and 90 mm Hg. A diagnosis of postoperative bleeding and cardiac tamponade was made, based on findings of pallor, persistent and increasing tachycardia, narrowed pulse pressure, tachypnea, decreased urine output, and neck vein distension with a steadily rising venous pressure. The patient was returned to the operating room at 6:00 pm that day (September 5, 1968). The median sternotomy closure was reopened and about 1200 ml of blood clots was found in the pericardium, which were evacuated. The systemic blood pressure then rose to 130/80 mm Hg after evacuation of the clots.

The site of bleeding was a small lateral branch of the right coronary artery which had been lacerated by the tip of the electrode placed on the anterolateral wall of the right ventricle. A single 4-0 silk suture stopped the bleeding. The anastomoses were inspected and looked in perfect condition without any leakage. It was gratifying to see the strong heartbeat. The electrode was removed, and from then on the patient had an uneventful recovery. He was ambulatory on the third postoperative day, but was kept in isolation for 10 days. He was discharged from the hospital to his home on September 26, 1968, the twenty-second postoperative day, in excellent general condition.

Comment

Heart transplantation is a new clinical endeavor, and several problems are still to be solved related to operative details, histocompatibility typing, and postoperative immunosuppressive therapy. The operative technic is well standardized, based on open-heart surgical principles, and does not present any unusual difficulties to a well-organized surgical team. There are minor details that vary, depending on the individual surgeon's experience and preference. For example, we strongly believe that coronary perfusion is not necessary, a concept upheld by our experience with aortic and mitral valve replacements performed at the Cleveland Clinic Hospital with the patients under anoxic arrest. We also believe that peripheral venous cannulation for perfusion is not indispensable.

Histocompatibility typing and immunosuppressive therapy are two aspects that seem to be especially important in regard to heart transplantation. Compatibility between recipient and donor in the ABO erythrocyte antigen group is mandatory, as well as leukocyte antigen serotyping as a guide to histocompatibility between donor and recipient. The pertinent data in the case we report are as follows. The recipient is blood type A,

and the donor was type O. The tissue typing was in Group D of the Terasaki classification,⁴ indicating that two major groups (Te7-Te3) were mismatched. In this particular instance, the terminal condition of the donor required that the transplantation be performed on the basis of ABO blood group compatibility. The significance of tissue typing is currently uncertain and requires long-term follow-up study. On the basis of experience with renal transplantation, generally, when one or two major groups are mismatched, rejection is likely to develop in the recipient, and high doses of suppressive medication are required. There are many exceptions, though, and much has to be learned about this subject. For example, the "Richmond patient" discussed in the report by Terasaki, Patel, and Von Diepow⁴ represented the best match possible but died of severe rejection on the seventh day. Laboratory facilities at the Cleveland Clinic Hospital allow preliminary preoperative typing and the matching of suitable donors and recipients.

Immunosuppressive therapy entails the use of antilymphocyte globulin (ALG), azathioprine, and prednisone. The use of antilymphocytic serum is a great advance in therapy, mainly because it allows reduction in the dosages of azathioprine and prednisone, as demonstrated by Starzl and associates.⁵ The Cleveland Clinic Foundation produces its own ALG which has been used in renal transplantation, and results have confirmed the results obtained by Starzl and associates.

The ALG is given daily for two weeks, every other day for two weeks, twice a week in the next two weeks, and then once a week. The dosage is 5 ml per injection. Since ALG is a heterologom animal product, the patient must be closely watched for anaphylactic and serum reactions. The initial dosage of azathioprine on the day of transplantation was 4 mg per kilogram of body weight, or 280 mg. The dosage then ranged between 150 and 175 mg, depending on the extent of depression of the leukocyte count. Prednisolone (100 mg) was administered intravenously on the day of the operation, followed by a daily oral dose of 100 mg. On the ninth postoperative day the dosage was 90 mg, but the electrocardiogram for the first time showed notable reduction in the voltage of the QRS complex (*Fig. 7*), and on the next day 180 mg was given. The electrocardiogram returned to a normal pattern on September 17, 1968, and remained unchanged the rest of the time the patient was in the hospital.

The best bases for judging onset and extent of rejection of homografts we have found to be: electrocardiography (QRS amplitude), lactate dehydrogenase isoenzyme patterns, and leukocyte count, in addition to the usual vital signs.

The indication for heart transplantation and the selection of the recipient must be most carefully considered. At present the operation is justified only in patients who have far-advanced heart disease with intractable chronic congestive cardiac failure: (1) primary myocardial disease, (2) coro-

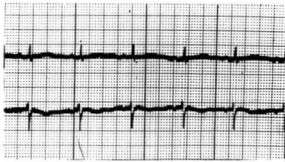
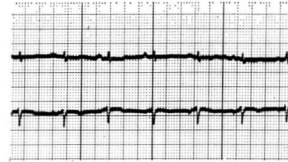
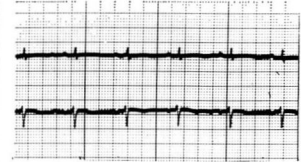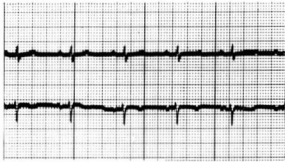
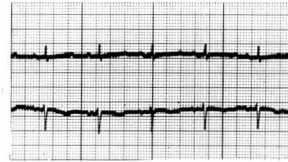
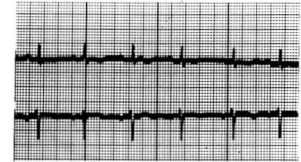
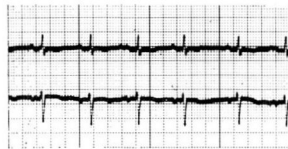OPERATION SEPTEMBER 4, 1968**Mon. Sept. 9 1968****Tues. Sept. 10, 1968****Fri. Sept. 13, 1968****Sun. Sept. 15, 1968****Tues. Sept. 17, 1968****Fri. Sept. 20, 1968****Thurs. Sept. 26, 1968**

Fig. 7. Electrocardiograms of the patient (lead II). On September 10, 1968, there was significant reduction of the QRS complex; the patient was given an increased dosage of prednisone. The pattern returned to normal on September 17, 1968.

nary arteriosclerosis with scar-tissue replacement of the left ventricle, (3) rheumatic heart disease with multivalvular lesions, or (4) types of congenital dysfunction not amenable to surgical repair. At the Cleveland Clinic Hospital the selection of potential recipients is made after consultation by three staff physicians of the Department of Clinical Cardiology. The selection of the donor and the determination of death are subject to precise criteria. The donor should be less than 50 years of age with no history of heart disease. A standard roentgenogram of the chest and an electrocardiogram are made before the operation. A crucial matter that has been the subject of much discussion is how to define death although the heart is still beating. There is now general agreement that the patient should be in coma, not responsive to any stimuli, with both pupils fixed and dilated, must require respiratory support by a mechanical ventilator, and that at least two electroencephalograms show total absence of electrical activity in the brain. For this particular decision, we also have a committee that includes staff members of the Department of Neurology who certify the death of the cerebrum of the patient.

Conclusion

Cardiac transplantation is an extremely rare clinical procedure. However, more than 100 patients in the world who have undergone such transplantation have confirmed the fact that the surgical procedure is entirely feasible. Evaluation of the final status of the procedure must await further clinical and experimental data, as the magnitude of the rejection problem remains largely unknown. At present, heart homografts are only for those patients who are in a preterminal condition without other hopes for improvement.

The transplantation of hearts should be performed only in those medical institutions with: (a) previous clinical experience in renal transplantation, (b) an experienced open-heart surgical team, and (c) laboratory facilities available for tissue typing. The organization of the surgical-medical program is important. We believe that two committees independent of the transplantation surgical team are necessary to evaluate the donor and the recipient of a homograft on scientific and ethical bases. Cooperation from the neighboring medical centers is invaluable to have a well-organized program and to obtain donors. The new concept of death of the cerebrum is important, and public education in this regard will be essential if wider use is to be made of this type of heart surgery.

Addendum

The patient whose heart transplantation is described in this report has remained in good condition six months since the operation. Complete evaluation, including catheterizations of the right side and the left side of the heart, and selective coronary angiography, was performed on January 8, 1969. The studies revealed good function of the left ventricle. The end diastolic left ventricular pressure and left atrial pressure remained within normal limits.

A heart transplantation was performed in a second patient, on December 16, 1968, a 21-year-old man who had intractable heart failure due to primary myocardial disease. The deceased donor was a 21-year-old man whose death occurred as a result of acute irreversible brain damage. The operation utilized the same technic as described in the foregoing report, and the recipient had an uneventful recuperation. He was discharged from the hospital on January 21, 1969, in good condition, but was readmitted five days later because of acute deterioration. He died on January 28, 1969, because of heart failure resulting from acute rejection as confirmed by the necropsy findings.

References

1. Dong, E., Jr., and others: Performance of the heart two years after autotransplantation. *Surgery* 56: 270-273; discussion, 273-274, 1964.
2. Lower, R. R.; Dong, E., Jr., and Shumway, N. E.: Long-term survival of cardiac homografts. *Surgery* 58: 110-119, 1965.

3. Barnard, C. N.: What we have learned about heart transplants. *J. Thorac. Cardio. Surg.* **56**: 457-468, 1968.
4. Terasaki, P. I.; Patel, R., and von Diepow, M.: Serotyping for homotransplantation XXIV. Possible role in heart transplantation. *Amer. J. Cardiol.*: In press.
5. Starzl, T. E., and others: The clinical use of antilymphocyte globulin in renal homotransplantation. *Transplantation* **5**: 1100-1105, 1967.