

Trends in the management of scoliosis

CHARLES M. EVARTS, M.D.

Department of Orthopedic Surgery

WATCHFUL waiting" in regard to children with scoliosis is no longer an acceptable form of management. Prompt and effective treatment is now possible because of recent improvements in technic and in devices. Five of these important advances are: the localizer cast,^{1, 2} the Milwaukee brace,³ the halo apparatus,⁴ Harrington instruments and devices,⁵ and the massive autogenous iliac bone graft for spinal fusion.⁶ The greatest challenge now facing the orthopedic surgeon is in clarifying the etiology of idiopathic scoliosis.⁷

Localizer cast

The localizer cast developed in 1952^{1, 2} offers important advantages in comparison with its predecessor the turn-buckle cast: earlier postoperative ambulation of the patient, less time-consuming and less difficult application. The localizer cast is applied on a special frame and requires a minimal amount of padding. A distraction force is applied by means of traction on the chin and pelvis. This force helps to correct the spinal curvature. Posterolateral forces are then directed by means of pushers into the apex of the curves, and help to correct the rotary deformity of the spine as well as the lateral curvature. A well-molded pelvic plaster cast is applied, and a thoracic, neck, and chin plaster piece is constructed to fit beneath the mandible and under the occiput. Large windows, including a cardiac and abdominal window, are fashioned over the anterior cast (*Fig. 1A and B*). A large posterior window is created over the fusion area and the iliac crest. Knowledge of the correct application of this type of body cast is basic to any program of therapy for scoliosis.

Milwaukee brace

The introduction and perfection of the Milwaukee brace has been a significant advance in the treatment of scoliosis. It is an effective method of obtaining and maintaining partial correction of a scoliotic curve. The application of the Milwaukee brace allows control of a spinal curvature. Its use is confined to the growing child, but it can be applied to a child as young as three years of age and it will inhibit progression of a curve in a child between 5 and 10 years of age (*Fig. 2A and B*). Its greatest use is in the age range between 10 years and the time of cessation of bone growth. The construction of a brace requires the services of a competent orthotist who

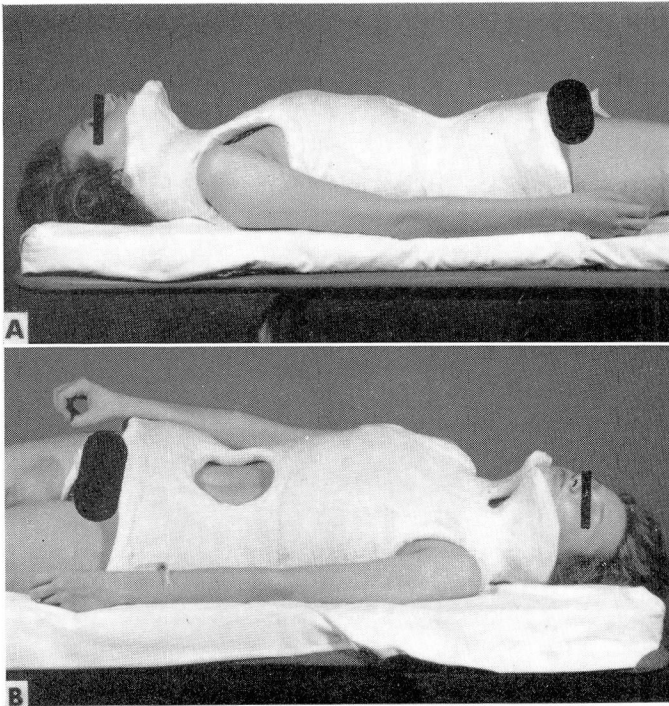


Fig. 1. Photos showing the localizer cast on a patient: **A**, lateral view; **B**, view showing neck and abdominal windows.

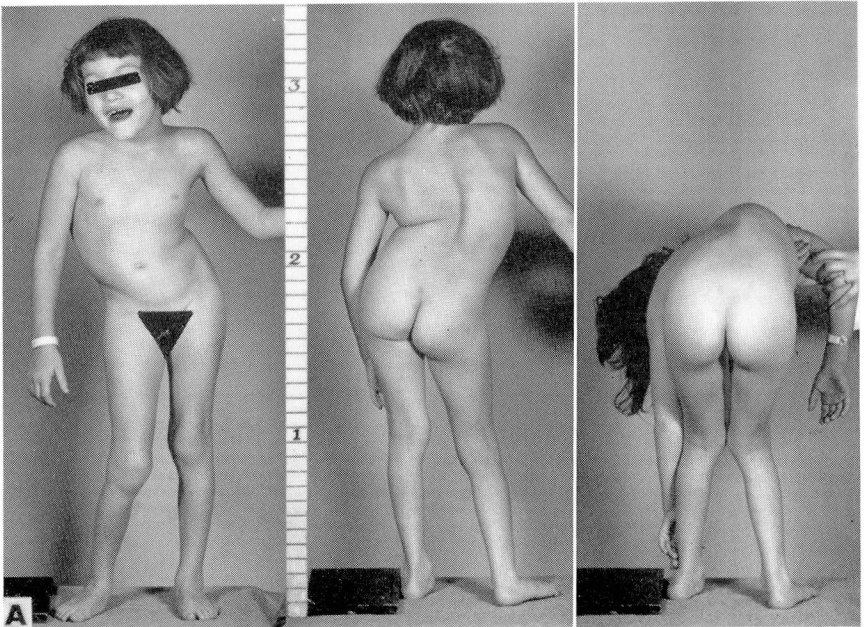

Fig. 2. A, Photo of an eight-year-old cerebral palsy patient with right thoracic scoliosis.

must be willing to accept and to follow the pattern of construction as outlined by Blount.³ The brace provides passive as well as active or dynamic corrective forces. Constant activity is encouraged for the patient wearing the brace, and routine posture and breathing exercises are performed by the patient while in the brace. Continuous daily use of the brace is essential, once treatment is begun. A thorough trial in a Milwaukee brace is necessary before considering spinal fusion for scoliosis in a growing child.

Halo apparatus

The use of skeletal traction by means of halo skull traction apparatus^{8, 9} and counter femoral pin traction allows correction and stabilization of severe curves (*Fig. 3A through E*). With the patient under local anesthesia, the metal halo apparatus is attached to the outer table of the skull by four pins. This form of distraction is useful when respiratory function is impaired and external pressure must be avoided. Distraction forces are applied over a period of two or three weeks to obtain correction before spinal fusion. The fusion is then performed with traction forces still in

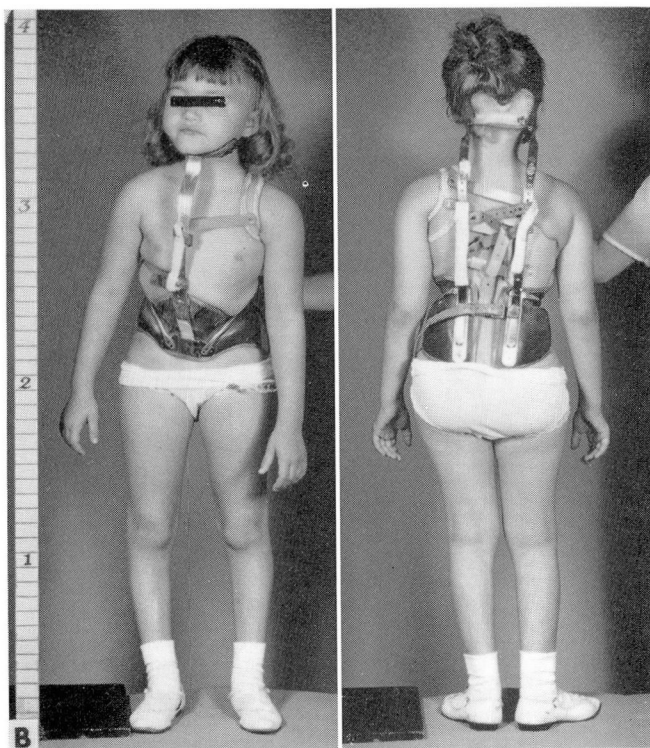


Fig. 2. B, Anterior and posterior views of Milwaukee brace on the child (*Fig. 2A*), showing partial correction of spinal curvature.

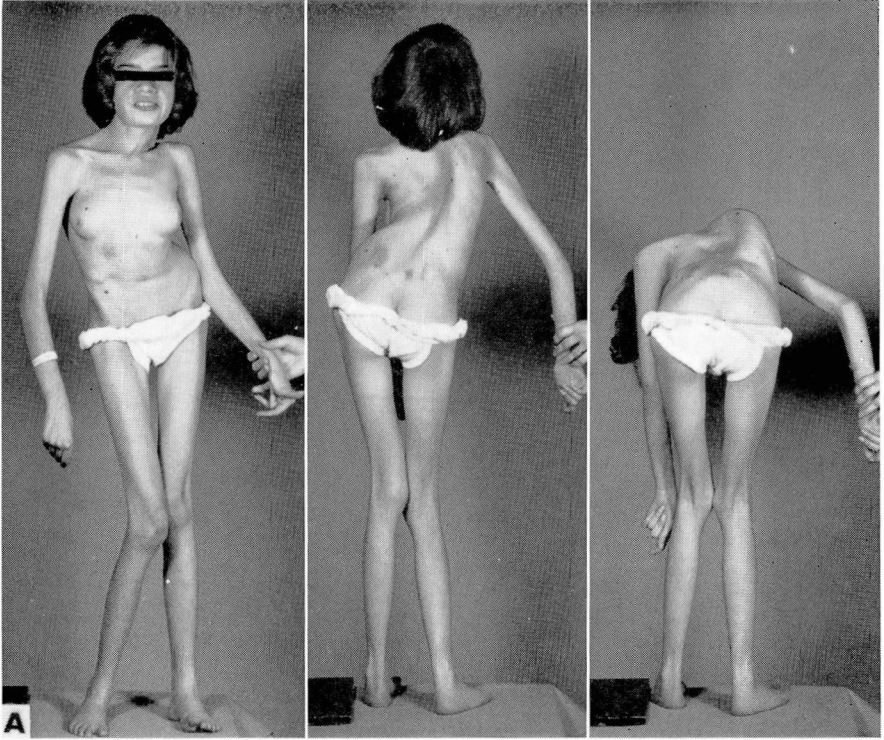


Fig. 3. A, Photo of a 14-year-old patient with a rigid neurogenic spinal curve. (Courtesy of Evarts, C. M.: The management of unusual types of scoliosis: report of four illustrative cases, *Cleveland Clin. Quart.* 33: 1–12, 1966; and of the *Cleveland Clinic Quarterly*.)

effect. Postoperatively, traction is continued with application of a halo cast, Milwaukee brace, or localizer cast, at three weeks.¹⁰

Harrington instruments and devices

Most methods employed in the treatment of scoliosis utilize external corrective forces. After many modifications and clinical trials between the years of 1947 and 1960, a metallic system was devised by Harrington⁵ for use in the surgical treatment of scoliosis. The system is designed to exert an internal corrective force directly upon the rotary and angular deformity of the spine. The device consists of a distraction rod that is placed on the concave side of the curve, and a compression rod that is placed on the convex side of the curve, each by means of metal purchasing hooks (*Fig. 4*). The advantages of the Harrington apparatus are: it provides a direct internal corrective force and exerts a greater influence upon the rotary deformity of the spine; it obtains greater correction in severe, rigid, congenital scoliosis; it allows greater internal fixation, and it decreases the

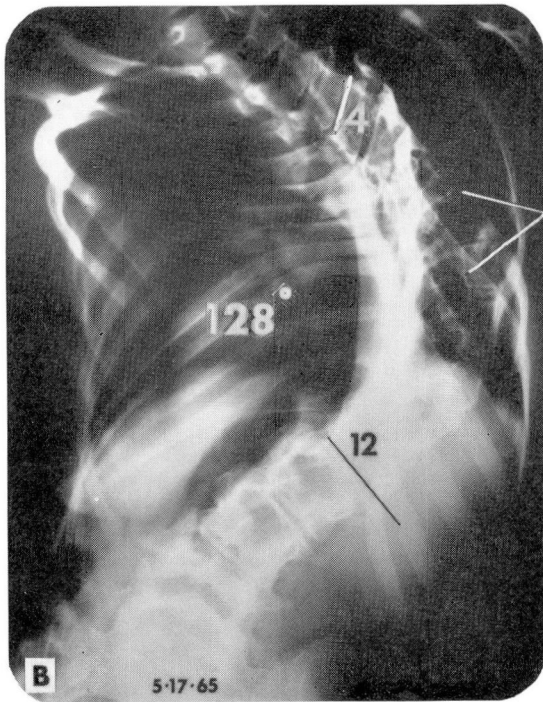


Fig. 3. B, Roentgenogram of child (Fig. 3A), anteroposterior view of right thoracic spinal curve of 128 degrees. (Courtesy of Evarts, C. M.: The management of unusual types of scoliosis: report of four illustrative cases, *Cleveland Clin. Quart.* 33: 1-12, 1966; and of the *Cleveland Clinic Quarterly*.)

period of postoperative immobilization than has been heretofore possible. Harrington instrumentation has provided a most useful adjunct in the management of scoliosis (Fig. 5A through C).

Massive autogenous iliac bone graft for spinal fusion

Goldstein¹¹ has made the fusion operation itself worthy of special comment. He emphasizes that careful, precise, surgical technic, expert anesthesia, and complete replacement of blood lost during the operation are important for successful scoliosis surgery (Fig. 6A through D). A wide subperiosteal exposure, meticulous removal of all soft tissue, and facet joint disruption are necessary. A wide area of cancellous bone surface must be exposed by complete decortication of the posterior aspects of the lamina and transverse processes of the thoracic spine. In the lumbar area, resection of the posterior portion of the articular processes is worthwhile. He has demonstrated that a large amount of fresh autogenous iliac bone should be placed into the fusion area. *There is no substitute for the osteogenic potency of fresh autogenous cancellous bone.* The fusion

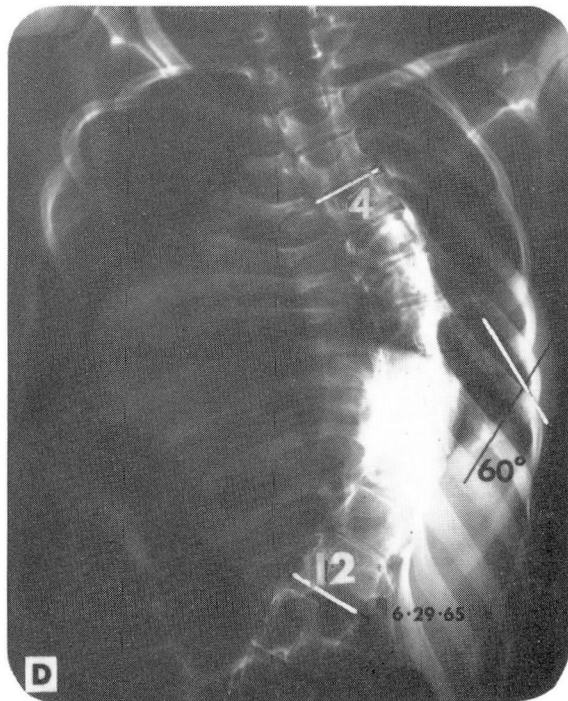
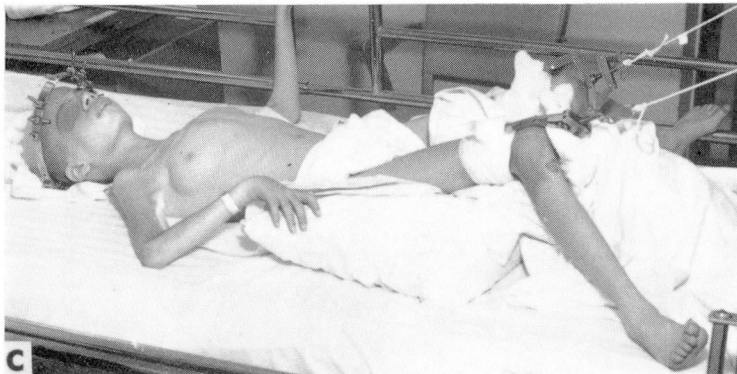


Fig. 3. C, Photo of child (Fig. 3A), showing halo apparatus and femoral skeletal distraction without localizer cast. D, Roentgenogram showing curve correction to 60 degrees after halo and femoral distraction for 19 days. (Courtesy of Evarts, C. M.: The management of unusual types of scoliosis: report of four illustrative cases, *Cleveland Clin. Quart.* 33: 1-12, 1966; and of the *Cleveland Clinic Quarterly*.)

area must include all of the vertebrae of the major curve, and in addition those rotated toward the convexity of the curve. When there is some question as to the end vertebra, an extra vertebra should be fused above and below the primary curve. In most cases an adequate amount of bone

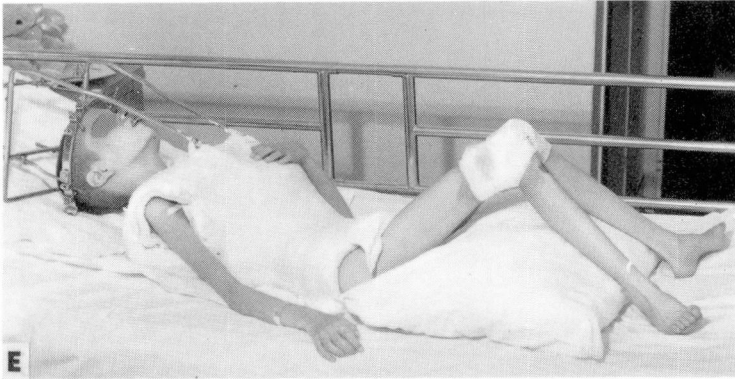

Fig. 3. E, Photo of child (Fig. 3A), showing halo apparatus incorporated into a localizer cast. (Courtesy of Evarts, C. M.: The management of unusual types of scoliosis; report of four illustrative cases, *Cleveland Clin. Quart.* 33: 1-12, 1966; and of the *Cleveland Clinic Quarterly*.)

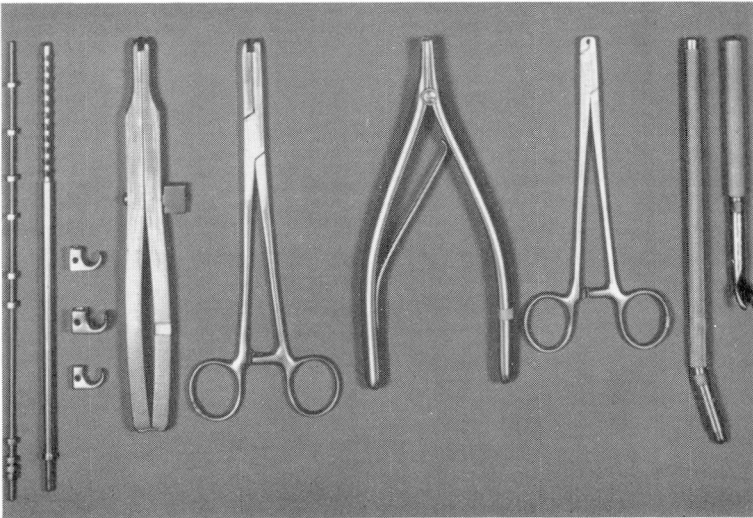


Fig. 4. Harrington instruments.

can be obtained from the posterior two thirds of the outer table of the ilium. Goldstein and Evarts¹² have obtained exceptionally low pseudoarthrosis rates with these basic methods of treatment.

Summary

In the last decade, significant advances have been made in the management of scoliosis in children. It has become possible to institute a treatment program shortly after the diagnosis is established. An early, aggressive approach to congenital and idiopathic scoliosis is now mandatory.

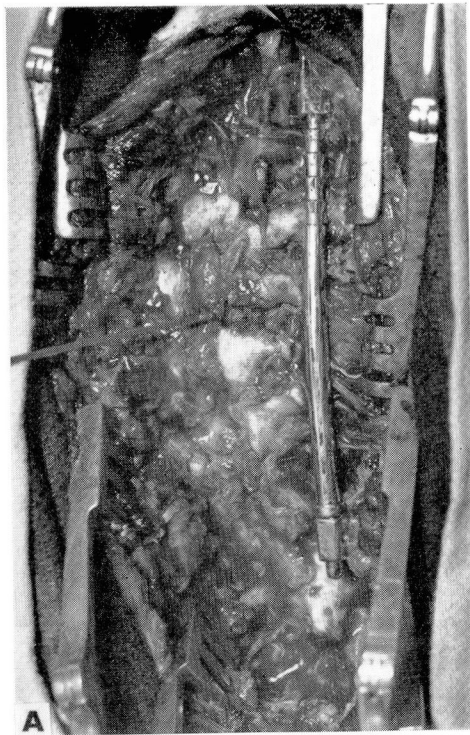


Fig. 5. A, Photo at operation, showing Harrington distraction rod bridging the osteotomy site.

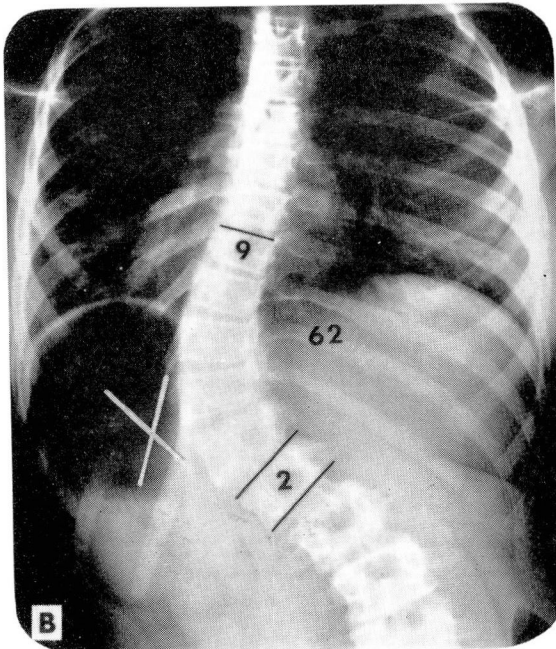


Fig. 5. B, Roentgenogram, preoperative anteroposterior view, showing idiopathic left thoracolumbar spinal curve.

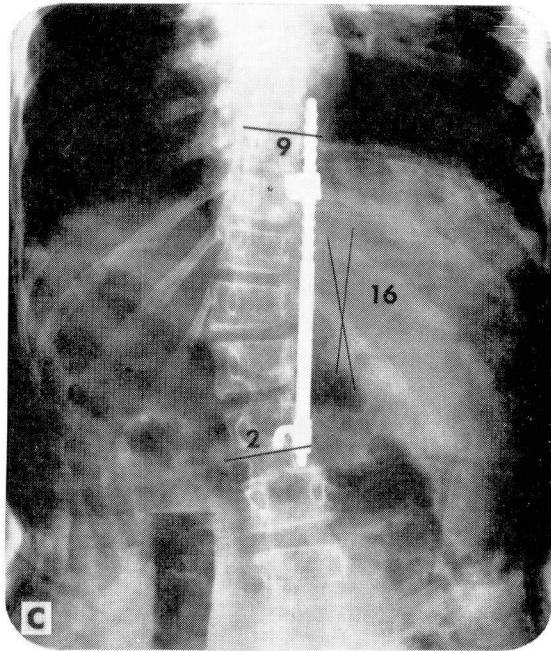


Fig. 5. C, Roentgenogram, postoperative anteroposterior view, showing left thoracolumbar spinal curve with Harrington distraction rod extending from the ninth thoracic vertebra to the second lumbar vertebra.

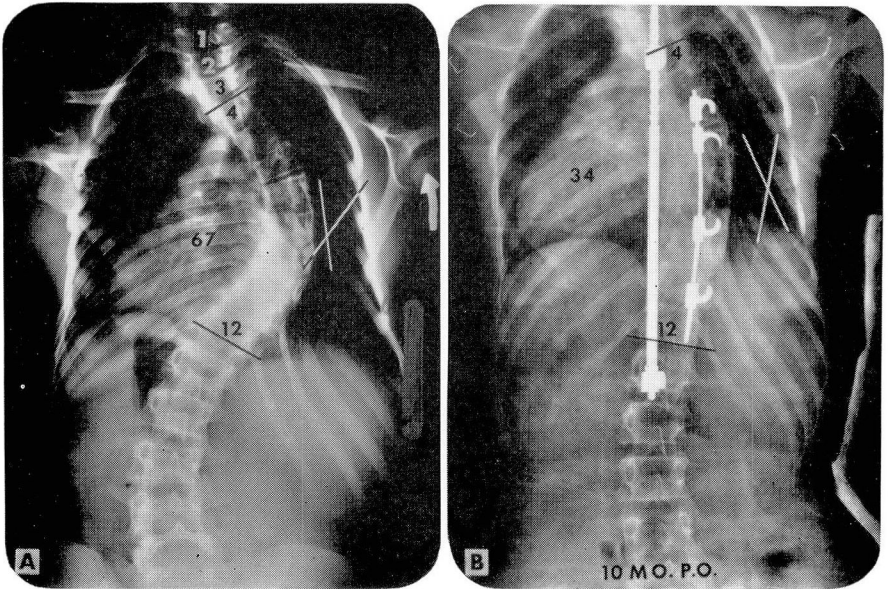


Fig. 6. Roentgenograms: **A**, preoperative anteroposterior view, showing idiopathic right thoracic spinal curvature; **B**, postoperative, showing correction of spinal curvature with Harrington compression and distraction rods to 34 degrees.

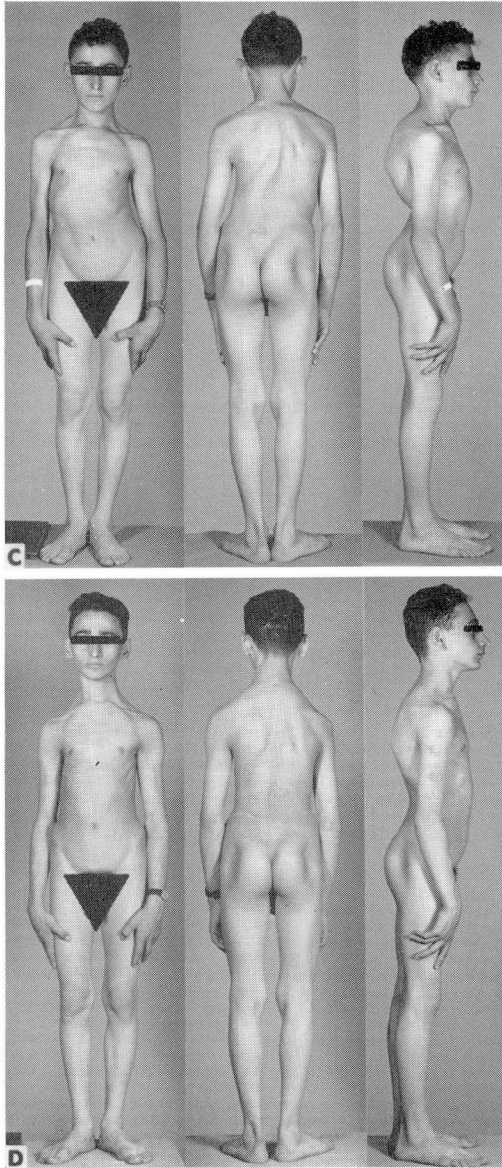


Fig. 6. Photos, anterior, lateral, and posterior views; C, preoperative; D, postoperative.

Prompt surgical intervention is permissible, and improved surgical techniques have greatly lowered the rate of pseudoarthrosis after spinal fusion. However, the greatest challenge of the management of scoliosis remains in the clarification of the cause of idiopathic scoliosis.

References

1. Risser, J. C.: Application of body casts for correction of scoliosis. *Amer. Acad. Orthop. Surgeons. Lect.* **12**: 255-259, 1955.
2. Risser, J. C., and others: Three types of body casts. *Amer. Acad. Orthop. Surgeons. Lect.* **10**: 131-142, 1953.
3. Blount, W. P.: Scoliosis and the Milwaukee brace. *Bull. Hosp. Joint Dis.* **19**: 152-165, 1958.
4. Nickel, V. L., and others: Application of the halo. *Orthop. Prosthet. App. J.* **14**: 31-35, 1960.
5. Harrington, P. R.: Treatment of scoliosis; correction and internal fixation by spine instrumentation. *J. Bone Joint Surg.* **44-A**: 591-610, 1962.
6. Goldstein, L. A.: Surgical management of scoliosis. *J. Bone Joint Surg.* **48-A**: 167-196, 1966.
7. Riseborough, E. J.: Current concepts. Treatment of scoliosis. *New Eng. J. Med.* **276**: 1429-1431, 1967.
8. Evarts, C. M.: The management of unusual types of scoliosis; report of four illustrative cases. *Cleveland Clin. Quart.* **33**: 1-12, 1966.
9. Garrett, A. L.; Perry, J., and Nickel, V. L.: Stabilization of the collapsing spine. *J. Bone Joint Surg.* **43-A**: 474-484, 1961.
10. Winter, R. B.; Moe, J. H., and Eilers, V. E.: Congenital scoliosis; a study of 234 patients treated and untreated; part I: natural history; part II: treatment. *J. Bone Joint Surg.* **50-A**: 1-47, 1968.
11. Goldstein, L. A.: *The Surgical Treatment of Scoliosis*. Springfield, Ill.: Charles C Thomas, Pub., 1959, 116 p.
12. Goldstein, L. A., and Evarts, C. M.: Follow-up notes on articles previously published in *The Journal*. Further experiences with the treatment of scoliosis by cast correction and spine fusion with fresh autogenous iliac-bone grafts. *J. Bone Joint Surg.* **48-A**: 962-966, 1966.