

Secondary reconstruction of the mandible: technic of intraoral immobilization

SHATTUCK W. HARTWELL, JR., M.D.

Department of Plastic Surgery

BURTON P. SIEGEL, D.D.S.

Dental Consultant, Cleveland, Ohio

COMMON structural disorders of the mandible are partial loss, malunion, and nonunion after operations or fractures (*Fig. 1*). Impaired function and appearance require reconstruction. This is a discussion, with examples, of mandibular intraoral immobilization that is essential to a successful reconstruction.

GOALS

The goals in surgical repair of the mandible are twofold: adequate function and acceptable appearance. The principal objective in the secondary reconstruction of the lower jaw is that the patient be able to chew food without discomfort. This means that there must ultimately be adequate motion of the temporomandibular joints, and a rigid mandibular arch to hold existing or prosthetic dentition in a controlled relationship with the upper dental arch. Improved appearance may also be an aim of the reconstruction in patients with segmental mandibular defects or with malunion after fracture. Goals must be reasonable, and the patients must be fully informed of what is possible and of the probable outcome of surgical treatment. The reconstruction of the lower jaw can only be achieved within the limitations of available soft tissue, blood supply, and potential joint motion.

METHODS

Preoperative planning. It is necessary to plan preoperatively the form and position of the reconstructed lower jaw. Dental impressions are made of the upper and lower arches, and from these impressions study models are constructed and mounted on an articulator (*Fig. 2*). The lower arch of the study model is shifted into a desirable relationship with the upper jaw. Cutting the mandibular model permits repositioning, and the need for either grafting or resecting will become obvious. A secure intermaxillary relationship (upper jaw to lower jaw) must be designed to permit healing of the mandibular reconstruction.

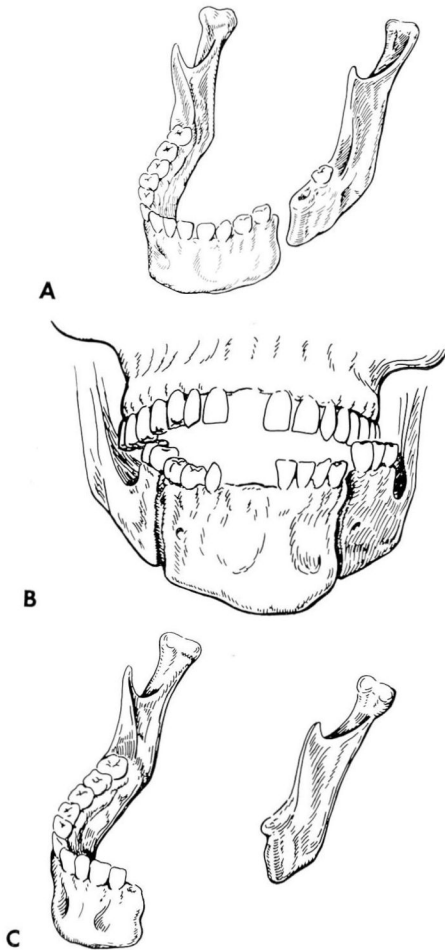


Fig. 1. A, Drawing of nonunion after fracture. B, Drawing of posttraumatic malunion with open-bite deformity. C, Drawing showing postoperative mandibular defect.

Intermaxillary splinting. Where there is adequate dentition, the interlocking of the dental surfaces in occlusion provides immobilization of the jaws. No appliance is needed except the dental arch bars and wire ligatures or intermaxillary elastic bands (Fig. 3); these are applied when needed and are not prefabricated.

Placing and holding study models of upper and lower jaws in the desired position may require a special appliance suited to the situation. These splints are prefabricated on the study models (Fig. 2 and 4). Complete or partial loss of teeth is common, and the splints serve to build up the alveolar processes and to provide a biting plane for the opposite jaw.

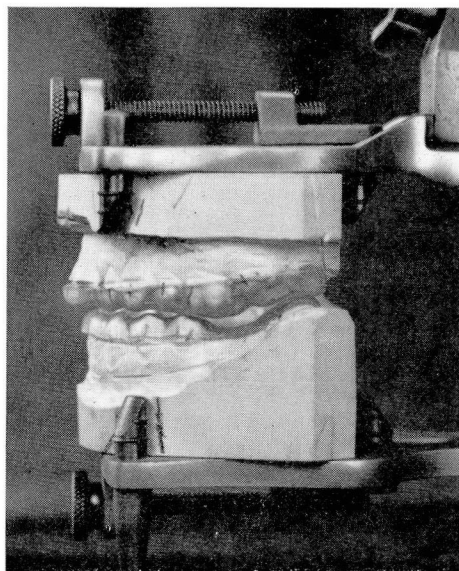


Fig. 2. Models of upper and lower jaws are placed in desired relationships. Note clear acrylic splint in the occlusion.

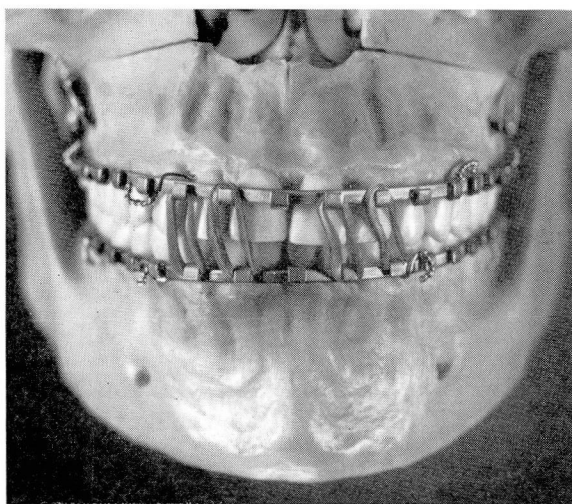


Fig. 3. Photograph of fixed occlusion with dental arch bars and interconnecting elastics.

Splints may be of a type that builds up or interlocks the occlusal plane that already exists between upper and lower dentition. Such appliances are called bite-plane splints and are used when the dental cusps or occlusal

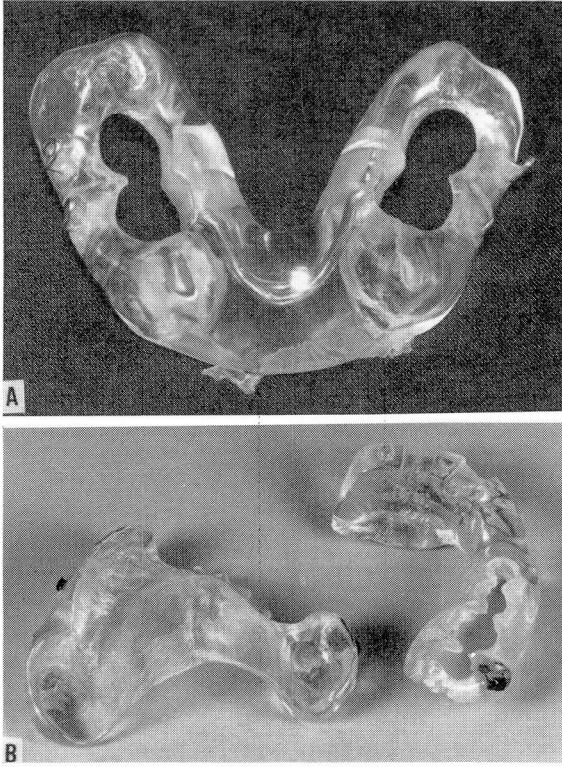


Fig. 4. A, Photograph of splint used to stabilize the mandible. Remaining lower teeth pass through the holes. B, Photograph of maxillary and mandibular splints.

surfaces do not fit well after the desired bony realignment has been established. In such instances, the bite-plane splint serves to hold the mandible rigid until bony union at the site of the reconstruction is secure. Thereafter, occlusal adjustment is accomplished by grinding, extractions, tooth movement, or prosthetics.

Splint fixation. Wire ligatures, passed around or through facial bones, hold the splints in place. The anterior nasal spine and the zygomatic arches provide points of suspension from the upper dental arch. A hole is made through the anterior nasal spine, and a wire through this is then passed through a hole or hook in the splint. Ligature-carriers direct the wires around the zygomatic arches, and these wires are attached to the splints bilaterally in the upper buccal sulcus.

Circummandibular or circumdental wires secure splints to the lower jaw. The structural problem indicates the choice of combination of ligature points. Intermaxillary (i.e., between the jaws) fixation is the immo-

bilizing attachment of lower jaw to upper jaw. After splint fixation, intermaxillary fixation completes the positioning of the mandible.

BONE GRAFTS

Transplanted bone is required to replace the missing or defective mandible. We use autogenous rib or ilium, the choice depending on the length, bulk, and thickness of the required graft, and on the stresses to which it will be subjected. To replace missing mandibular arch segments is an exacting and time-consuming operation. Inventiveness and careful craftsmanship are required to produce the best results. Soft tissue around the graft must be well vascularized, and not under tension that may cause necrosis. Accurate construction of the abutments of graft and mandible is possible with careful planning and the use of appropriate instruments. High-speed air-driven and electric-powered tools permit accurate shaping, cutting, and drilling in a minimum amount of operative time.

POSTOPERATIVE CARE

Maintenance and immobilization. All patients who undergo secondary reconstruction of the mandible require immobilization and intermaxillary fixation. The wire ligatures and elastics used for this purpose loosen postoperatively; at intervals of from one week to two weeks these should be examined and tightened or, in the case of elastics, replaced. Care and cleaning of the splints, teeth, and soft tissues in the postoperative period are best done by use of a water-jet engine. The Water-Pik* is used in the hospital and also by the patient at home.

Bone grafts require immobilization for three months. After osteotomy and interosseous wiring, without the use of a bone graft, immobilization is maintained for two months.

Prosthetics and occlusal adjustment. After motion of the restored mandible is permitted, correction of upper- and lower-tooth relationships should be undertaken. Lack of teeth, especially the anterior dentition, causes defective speech and cosmetic deformity. Prosthetic replacement by full or partial dentures is important to the patient. The best results may depend on crowning of teeth and permanent bridgework to restore occlusion.

These secondary problems in prosthetics and bite relationships are difficult to resolve, and require the cooperation of plastic surgeon and dentist. In addition to a good functional result, cosmetic improvement, as mentioned, is an important goal. The combined experience, imagination, and technical skill in two specialties is required.

* Manufactured by Aqua Tec Corp., Fort Collins, Colorado.

SUMMARY

Secondary reconstruction of the lower jaw can correct posttraumatic problems of malunion, nonunion, and the open-bite deformity. Missing segments of the mandibular arch, postsurgical or posttraumatic, may be replaced with autogenous bone grafts. The preoperative planning must include construction of study models made from impressions of the patient's upper and lower dental arches. Restored mandibular position requires a period of postoperative intraoral immobilization, best achieved by prefabricated mouth splints and occlusal appliances. In addition to preoperative planning, when postoperative bite adjustment, tooth movement, and prosthetics are needed, the cooperation of a dentist is essential to the best results of secondary mandibular reconstruction.