

# Temporomandibular arthralgia

## DIAGNOSIS AND TREATMENT

SHATTUCK W. HARTWELL, JR., M.D.,

*Department of Plastic Surgery*

BURTON P. SIEGEL, D.D.S.,

*Dental Consultant, Cleveland, Ohio*

ROBIN ANDERSON, M.D.

*Department of Plastic Surgery*

**P**AIN in the jaw joint is a presenting symptom of many patients who consult the maxillofacial surgeon, the otologist, or the dentist. During the years 1963 through 1965 a total of 119 patients with this symptom were examined at the Cleveland Clinic, and were given the diagnosis of temporomandibular arthralgia. This report outlines the symptoms and the signs of temporomandibular arthralgia, the methods of evaluation, and the treatment.

## SYMPTOMS

Earache may be the patient's initial experience when temporomandibular arthralgia is the actual problem. The auriculotemporal branch from the third (mandibular) division of the trigeminal nerve contains sensory fibers from the temporomandibular joint, the external auditory canal, and the tympanic membrane. This common nerve and the proximity of the joint, the auditory canal, and the tympanic membrane account for discomfort in the temporomandibular joint often perceived as pain in the ear.

Clicking or snapping in temporomandibular joints occurs in some patients. The sound may be so loud that it carries across a quiet room. Clicking may be transient and painless. Lancinating pain in the temporomandibular joint may be associated with joint crepitus.

Pain in a joint generally is related to motion, and this is true of pain in the temporomandibular joint. Discomfort may occur on extreme opening of the mouth; while chewing food; with clenching of the jaw and grinding of teeth (bruxism); and with mandibular movement during talking. Temporomandibular pain is usually one-sided, but if bilateral it is worse on one side than on the other.

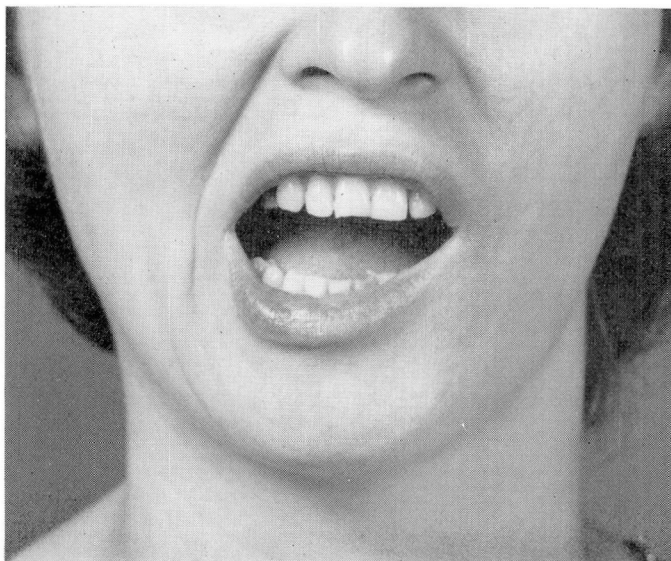## ONSET

The patient may remember clearly the time of onset. A fall or a blow on the jaw may be followed shortly by discomfort in the temporomandibular joint. Roentgenograms of the mandibular condyles should always be made to see whether or not a fracture is present. Symptoms may follow a yawn or a meal, and the patient may even recall what he was chewing when pain developed. Sometimes the patient is able to recall the year and the month when discomfort began, but he can remember no inciting incident.

## SIGNS

Examination of patients with pain in the temporomandibular joint nearly always will reveal tenderness over the joint capsule—the most common sign. The joint on the affected side is sore, and motion there is restricted by muscle splinting. The unaffected side allows its condyle to glide fully in the normal excursion of opening the jaw, but the splinted side is “tethered,” and this causes deviation of the chin to the affected side; hence the grimace when the patient opens the mouth widely (*Fig. 1*). Condylar motion is easily detected by palpation.

Crepitus within the joint may or may not be found. The crunching or snapping sensation beneath the examiner's fingers is caused by the grinding of the meniscus within the temporomandibular joint. The joint itself may be considered an upside-down mortar and pestle, where the fossa is the



**Fig. 1.** Photograph showing deviation of the jaw toward the painful mandibular joint. Note the grimace.

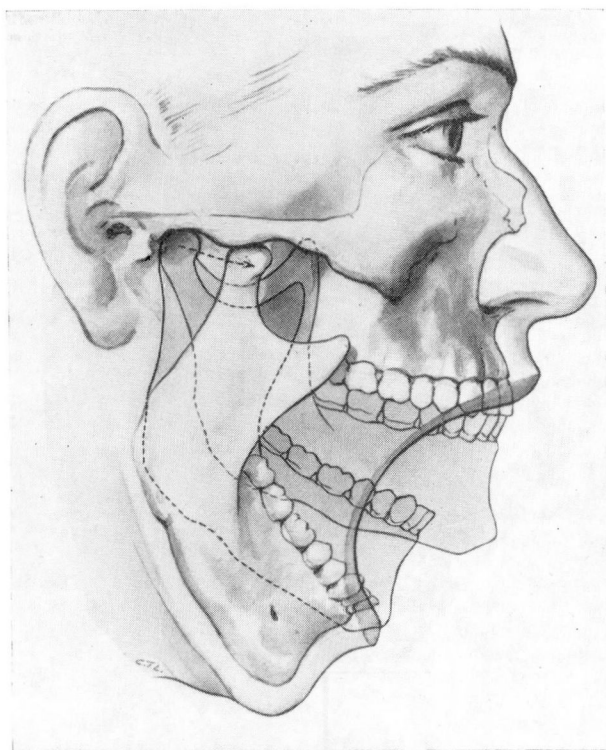


Fig. 2. Drawing of the ranges of condylar motion of the mandible. (Courtesy of the American Dental Association, plate 35, in Massler, M., and Schour, I.: *Atlas of the Mouth and Adjacent Parts in Health and Disease*, 1st ed. Chicago, Illinois: The Bureau of Public Relations Council on Dental Health, American Dental Association, 1946.)

mortar and the pestle is the mandibular condyle. Grinding of molar teeth is permitted by the motions of the condyle within the fossa. The condyle normally rides "down and out," over the edge of the eminence of the fossa for a variable distance (Fig. 2). In doing so, the meniscus is pushed and squeezed within the joint, like a doormat caught beneath a door. This is one illustration of a cause of joint crepitus.

A second cause of joint crepitus is irregularity in the surfaces of condyle and of fossa. Their grating motion may not be prevented by a meniscus if its cartilage is atrophic, torn, or worn away. Intracapsular changes such as this result from wear and tear over several years.

#### MALOCCLUSION

The qualified dentist understands occlusal relationships and is best prepared to analyze and to treat abnormal bite patterns, but the physician can recognize conditions where the teeth are likely causes of joint pain.

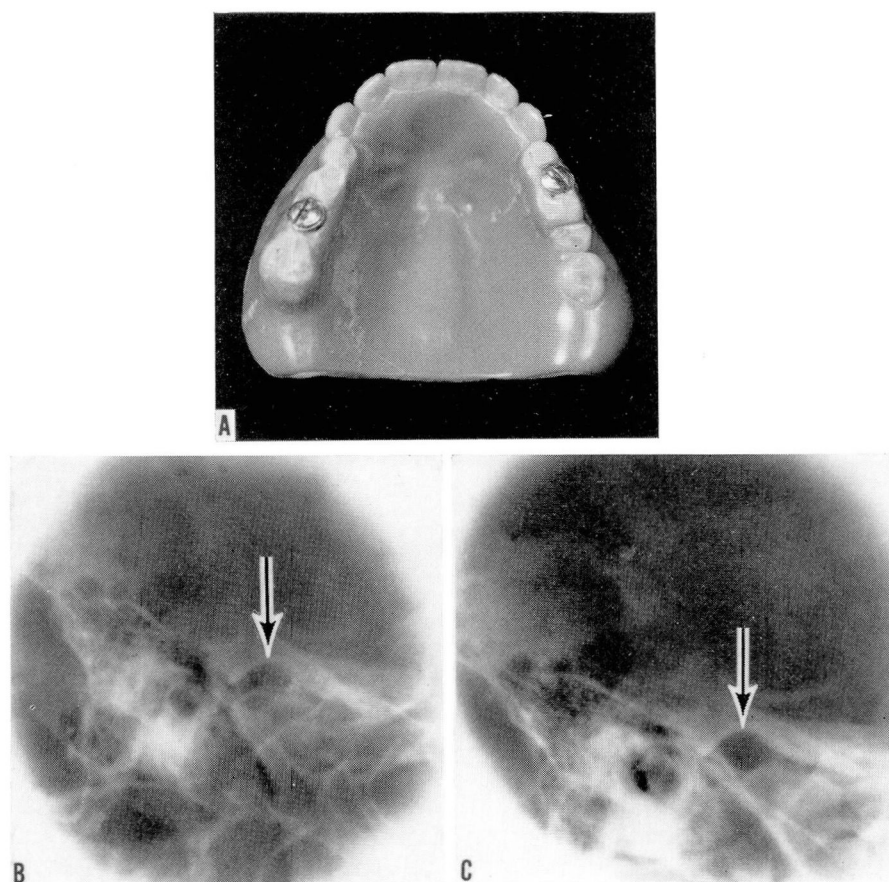


Fig. 3. A, Photograph of upper complete denture and appliance. Note screws that temporarily adjust occlusion against the lower denture. B, Roentgenogram of right temporomandibular joint. Jaws are closed without the denture. Arrow points to top of fossa. C, Roentgenogram of right temporomandibular joint. Jaws are closed. Dentures are in place. Note effective distraction of the joint by the denture appliance. Arrow points to top of fossa. (The prosthesis was constructed by T. S. Malson, D.D.S., Cleveland, Ohio.)

Most apparent is the imbalanced bite after loss of posterior teeth. Upper and lower teeth normally are opposed in the closed-bite position; without them there is increased pressure of the condyle in the fossa. Edentulous patients without proper prosthetic replacement have no teeth to act as "bite stops," and change of articular relations may be demonstrated with and without dentition (*Fig. 3*).

Less obvious to the physician are dental interferences with normal chewing. The sliding motions from side to side, and forward and backward are

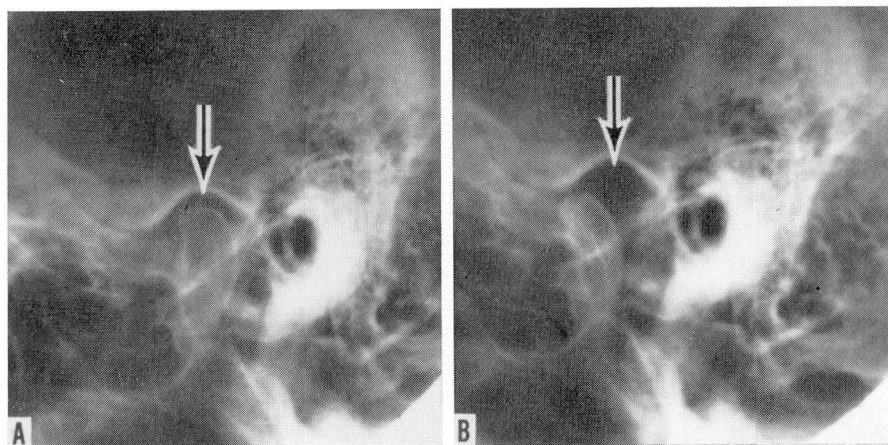
frustrated by dental cusps or abnormal position of teeth. Occlusal imbalance is the most common cause of temporomandibular arthralgia. The mechanical frustrations in the gliding of occlusal surfaces create spasm in the muscles of mastication, and motion and stress are unevenly distributed between the two temporomandibular joints.

## ANXIETY AND TEMPOROMANDIBULAR ARTHRALGIA

The development of pain is commonly associated with jaw-clenching habits and nocturnal teeth grinding, as muscular signs of anxiety. Levels and intensities of anxiety may contribute to facial discomfort and pain. Interviews with the patient may not disclose emotional tensions, but a carefully elicited history (sometimes completed after treatment is begun or progress examinations have been made) often reveals onset of pain in association with mental stress, and a female patient may tearfully relate due cause for her anxiety.

## RADIOGRAPHIC EVALUATION OF TEMPOROMANDIBULAR JOINT

Roentgenograms of the temporomandibular joint should be obtained in all cases of arthralgia in this region. Bilateral views are required even though symptoms are one-sided. Roentgen examinations of the mouth in open and in closed positions are made, and the following diagnostic information is readily obtained: condylar form and contour; the presence or absence of an adequate cartilaginous zone between the articular surfaces; and the extent of condylar motion. An example is shown in *Figure 4*.



**Fig. 4.** A, Roentgenogram of a normal temporomandibular joint, closed position. Arrow points to top of fossa. B, Roentgenogram of a normal temporomandibular joint, open position. Note difference in condylar position. Arrow points to top of fossa.

## TREATMENT OF CHRONIC TEMPOROMANDIBULAR ARTHRALGIA

Treatment may be of three types: medication, occlusal and mechanical correction, and, finally, arthroplasty.

Medication that is useful includes drugs that modify the psychic state, specifically the tranquilizers such as meprobamate and chlorthalidazine hydrochloride, or the antidepressant drugs such as diazepam. They are prescribed in conjunction with muscle relaxants such as methocarbamol. The muscle tensions either from anxiety or secondary to imbalanced stress between the temporomandibular joints contribute to pain and are treated specifically.

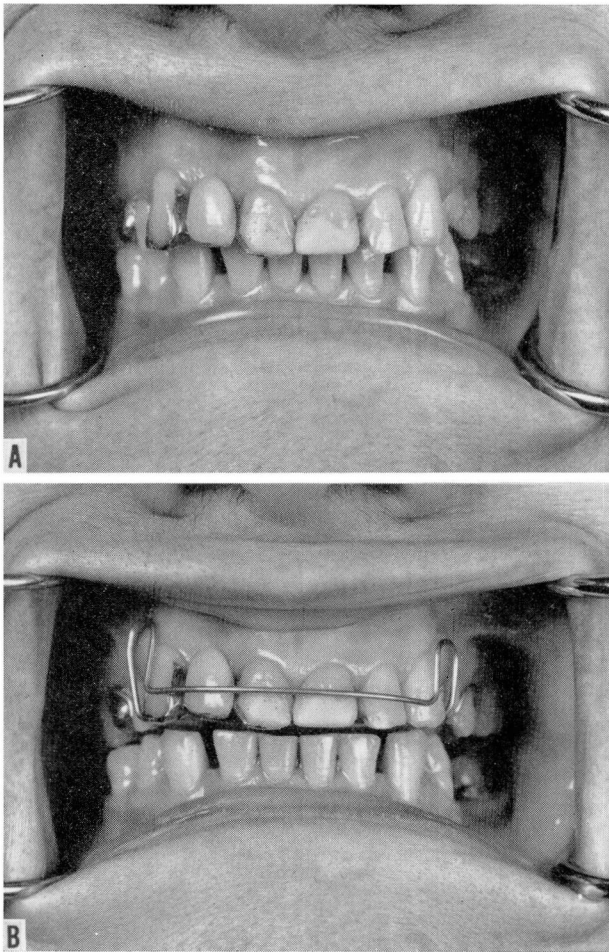
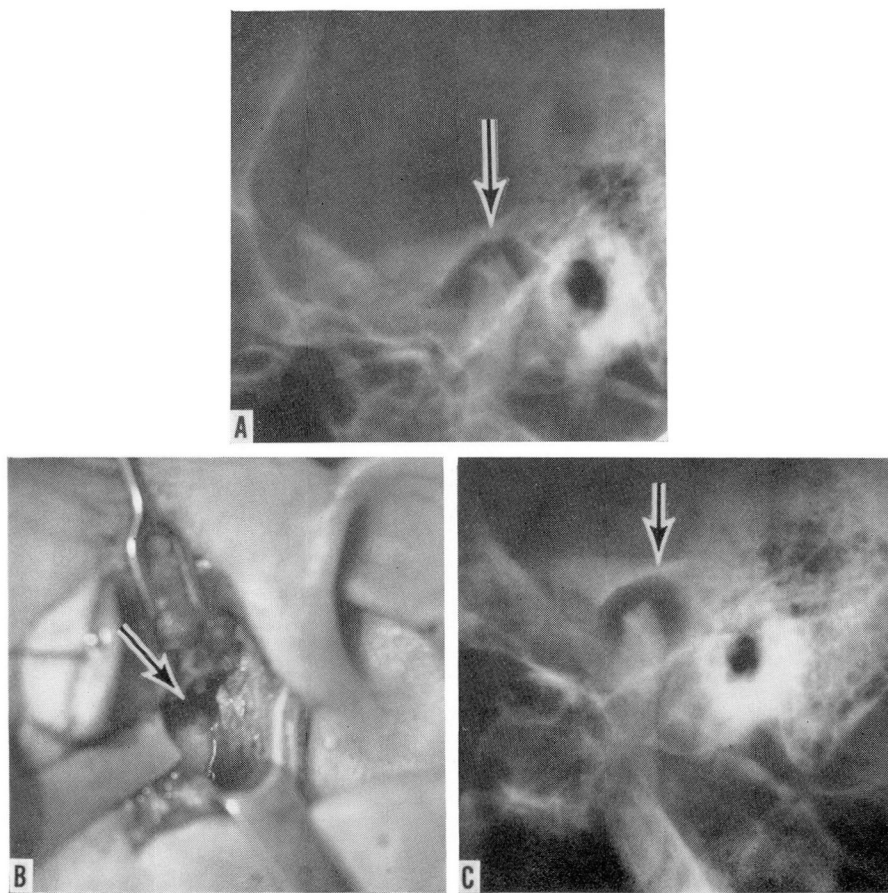


Fig. 5. A, Photograph of occlusion. B, Photograph of bite-plane appliance in place.

Occlusal and mechanical adjustments are managed by a qualified dentist. All patients with temporomandibular arthralgia seen in the Department of Plastic Surgery are examined both by a maxillofacial surgeon and by a dentist, and problems of occlusion and prosthetics are referred to dentists. In addition to bringing about improvement in occlusion, one of the most useful technics in the relief of temporomandibular arthralgia is the construction of a bite-plane appliance (*Fig. 5*). This device distracts the occlusal surfaces, permits mandibular gliding without interference from maxillary dentition, and hence relieves distressing forces in the tempo-



**Fig. 6.** A, Roentgenogram of right temporomandibular joint. Note irregular condylar contour. B, Photograph of the condyle at the time of operation. Note irregular surface on condyle. C, Postoperative roentgenogram of the same patient showing improved joint space and condylar profile.

mandibular joint. The patient generally wears such an appliance at night.

Arthrotomy is reserved for the patient who is not relieved by medication and occlusal balancing. The following standards in addition to the foregoing qualification are used to judge the need for operative treatment. Chronicity of the problem must be established, and the patient must have been symptomatic for at least six months. There should be radiographic evidence of changes in the joint; and at least one of the following conditions should be present: joint tenderness, crepitus, or restricted motion. These requirements justify an operation that improves the relationship of the condyle and the fossa. The operation used at the Cleveland Clinic Hospital is a condyloplasty with or without a dermal interposition graft<sup>1</sup> (*Fig. 6*). A high-speed air-driven bur is used to reshape the condyle to a smooth and rounded surface, and a free graft of dermis may be interposed between the condyle and the fossa. If the meniscus is intact, such a graft is not used.

After arthroplasty, the edentulous patient must be carefully fitted for dentures that approximate as closely as possible a good posterior bite relationship, and the patient who has teeth must be examined at intervals postoperatively by his referring dentist or a dental consultant in regard to occlusal adjustments that may be necessary.

#### DATA

Temporomandibular arthralgia was diagnosed in 119 patients at the Cleveland Clinic from 1963 through 1965. Of these, 91 patients (76 per cent) were women. Roentgenograms of the affected joints were made of 37 patients (31 per cent) of the entire group.

Of the 119 patients, 26 were examined in the Department of Plastic Surgery. Radiographic examination was made of the joints, and of the 26 patients only three were selected for temporomandibular arthroplasty. The progress of the three patients, all women, has been followed for more than two years, and all are symptom free.

#### SUMMARY

From 1963 through 1965, 119 patients received the diagnosis of temporomandibular arthralgia. The symptoms and clinical findings are discussed. Cooperation of dentist and surgeon is required in evaluation and treatment of the disorder. Selected therapeutic procedures are medications, mechanical balancing of the bite, and arthroplasty of the temporomandibular joint.

#### REFERENCE

1. Georgiade, N. G.: The surgical correction of temporomandibular joint dysfunction by means of autogenous dermal grafts. *Plast. & Reconstruct. Surg.* 30: 68-73, 1962.