

Intraoral 'leukoplakia'

SHATTUCK W. HARTWELL, JR., M.D.

Department of Plastic Surgery

LEUKOPLAKIA has become a convenient catchall term for many epithelial abnormalities within the mouth. According to Sprague¹ the term was first used by Schwimmer in 1887; it simply means "white patch." White patches are common in the mouth. Oral epithelium is constantly moist, and those abnormalities or portions of oral epithelium which are characterized by excess keratin will take on a white appearance because keratin characteristically turns white when it is thoroughly wet. As occurs with squamous epithelial surfaces elsewhere in the body, so too in healthy oral mucosa there is an orderly progression of epithelial cells toward the surface, and a continuing desquamation takes place without keratin accumulation.

If a painless, unobtrusive, or even unnoticed, white patch in the mouth had no more significance than a callus on a laborer's hands, then there would be no problem to discuss. There is real danger, though, in intraoral leukoplakia, since leukoplakia may be a premalignant condition or mask a lesion that is actually a carcinoma.

WHAT IS INTRAORAL LEUKOPLAKIA?

Leukoplakia is a term to be used strictly for a clinical diagnosis of a white mucosal patch. It has no precise histopathologic meaning; as a definitive diagnosis (after biopsy) it should be abandoned; and it should not be used to designate carcinoma.² Leukoplakia has been used to designate epithelial lesions in the mouth which are not white,³ and this has caused confusion. Lesions that are red and eroded in appearance should not be labeled leukoplakias.

Without keratin, intraoral epithelial lesions are not white, although intraepithelial edema may show grossly as a faint, hazy whiteness.⁴

WANTED: A GOOD BIOPSY

It is essential that biopsy provide a good specimen of sufficient depth and extent for cross-sectional detail of oral mucosa. Exfoliative cytologic specimens do not provide such detail for the assessment of intraoral leukoplakia, and have been shown to be inaccurate in mass screening for oral cancer.⁵ Therefore, in all instances of intraoral leukoplakias and epithelial abnormalities, biopsies should be performed in preference to exfoliative cytologic studies. Relatively superabundant keratin (hyperkeratosis), or imperfectly

formed keratin (parakeratosis), which appears white in a moist environment, forms only the outermost epithelial layer. Of greater diagnostic importance than the outermost layer are cells in the deeper epithelial layers.

ETIOLOGY AND EPIDEMIOLOGY

Leukoplakia in the mouth may be caused by mechanical irritation such as ill-fitting dentures, irregular teeth, and habitual cheek or tongue biting. Chemical irritation from tobacco smoke and snuff may also induce leukoplakia.

Lack of vitamin A has long been known to cause changes in the skin, including epithelial atrophy, hyperkeratosis, squamous hyperplasia, xeroderma, follicular hyperkeratosis, and xerophthalmia.⁶ There is no valid evidence that supplementary vitamin A will alter favorably intraoral leukoplakia. In the absence of mechanical or chemical causes of leukoplakia, it must be stated that we do not know the etiology.

Intraoral leukoplakia occurs twice as often in men as in women and is most prevalent in the fifth, sixth, and seventh decades of life.⁷

TYPES OF EPITHELIAL CHANGE

Figures 1 through 4 are different examples of epithelial irregularity, all of which can be classified clinically as leukoplakia. Good biopsies show the microscopic detail. The surgeon should advise the patient to have the leukoplakia removed only if there is histocytologic change that may portend

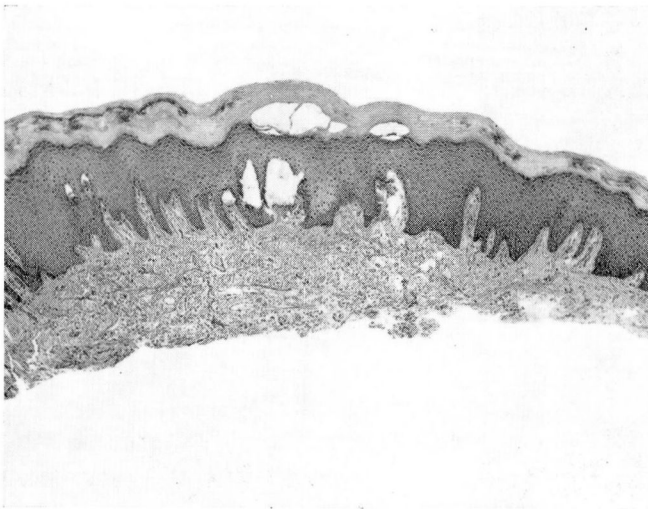


Fig. 1. Thick layer of keratotic epithelium (in response to an irritating denture). The underlying epithelium shows no unusual alteration except for some mild pseudoepitheliomatous hyperplasia. Hematoxylin-eosin stain; magnification $\times 35$.

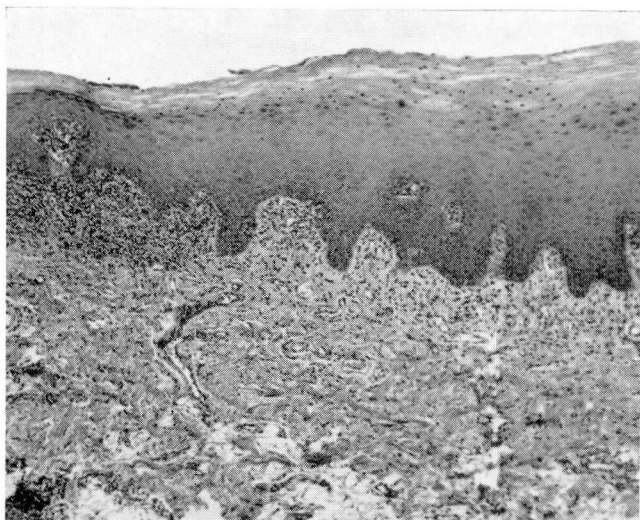


Fig. 2. An irregular thickening of the squamous epithelium with nuclear variation in size and staining property and also some irregularity in nuclear distribution. This is regarded as a mild dysplastic change in the epithelium. Hematoxylin-eosin stain; magnification $\times 65$.

malignancy. By these standards there is not enough histocytologic change in *Figures 1 and 3* to warrant total excision of the leukoplakia; these lesions should be observed at regular intervals for further changes. There are severe enough changes seen in *Figures 2 and 4* to warrant total excision of these areas of leukoplakia.

LEUKOPLAKIA AND ORAL CARCINOMA

Oral carcinoma and leukoplakia are two different lesions, but there is an association between the two.⁷⁻⁹ The exact nature of this relationship is not certain, but we must acknowledge it. For this reason some leukoplakias (*Fig. 2 and 4*) should be excised.

The significance of any leukoplakia *at the time when it is seen* must be established; it is not so much a question of what a leukoplakia will become. The following data will illustrate the problem. In 8 percent of the patients in one series,⁸ the so-called leukoplakia proved to be invasive cancer; in another series,⁷ 10 percent of the lesions were carcinoma in situ; and in another series⁹ the gross leukoplakias in 30 percent of the patients were microscopically dyskeratoses regarded as premalignant.

The problem then, has two parts: namely, (a) what leukoplakias are in reality a mask for existing carcinoma? and (b) what leukoplakias will become carcinoma? The answer to the first part is easier, because histocytologic study here and now can give an answer. The second part is more difficult.

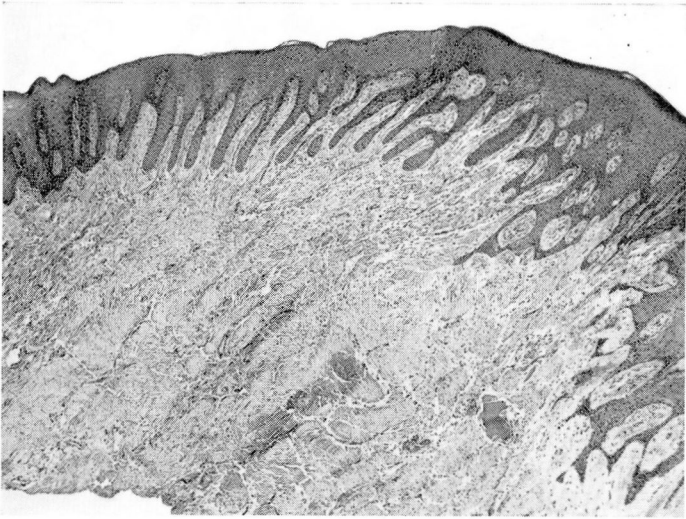


Fig. 3. Severe pseudoepitheliomatous hyperplasia. Epithelium, however, reveals no alarming histocytologic change. Hematoxylin-eosin stain; magnification $\times 35$.

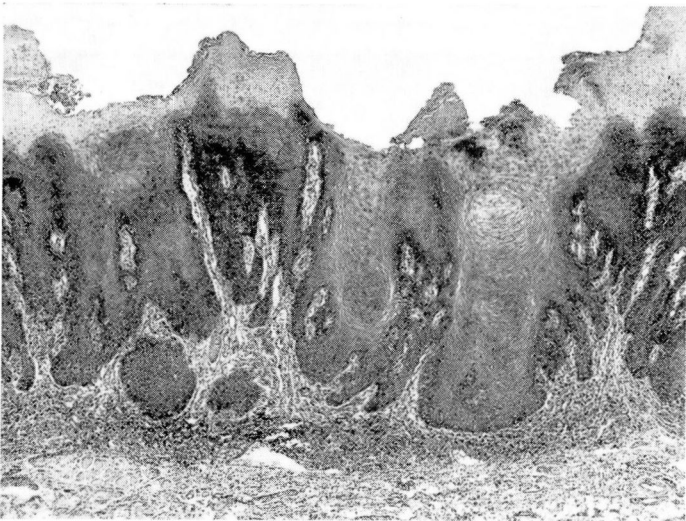


Fig. 4. Great variation in thickness of epithelium with a verrucous surface configuration; distinct pseudoepitheliomatous hyperplasia that at this magnification cannot definitely be distinguished from superficial well-differentiated carcinoma. Histologic study did not reveal invasive carcinoma in this area. Hematoxylin-eosin stain; magnification $\times 35$.

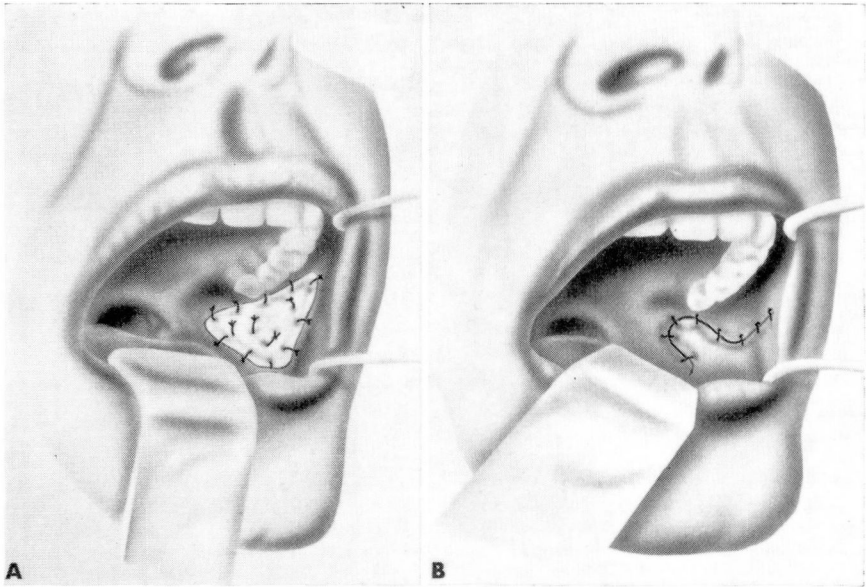


Fig. 5. Drawings that illustrate the reconstruction of intraoral buccal defects: A, Split thickness skin graft. B, Transposition flap of mucosa. In each instance, coverage will reduce the scar in this region which may restrict the opening of the jaws.

A careful statistical study and years of collected observations and biopsies will be necessary; at present we have no definite answer.

TREATMENT

Biopsy may be all that is necessary; the pathologist may reassure the clinician that the epithelium is not seriously disordered. The patient is entrusted to follow-up observations. When the intraoral lesion is extensive and histopathologically atypical (*Fig. 2 and 4*), the patient is admitted to the hospital. Treatment is made convenient by the assistance of operating room personnel and equipment, and the hospital care is reassuring to the patient, as even insignificant postoperative bleeding may frighten him.

With the patient under local or general anesthesia, the affected mucosa is removed. Should it be necessary to remove several square centimeters of mucosa, it is preferable to excise only part at one time. After the first excision, the patient is discharged from the hospital, then is readmitted at intervals of three or four months for the other excisions until all of the leukoplakia has been removed. Three or four stages may be required. This plan of treatment is called serial stripping or staged multiple excisions. Representative sections of all tissue removed are examined microscopically.

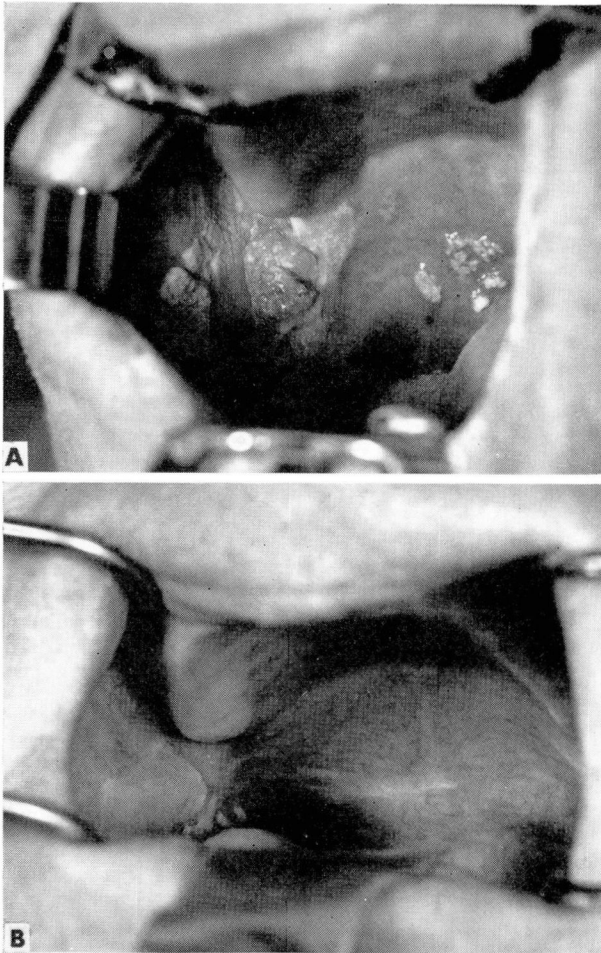


Fig. 6. A, Severe leukoplakia is seen in several locations. Serial stripping in three stages cleared all areas of severe dysplastic epithelium. B, Carcinoma in situ was noted histologically in some places.

The postoperative defects are not surgically closed unless they are small. A skin graft or a pedicled mucosal flap may be useful when it is feared that cheek or jaw movement will be severely restricted by scarring (*Fig. 5, A and B*). Staged excisions will generally avoid the necessity for such treatment (*Fig. 6, A and B*). Moreover, multiple staged excisions eliminate the need for the complicated intraoral appliances that have been used for stents.¹⁰ In removing intraoral mucosa it may also be necessary to remove the openings of the salivary ducts. When they lie in the region of disease they are included

in the resection. Cannulation, dissection, or reimplantation of the transected ducts is not always necessary.

An important part of treatment are the progress examinations of the patients; if they are smokers, they must be advised to give up smoking. It is true that some patients may use tobacco without apparent injury to their oral mucosa; but it must be stressed that the heavy smoker with keratosis or erosions in his oral epithelium is subjecting his mouth to a constant abuse.

Electrodesiccation or fulguration is useful in the treatment of intraoral leukoplakia but should only be done after biopsy. Full-thickness epithelial destruction must be achieved because uneradicted atypical epithelial elements will simply persist and bring about recurrence of the same problem. Further epithelial changes may tend toward invasive malignancy. Application of radium packs¹¹ to treat intraoral erosions or keratoses is to be condemned. Excisional treatment removes all epithelial elements, and healing must necessarily take place from the contribution of adjacent and more normal tissue.

SUMMARY AND CONCLUSIONS

Leukoplakia has become a confusing and inadequate word, often misapplied to intraoral epithelial lesions that are not white. It is recommended that it only be used for the clinical designation of a white patch on the oral mucosa. Preferably the term keratosis should be used instead of leukoplakia.

In all persistent leukoplakias (keratoses) or erosions, biopsy should be made to provide a definitive assessment of the epithelial alteration, especially to establish the presence or absence of carcinoma. When the biopsy specimen reveals epithelial dysplasia, complete removal of the lesion is advised. Extensive excisions are best done in stages. In the absence of atypism of the epithelium, definitive surgical treatment is not applied.

REFERENCES

1. Sprague, W. G.: A survey of the use of the term "leukoplakia" by oral pathologists. *Oral Surg.* 16: 1067-1074, 1963.
2. Smith, J. F.: Oral leukoplakia: a study of 420 tissue sections. *J. Tennessee M. A.* 56: 360-366, 1963.
3. King, O. H., Jr.: Intraoral leukoplakia? *Cancer* 17: 131-136, 1964.
4. Sandstead, H. R., and Lowe, J. W.: Leukoedema and keratosis in relation to leukoplakia of buccal mucosa in man. *J. Nat. Cancer Inst.* 14: 423-437, 1953.
5. Selbach, G. J., and Von Haam, E.: The clinical value of oral cytology. *Acta Cytol.* 7: 337-345, 1963.
6. Pinkerton, H.: Chap. 17, Vitamins and Deficiency Diseases, p. 401-416, in Anderson, W. A. D.: *Pathology*, 3d ed. St. Louis: The C. V. Mosby Company, 1957, 1402 p.
7. Shklar, G.: The precancerous oral lesion. *Oral Surg.* 20: 58-70, 1965.

8. Shafer, W. G., and Waldron, C. A.: A clinical and histopathologic study of oral leukoplakia. *Surg. Gynec. & Obst.* **112**: 411-420, 1961.
9. Cooke, B. E. D.: Leukoplakia buccalis. *Ann. Roy. Coll. Surgeons* **34**: 370-383, 1964.
10. Pilbeam, J. F., and Cohen, B.: Surgical treatment of leukoplakia of the palate. *J. Laryng. & Otol.* **79**: 225-232, 1965.
11. Breed, J. E.: Oral leukoplakia. *Illinois M. J.* **124**: 330-331, 1963.