

Hurler's disease—an illustrative case report

KENNETH S. K. TUNG, M.B., B.S.,*

Division of Pathology

GEORGE C. HOFFMAN, M.B., B.Chir., M.C.Path.,

Department of Clinical Pathology

ROBERT D. MERCER, M.D.

Department of Pediatrics

HURLER'S disease is the most common and also the most severe form of the mucopolysaccharidoses, a group of inherited diseases characterized by abnormalities in acid mucopolysaccharide (AMP) metabolism. The metabolic fault causes an excess of one or more types of AMP to appear in the serum,¹ the urine,² and tissues.³ A comprehensive classification of the mucopolysaccharidoses, based on clinical, genetic, and biochemical characteristics, has emerged as a result of the studies by McKusick and his associates (*Table I*).⁴

This paper concerns a clinicopathologic study of a patient with Hurler's disease. Emphasis is placed on those studies that were most helpful in diagnosis and in revealing the underlying biochemical abnormality.

REPORT OF A CASE

A 10-month-old Caucasian girl was first examined at the Cleveland Clinic Hospital on May 15, 1966, because of a hump on the back. She was the only child of healthy parents. No known consanguinity existed between the parents. Pregnancy and delivery had been normal and at birth the patient weighed 8 pounds 6 ounces and was 20 inches long. At 8½ months she sat unassisted, and at 10 months she stood with support. On physical examination, the patient had the characteristic appearance of Hurler's disease: thick dark eyebrows joined in the midline, eyelashes exceptionally long and dense, definite corneal clouding, flatness of the nose exaggerated by unusually prominent supraorbital ridges, thick lips, a large tongue, and no teeth. The upper and lower extremities were short and plump; the hands were clawed, with broad palms, and short stubby fingers; a large gibbus was present in the lumbosacral region of the back. A loud pansystolic murmur was audible at the base of the heart. The spleen and liver extended for 3 cm below the costal margin. An evaluation of the patient's age, according to the Cattell infant intelligence scale, gave a chronologic age of 11 months, a mental age of 8.8 months, and an intelligence quotient of 80. Roentgenograms revealed lumbosacral kyphosis, anterior hooklike projections (*Fig. 1*) of the upper lumbar vertebral bodies, small iliac components of the pelvis with shallow acetabula, and widening of the central medullary canals of the metacarpal, and the proximal and the middle phalangeal bones (*Fig. 2*). Laboratory investigation revealed the following: blood hemoglobin content, 13.4 gm per 100 ml; hematocrit reading, 40 percent; leukocyte count, 13,000 per cubic millimeter, with 34 percent neutrophils, 60 percent lymphocytes, 2 percent

* Fellow, Division of Pathology.

Table 1.—*The genetic mucopolysaccharidoses**

MPS	Clinical	Genetic	Biochemical
I (Hurler syndrome)	Early clouding of cornea, grave manifestations	Autosomal recessive	Ch S-B Heparitin S
II (Hunter syndrome)	No clouding of cornea, milder course	X-linked recessive	Ch S-B Heparitin S
III (Sanfilippo syndrome)	Mild somatic, severe CNS effects	Autosomal recessive	Heparitin S
IV (Morquio syndrome)	Severe bone changes of distinctive types, cloudy cornea, intellect +/-, aortic regurgitation	Autosomal recessive	Keratosulfate
V (Scheie syndrome)	Stiff joints, coarse facies, cloudy cornea, intellect +/-, aortic regurgitation	Autosomal recessive	Chondroitin sulfate B

* (Courtesy of McKusick, V. A.; Kaplan, D.; Wise, D.; Hanley, W. B.; Suddarth, S. B.; Sevick, M. E., and Maumane, A. E.: The genetic mucopolysaccharidoses. *Medicine* **44**: 445-483, Nov. 1965; and of *Medicine*.)

eosinophils, and 4 percent monocytes. No basophil was found among 200 leukocytes. The total serum protein content was 6.6 gm per 100 ml, with 400 mg per 100 ml of γ -globulin.

The patient was discharged from the hospital on May 18, 1966, but was readmitted two days later after an acute generalized convulsion. The rectal temperature was 103 F; blood pressure was 210/94 mm Hg; and the pulse rate was 168. A culture of pus escaping through a small perforation in the right ear drum yielded *Pseudomonas pyocyanea*. The cerebrospinal fluid was sterile. The blood hemoglobin content was 11.7 gm per 100 ml, and the hematocrit reading was 36 percent. The leukocyte count was 16,200 per cubic millimeter, with 81 percent neutrophils, 15 percent lymphocytes, and 4 percent monocytes. Treatment with penicillin and sulfisoxazole resulted in a drop in temperature to 99 F within three days. On the tenth day after admission to the hospital, the patient's temperature rose to 103 F, and a right myringotomy was performed. Chloramphenicol and colistin were added to her treatment and the temperature again subsided to 99 F. On the sixteenth day, the patient became irritable, her temperature rose to 104 F, and *Diplococcus pneumoniae* was grown from specimens of blood and of cerebrospinal fluid. Intravenous injections of penicillin were administered. The patient responded promptly, and fever subsided in two days. She was maintained on orally administered penicillin, and when she was discharged from the hospital on June 29, 1966, 40 days after admission, there were no abnormal signs referable to the central nervous system.

SPECIAL STUDIES

Urine. A random urine sample was studied for the presence of AMP. The specimen was concentrated by pervaporation in a cellophane bag as described by Faulkner, Gardner, and Lewis.⁵ A portion of this specimen was incubated with an equal volume of a 1 percent hyaluronidase solution at 37 C for one hour and then subjected to microzone electrophoresis on cellulose acetate with a barbital buffer at pH 8.6 and ionic strength of 0.075.* A band that stained metachromatically with 1 percent Alcian blue in 0.01 N

* Miss Milicent Gardner, B.S., M.T. (ASCP), performed the urine electrophoresis.

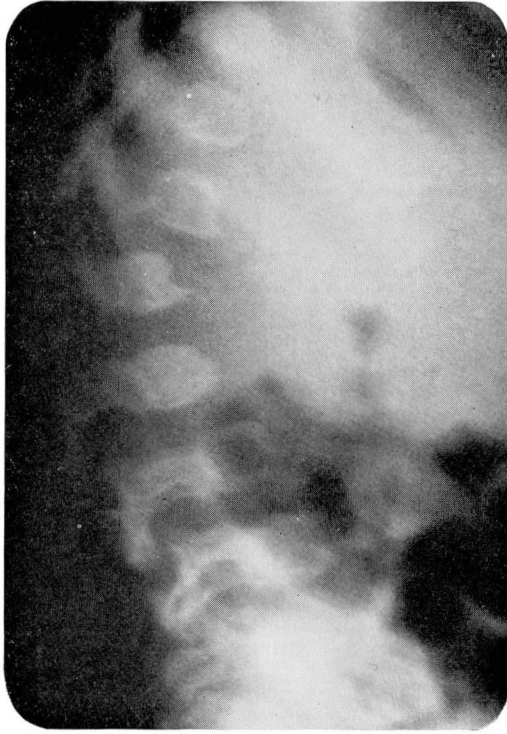

Fig. 1. Roentgenogram, lateral view of the thoracolumbar vertebra. Note anterior hooklike projection on the second lumbar vertebral body.

hydrochloric acid was demonstrated (*Fig. 3*). Chondroitin sulfate A, B, and C all exhibit this electrophoretic mobility. However, the band obtained from the patient's urine must be chondroitin sulfate B since this is the only type that resists hydrolysis by hyaluronidase. The patient's urine was not tested for heparitin sulfate (another AMP that is excreted by patients with Hurler's disease).

Blood and bone marrow. Bone marrow aspirates and peripheral blood smears were stained with Wright's stain and by the toluidine blue method of Mittwoch.⁶ When Wright's stain was used, discrete metachromatic granules were found in the cytoplasm of occasional histiocytes in the marrow aspirate (*Fig. 4*). These granules contrasted sharply with the red granules present in normal histiocytes. Peripheral blood stained with toluidine blue revealed similar metachromatic granules in 20 percent of lymphocytes and monocytes (*Fig. 5*). Typical inclusions described by Reilly⁷ as "toxic granulation-like metachromatic cytoplasmic granules in the neutrophils" were noted in occasional neutrophils, and were only seen when toluidine blue stain was used.

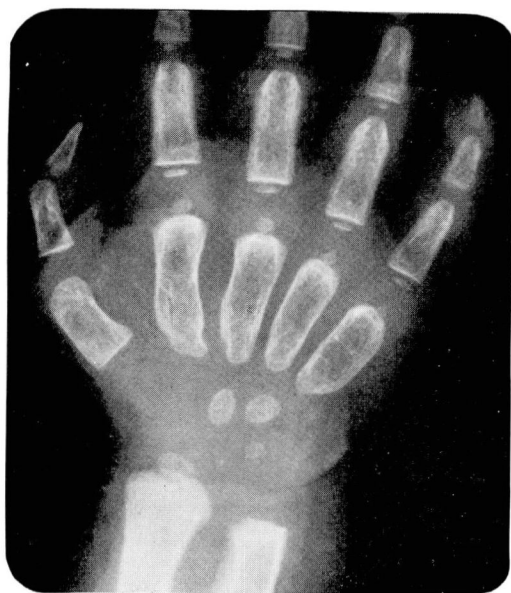

Fig. 2. Roentgenogram of the right hand. There are widening of the medullary cavity and deformity of the metacarpus and the proximal phalanges.

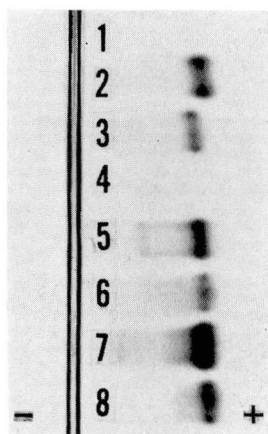


Fig. 3. Electrophoretic patterns of various urine specimens and reference solutions: 1. Urine from a normal 18-month-old girl. 2. Heparin sulfate solution. 3. Chondroitin sulfate A and C solution. 4. Chondroitin sulfate A and C treated with hyaluronidase. 5. Urine from a patient known to have Hurler's disease. 6. Urine (treated with hyaluronidase) from a patient known to have Hurler's disease. 7. Urine from the patient we studied. 8. Urine (treated with hyaluronidase) from the patient we studied.

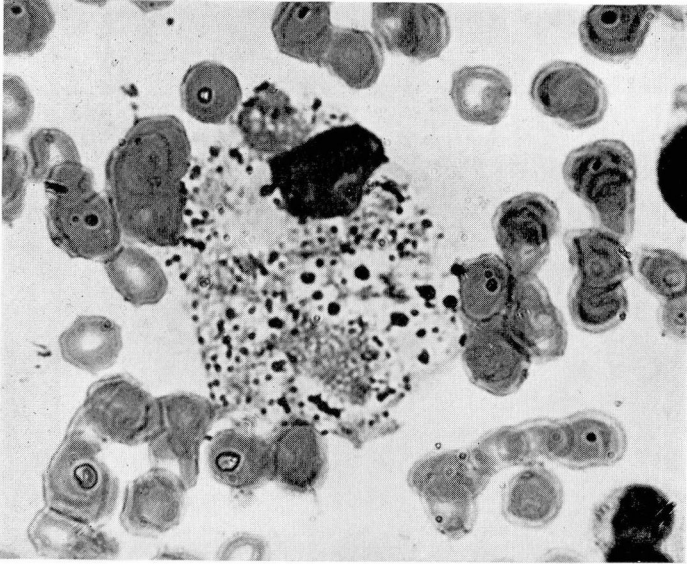


Fig. 4. Photomicrograph of the bone marrow aspirate, showing a histiocyte containing numerous (metachromatic) granules. Wright's stain; magnification $\times 1280$.

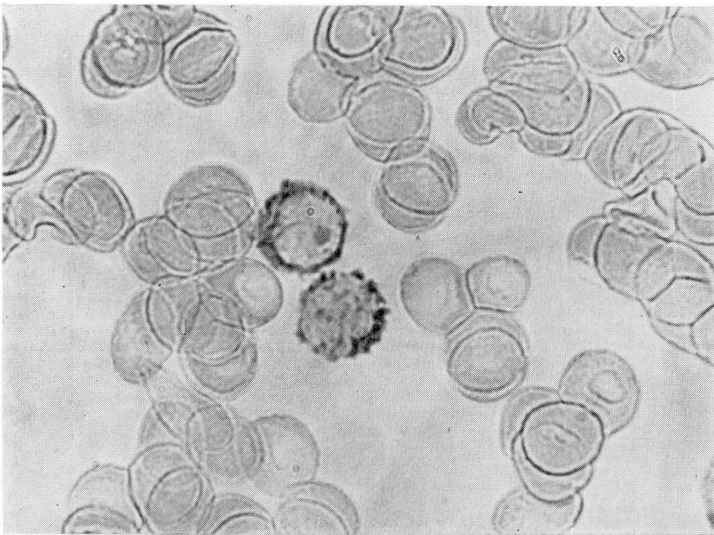


Fig. 5. Photomicrograph of a peripheral blood smear. Note the numerous (metachromatic) granules in the cytoplasm of two lymphocytes. Toluidine blue stain; magnification $\times 1280$.

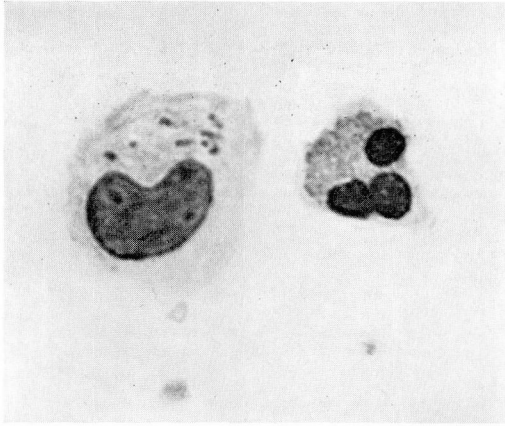

Fig. 6. Photomicrograph of cells representative of the third-hour cellular exudate from the skin window. Note the small cytoplasmic (metachromatic) granules. Wright's stain; magnification $\times 1280$.

Inflammatory cycle. The cellular components of the acute inflammatory response were studied qualitatively and semiquantitatively by the skin-window test of Re buck and Crowley.⁸ A shallow ulcer is made in the skin with a scalpel blade; a minute drop of diphtheria toxoid is placed in the ulcer; and a sterile coverslip is strapped over it. The cells migrate onto the coverslip and are harvested by replacing the coverslip at regular intervals. The normal sequence of events that occurs in children⁹ is as follows. Neutrophils appear within two or three hours and then increase in number for the next four to six hours. Mononuclear cells that morphologically resemble either lymphocytes or hematogenous monocytes appear after eight hours. During the next 12 hours, as the absolute number of the mononuclear cells increases, the neutrophils become pyknotic and gradually decrease in number. At this stage, phagocytosis of the neutrophils by the mononuclear cells may be observed. By the twenty-fourth hour, mononuclear cells predominate. For a brief period around the thirty-sixth hour, neutrophils again migrate in large numbers. Thereafter, the mononuclear cells dominate the pattern until the appearance of fibroblasts, fibrin particles, and epithelial cells indicate the onset of repair.

The results of the skin-window study on the patient differed from normal in several respects. The most striking abnormality was the presence of several types of metachromatic granules in the cytoplasm of the mononuclear cells. These granules appeared as a fine dust in occasional mononuclear cells as early as the third hour (*Fig. 6*). In some cells the granules appeared to be contained in vacuoles. During the next five hours, there was an increase in the number of cells that contained granules, in the

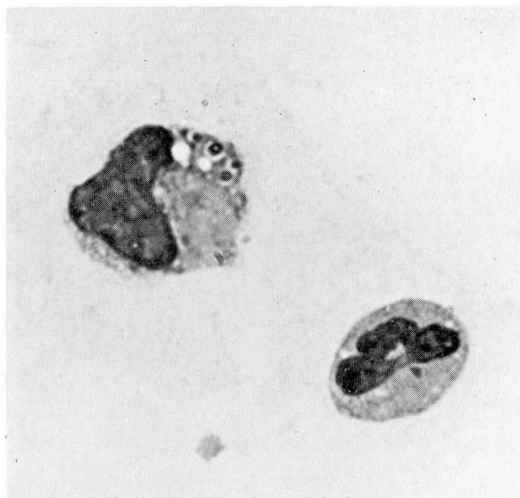


Fig. 7. Photomicrograph of cells from the skin window at the eighth hour. Note the bizarre ring forms of the (metachromatic) granules in the cytoplasmic vacuoles. Wright's stain; magnification $\times 1280$.

number of granules in such cells, and in the size of the individual granules. By eight hours, all the mononuclear cells and a few of the neutrophils were filled with granules of bizarre shapes and sizes (*Fig. 7 and 8*). These granules stained metachromatically with toluidine blue and Wright's stain, were periodic acid—Schiff positive, resisted digestion by diastase, and were Sudan-black negative.

Another abnormal result of the skin-window test was the diminished cellular response in the first study, performed when the patient was free of infection; however during the pneumococcal infection, when the absolute circulating neutrophil count increased from 4,500 to 13,000 per cubic millimeter, the pattern approached that of normal. A third abnormality was the increase in the number of basophils in the exudate, particularly in the forty-fifth hour period.

DISCUSSION

The diagnosis of Hurler's disease often can be made solely on clinical evidence. In the patient we studied, the corneal opacity and typical skeletal and facial abnormalities left little doubt as to the diagnosis. The laboratory studies confirmed the diagnosis by demonstrating some of the hematologic and biochemical abnormalities that result from the underlying defects in AMP metabolism.

The urine of normal children may contain small amounts of chondroitin sulfate A and C, but chondroitin sulfate B is not present. The presence of

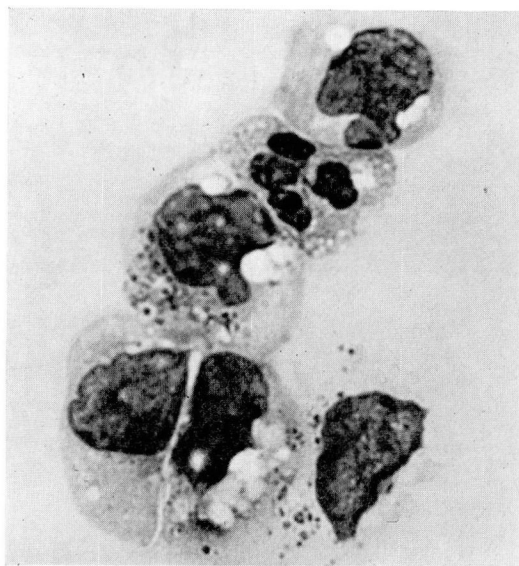

Fig. 8. Photomicrograph of cells representative of the eighth-hour cellular exudate obtained from the skin window. Note the numerous cytoplasmic (metachromatic) granules, both free in the cytoplasm and within cytoplasmic vacuoles with external limiting membranes. Wright's stain; magnification $\times 1280$.

chondroitin sulfate B in the urine of the patient we studied gave support to the diagnosis of Hurler's disease. However, chondroitin sulfate B is also excreted in other types of mucopolysaccharidoses (*Table 1*⁴), so this finding is not pathognomonic of Hurler's disease.

The metachromatic granules found in the neutrophils of patients with Hurler's disease were described by Reilly.⁷ Subsequent studies^{4, 8, 10-12} showed that only a few granule-containing neutrophils might be present, and only in a few patients. Similar granules may be seen in the histiocytes and plasma cells of bone marrow. Recently, these granules have been reported⁴ to be consistently demonstrated by the modified toluidine blue staining method of Mittwoch.⁶ The presence of metachromatic granules cannot be considered diagnostic of Hurler's disease since similar granules are present in patients with other types of mucopolysaccharidoses,⁴ as well as in patients with metachromatic leukodystrophy.¹³

Carlisle and Good,¹⁴ and later Rebeck and associates,¹⁵ noted intracytoplasmic granules in the mononuclear cells of the inflammatory exudates of patients with Hurler's disease. The granules consist of AMP, probably chondroitin sulfate B. In the patient we studied the granules seen in the mononuclear cells that appeared early in the inflammatory cycle, morphologically resembled those in the peripheral lymphocytes (*Fig. 6*). The gran-

ules seen in cells that migrated later appeared to be surrounded by limiting membranes (*Fig. 7 and 8*), suggesting that they were phagocytosed granules. In patients with Hurler's disease, chondroitin sulfate B has been demonstrated¹⁶ in the epidermal cells and dermal fibroblasts and they may be the source of these granules. The simplicity of the skin-window technic and the unequivocal results make it a useful screening test for Hurler's disease. Patients with the Scheie or the Sanfilippo syndromes produce results of skin-window tests similar to those of patients who have Hurler's disease. However they seldom present a diagnostic problem because their clinical features are so distinct. Morquio's syndrome is not so easily distinguished from Hurler's disease.⁴ We recently observed that the exudate appearing in the skin-window made on a patient with Morquio's syndrome contained no metachromatic granules. The skin-window test may prove to be useful in distinguishing these two disorders.

The development of pneumococcal meningitis in the patient we studied is of interest, since infection is a common and often fatal complication of the disease. The defective cellular components of the acute inflammatory response observed during the patient's first period in the hospital suggest a possible predisposing factor for this complication. However, our study also showed that once infection developed, both leukocytosis and a normal cellular inflammatory response followed.

Although the causes of mucopolysaccharidoses are not known, recent investigations suggest that an inborn error of AMP metabolism exists and that the subgroups of the mucopolysaccharidoses represent genetic variants of this basic defect.¹⁷ Matalon and Dorfman¹⁸ showed that fibroblasts from patients with Hurler's disease produced five times the quantity of AMP *in vitro* as compared with cells from a normal child. They further showed that the AMP produced by these cells possessed an abnormally low amino acid content. It has been suggested¹⁹ that a defect exists in the protein moieties that normally combine with the tissue AMP. This defect might result in the accumulation of free AMP that is excreted in the urine or taken up by circulating macrophages.

SUMMARY

A patient exhibiting the typical clinical and laboratory features of Hurler's disease is described. Urinary excretion of chondroitin sulfate B was demonstrated by paper electrophoresis. Metachromatic granules were present in the leukocytes and in the bone marrow histiocytes, but were most easily demonstrated in the inflammatory exudate in a skin window. This latter technic is a useful screening test for Hurler's disease and helps to distinguish it from Morquio's syndrome. The skin window also disclosed

a reduced inflammatory response, which may in part account for the susceptibility to bacterial infection, in patients with Hurler's disease.

REFERENCES

1. Sanfilippo, S. J., and Good, R. A.: A laboratory study of the Hurler syndrome. (Abs.) *Tr. Am. Pediatric Soc. Am. J. Dis. Child.* **102**: 766, 1961.
2. Dorfman, A., and Lorincz, A. E.: Occurrence of urinary acid mucopolysaccharides in the Hurler syndrome. *Proc. Nat. Acad. Sc.* **43**: 443-446, 1957.
3. Brante, G.: Gargoylism—a mucopolysaccharidosis. *Scandinav. J. Clin. & Lab. Invest.* **4**: 43-46, 1952.
4. McKusick, V. A., and others: The genetic mucopolysaccharidoses. *Medicine* **44**: 445-483, 1965.
5. Faulkner, W. R.; Gardner, M., and Lewis, L. A.: The concentration of low-protein body fluids. (Abs.) *Clin. Chem.* **8**: 424, 1962.
6. Mittwoch, U.: Inclusions of mucopolysaccharide in the lymphocytes of patients with gargoylism. *Nature*: **191**: 1315-1316, 1961.
7. Reilly, W. A.: The granules in the leukocytes in gargoylism. *Am. J. Dis. Child.* **62**: 489-491, 1941.
8. Rebuck, J. W., and Crowley, J. H.: A method of studying leukocytic functions in vivo. *Ann. New York Acad. Sc.* **59**: 757-805, 1955.
9. Eitzman, D. V., and Smith, R. T.: The nonspecific inflammatory cycle in the neonatal infant. *A.M.A. J. Dis. Child.* **97**: 326-334, 1959.
10. Pearson, H. A., and Lorincz, A. E.: A characteristic bone marrow finding in the Hurler syndrome. *Pediatrics* **34**: 280-282, 1964.
11. Griffiths, S. B., and Findlay, M.: Gargoylism: clinical radiological and haematological features in two siblings. *Arch. Dis. Child.* **33**: 229-234, 1958.
12. Muir, H.; Mittwoch, U., and Bitter, T.: The diagnostic value of isolated urinary mucopolysaccharides and of lymphocyte inclusions in gargoylism. *Arch. Dis. Child.* **38**: 358-363, 1963.
13. Strouth, J. C.; Zeman, W., and Merritt, A. D.: Leukocyte abnormalities in familial amaurotic idiocy. *New England J. Med.* **294**: 36-38, 1966.
14. Carlisle, J. W., and Good, R. A.: The inflammatory cycle; a method of study in Hurler's disease. *A.M.A. J. Dis. Child.* **99**: 193-197, 1960.
15. Rebuck, J. W., and others: Basophilic granulocytes in inflammatory tissues of man. *Ann. New York Acad. Sc.* **103**: 409-426, 1963.
16. Hambrick, G. W., Jr., and Scheie, H. G.: Studies of the skin in Hurler's syndrome: mucopolysaccharidosis. *Arch. Dermat.* **85**: 455-471, 1962.
17. Leroy, J. G., and Crocker, A. C.: Clinical definition of the Hurler-Hunter phenotypes. *Am. J. Dis. Child.* **112**: 518-530, 1966.
18. Matalon, R., and Dorfman, A.: Hurler's syndrome: biosynthesis of acid mucopolysaccharides in tissue culture. *Proc. Nat. Acad. Sc.* **56**: 1310-1316, 1966.
19. Hall, V. E.; Giese, A. C., and Sonnenschein, R. R. (editors): *Annual Review of Physiology*, vol. **28**. Palo Alto, California: Annual Reviews, Inc., 1966, 571 p.; p. 145.