

IMPLANTATION OF YTTRIUM⁹⁰ IN AN ACROMEGALIC PATIENT

REPORT OF A CASE

J. JACQUES GÉLINAS, M.D.,* E. PERRY McCULLAGH, M.D.,†

Department of Endocrinology

AND

DONALD F. DOHN, M.D.

Department of Neurologic Surgery

IMPLANTATION of radioactive substances in the pituitary gland has been used in an attempt to obtain more successful hypophysectomy than can be achieved with conventional X-ray treatment or cobalt⁶⁰ teletherapy. The morbidity and mortality associated with other surgical methods are avoided.¹⁻⁸ Heavy-particle irradiation has given promising results but is available in only a few medical centers.⁹ Yttrium⁹⁰ (Y⁹⁰) has been used, at the Cleveland Clinic, for pituitary ablation in metastatic breast cancer, in selected cases of diabetic retinopathy, in a few patients with Cushing's syndrome, and in 20 patients with acromegaly to be reported with additional cases more extensively later. This report concerns a patient with acromegaly who underwent this form of treatment and in whom growth-hormone assays were made before and after the operation. It is hoped that growth-hormone assays will help in the evaluation of therapeutic results.

METHODS OF STUDY

Transnasal implantation of two sources of yttrium⁹⁰ (5 mc. and 5.12 mc.) was performed according to the method of Forrest, Blair, and Valentine.¹ In this method plastic capsules containing the radioactive material are held in stainless steel screws, which are screwed into burr holes in the floor of the sella turcica after insertion through the nostrils and the sphenoid sinus.

Blood glucose was determined by means of the AutoAnalyzer ferricyanide method.¹⁰ The glucose tolerance tests were done with 100 gm. of glucose orally, and venous blood sugar was measured at one and at two hours.

The growth-hormone assays were performed by Dr. Olof H. Pearson of the School of Medicine of Western Reserve University, at first by the method of hemagglutination inhibition¹¹ and later by radioimmunoassay.¹² The results by both methods are comparable in the normal range.¹³

* *Fellow, Department of Endocrinology.*

† *Senior Consultant, Department of Endocrinology.*

Hypoglycemia was produced by intravenous injection of insulin in a dose of 0.2 unit per kilogram of body weight, i.e., 18 units, and blood sugar and growth-hormone determinations were made at 30 and at 60 minutes. Hyperglycemia was produced by intravenous injection of an infusion containing 75 gm. of dextrose given over a period of one hour. The blood sugar and growth-hormone determinations were made at 30 minutes, at 60 minutes, and at 90 minutes after the infusion was started. The serum calcium was measured by the method of Clark and Collip.¹⁴ The serum phosphorus¹⁵ and alkaline phosphatase¹⁶ values were determined with the AutoAnalyzer. The 17-ketosteroids^{17, 18} and 17-hydroxycorticosteroids¹⁹ were measured in the 24-hour urine specimen. Urinary gonadotropins²⁰ were measured in 24-hour specimens of urine, and the SU-4885 test (2-methyl-1, 2-bis (3-pyridyl)-1-propanone) (Metopirone, Ciba), as described by Liddle and associates²¹ was performed before and after the operation. In the test, 750 mg. of Metopirone was given orally every four hours for 24 hours. A 24-hour urine specimen for measurement of 17-hydroxycorticosteroids and 17-ketosteroids was obtained the day before, the day of, and the day after administration of Metopirone. The thyroid function studies included determinations of protein-bound iodine,²² basal metabolic rate, serum cholesterol, and 24-hour radioiodine uptake. Semen specimens were obtained before and after the operation.

REPORT OF A CASE

A 51-year-old white steelworker was first examined here in June 1963 because of various disturbing symptoms. His shoe size had increased from 7 to 10½ in the previous five years. His lips and tongue had recently increased in size considerably. He had noticed some decrease in sexual potency. He had frequent aching pains in his shoulders, back, and hands. He had no loss of vision. One week previous to his examination here he had a severe occipital headache for the first time, which had necessitated an injection of analgesic by his family physician.

In the last year or two he had noted some weakness and fatigability in his legs. His blood pressure had been persistently high for the last three years. A roentgenogram of the chest had shown an enlarged heart in 1958. His family history was not contributory. There was no diabetes mellitus or hypertension in his family. He was married and had a 21-year-old daughter.

His height was 70 in. and weight 197 pounds. The blood pressure was 150/95 mm. of Hg. The pulse rate was 80. He had the typical features of acromegaly. His hands and feet were "huge." He had moderately severe prognathism, a large tongue and lips, prominent supraorbital ridges, wide spacing of the teeth, and malocclusion (*Fig. 1*). The ocular fundi were normal and he had no visual field defect except a small bitemporal decrease in fields of color.

He had no thyroid enlargement, no rales, no cardiomegaly. He had regular cardiac rhythm with a grade 2 apical systolic murmur radiating to the left sternal border; the peripheral pulses were normal. The abdomen revealed no hepatomegaly or splenomegaly. He had a hydrocele on the left side. Testes were normal in size and consistency. The joints revealed no limitation of movement; there was a slight weakness in the quadriceps muscles of the thigh. The neurologic findings were normal. An electrocardiogram showed incomplete right bundle-branch block. The results of the laboratory tests are listed in *Tables 1, 2, and 3*.

IMPLANTATION OF YTTRIUM⁹⁰ IN ACROMEGLIC

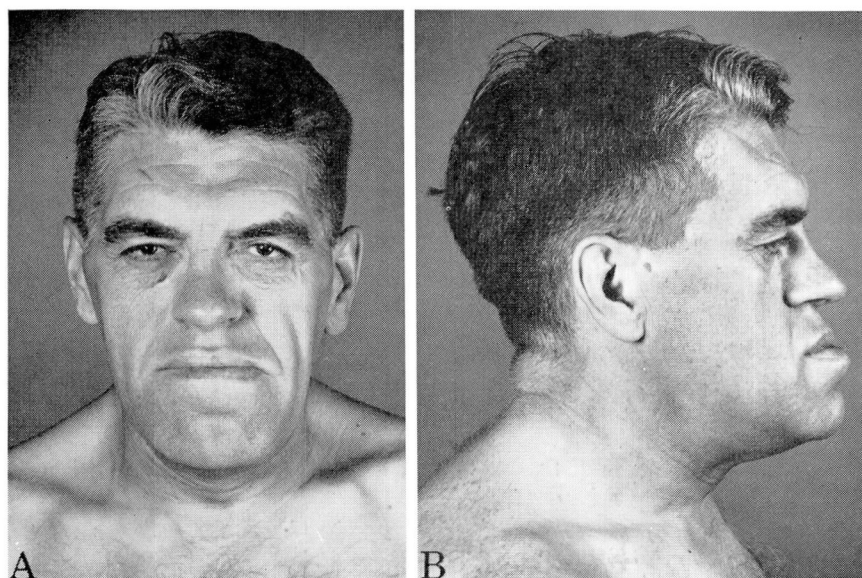


Fig. 1. Photograph taken before implantation of Y⁹⁰ in the pituitary.

Table 1.—*Growth hormone determinations before yttrium⁹⁰ implantation in the pituitary*

Test	Yttrium ⁹⁰ implantation		
	Before	After	
	Growth hormone, mμg.*	Growth hormone, mμg.†	Blood sugar, mg./100 ml.
Fasting	12.8	2.2	64
After insulin			
30 min.	—	1.7	22
60 min.	—	2.3	40
Fasting	—	2	77
After beginning of dextrose infusion			
30 min.	—	1.9	172
60 min.	—	1.5	218
90 min.	—	0.5	154

* Measured by hemagglutination inhibition method.

† Measured by radioimmunoassay method.

Normal growth hormone concentration, 1 to 5 mμg./ml.

Table 2.—*Metopirone test*

Metopirone test	Yttrium ⁹⁰ implantation					
	Before		14 months after		24 months after	
	17-KS*	17-OHCS†	17-KS*	17-OHCS†	17-KS*	17-OHCS†
Baseline	10	6.1	14.9	7.9	8.0	3.1
Day of Metopirone	—	—	—	—	9.1	4.9
Day after Metopirone	—	—	18.4	10.4	16.2	5.7

* 17-KS = 17-ketosteroids.

† 17-OHCS = 17-hydroxycorticosteroids.

Table 3.—*Laboratory tests before and after yttrium⁹⁰ implantation in the pituitary*

Assays	Yttrium ⁹⁰ implantation	
	Before	2½ years after
Total urinary gonadotropins	>13 <105	>13 <105
Serum phosphorus, mg./100 ml.	4.0	3.0
Protein-bound iodine, µg./100 ml.	4.1	5.2
Basal metabolic rate	+8%	—10%
Serum cholesterol, mg./100 ml.	180	175
Radioiodine uptake	25%/24 hr.	20%/20 hr.
Glucose tolerance, mg./100 ml.: 1 hr.	183	181
2 hr.	95	124
Semen examination: Volume, ml.	2.8	6.4
Sperm count	51 m./ml.	418 m./ml.
Motility, 1 hr.	5%, 3+ motile	30%, 3+ motile

The roentgenogram of the skull revealed erosion of the posterior clinoids, and the sella turcica appeared to have a double floor. Stereolateral views and a posteroanterior view of the sella turcica showed that the right rim of the sella turcica was in its normal position for the first 5 mm. but that the floor then dipped sharply downward toward the left so that the rim on the left side was 23 mm. in the anteroposterior dimension and approximately 19 mm. in depth. A roentgenogram of the right hand showed broadening of all the bones and thickening of the soft tissues with large unguial tufts and periosteal hypertrophy with irregular roughening. The chest was normal according to a roentgenogram; there was no cardiomegaly.

In July 1963 the patient underwent implantation of yttrium⁹⁰ in the pituitary gland; there were no postoperative complications. Cortisone was given after surgery and he was discharged from the hospital with the advice to take 12.5 mg. of cortisone acetate twice a day.

His friends have told him that he looks thinner. The joint pains disappeared. After two years he had not noticed any change in the size of feet but his hands were more bony and the size of his collar had diminished by half a size (*Fig. 2*). His new upper dental plate is decidedly smaller than the old one. He has had no more headaches. He stated that

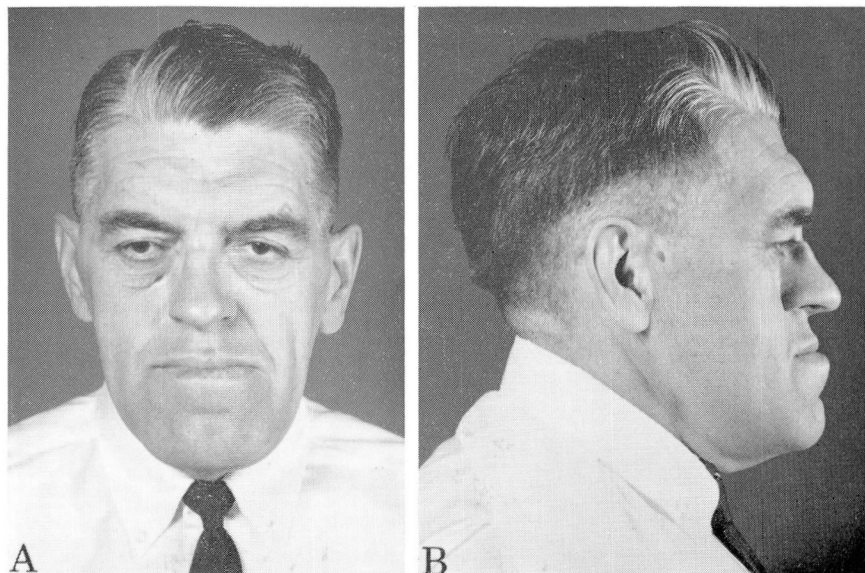


Fig. 2. Photograph taken two years after implantation of Y⁹⁰ in the pituitary.

potency had returned, and he feels generally much better. Roentgenograms of the skull and hands did not change appreciably after the operation (*Fig. 3 and 4*). The serum phosphorus concentration decreased from 4.0 mg. preoperatively to 3.0 mg. per 100 ml. Determinations of urinary gonadotropins, thyroid function, and glucose tolerance were essentially unchanged (*Table 3*). The blood growth-hormone concentration decreased postoperatively and there was no increase after administration of insulin (*Table 1*). The Metopirone test performed postoperatively showed "limited pituitary reserve," which could be due to the acromegaly itself or to the hypophysectomy (*Table 2*).

COMMENT

This patient with acromegaly has had good results from the intrasellar implantation of Y⁹⁰, a procedure that he tolerated well without complication and with a rapid postoperative recovery. Much larger doses than were used in this patient have been used in some of the other patients, and in those of Molinatti and associates.⁴ The procedure in more recent cases has included careful calculation of pituitary size and geometric contour to facilitate a more accurate distribution of sources of irradiation and a methodical calculation of the number of radioactive pellets and their strength.

The criteria used for evaluation of progress in this man were the physical appearance, and the values of serum phosphorus and of the growth hormone in the peripheral blood.

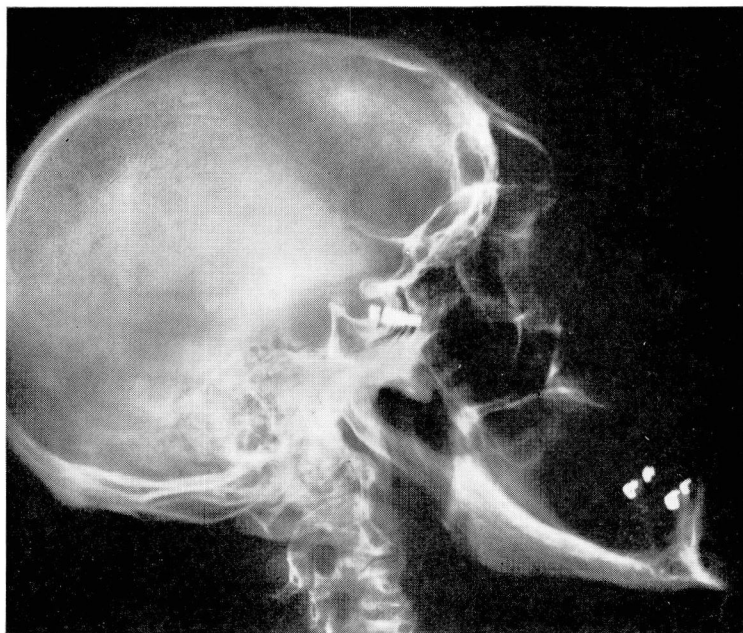


Fig. 3. Roentgenogram of the skull taken after implantation of Y^{90} in the pituitary.

Content of growth hormone in the blood, determined by hemagglutination inhibition or radioimmunoassay, has been found to be increased by hypoglycemia in normal patients,²³⁻²⁶ and the lack of response to insulin has been seen in patients who have pituitary failure.²⁴ Unfortunately the patient's response to hypoglycemia and hyperglycemia were not evaluated preoperatively in the case we report, but the absence of response to hypoglycemia after operation, along with low fasting levels of growth hormone, leads us to believe that his pituitary has a deficient capacity in the production of growth hormone. Hyperglycemia has been said to suppress the production of growth hormone,²⁶ and the growth-hormone level decreased from 2 to 0.5 m μ g. per milliliter in the presence of hyperglycemia. Acromegalics have been found to have inconsistent responses to hyperglycemia.²⁷

SUMMARY

A patient with acromegaly had clinical improvement after implantation of yttrium⁹⁰ in the pituitary gland: serum phosphorus levels decreased and growth-hormone values decreased from more than twice normal preoperatively to within normal range postoperatively, and hypoglycemia did not produce an increase in the growth-hormone concentration.

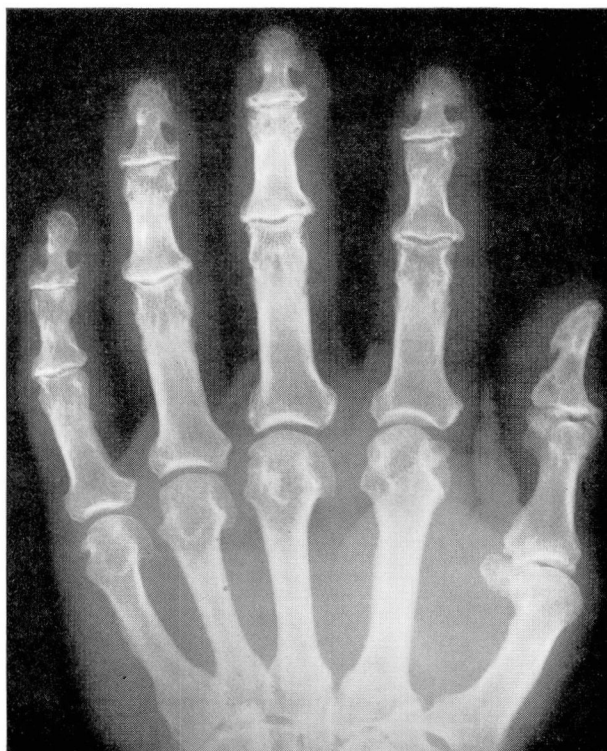

Fig. 4. Roentgenogram of the hand, showing typical changes of acromegaly.

REFERENCES

1. Forrest, A. P. M.; Blair, D. W., and Valentine, J. M.: Screw implantation of the pituitary with yttrium-90. *Lancet* 2: 192-193, 1958.
2. Fraser, R.; Joplin, G. F.; Laws, J. W.; Morrison, R., and Steiner, R. E.: Needle implantation of yttrium seeds for pituitary ablation in cases of secondary carcinoma. *Lancet* 1: 382-386, 1959.
3. Joplin, G. F.; Steiner, R.; Fraser R.; Laws, J., and Jones, E.: Partial pituitary ablation by needle implantation of gold-198 seeds for acromegaly and Cushing's disease. *Lancet* 2: 1277-1281, 1961.
4. Molinatti, G. M.; Camanni, F.; Massara, F.; Olivetti, M.; Pizzini, A., and Guiliani, G.: Implantation of yttrium 90 in the sella turcica in sixteen cases of acromegaly. *J. Clin. Endocrinol.* 22: 599-611, 1962.
5. Falconer, M. A.: Pituitary implantation of radioactive isotopes for medical diseases. *Proc. Roy. Soc. Med.* 58: 62-63, 1965.
6. McCullagh, E. P.; Feldstein, M. A.; Tweed, D. C., and Dohn, D. F.: A study of pituitary function after intrasellar implantation of ⁹⁰yttrium. *J. Clin. Endocrinol.* 25: 832-842, 1965.
7. Bonis, A.; Talairach, J.; Szikla, G., and Covello, L.: Résultats de la radiothérapie

- interstitielle (Au 198-Ir 192) dans 30 cas d'acromégalie. *Presse méd.* 73: 473-477, 1965.
8. Greenwood, F. C.; Stewart, H. J.; Forrest, A. P. M., and Wood, R. G.: Plasma-growth-hormone levels in untreated acromegaly and after radioactive implants into the pituitary. *Lancet* 2: 555-558, 1965.
 9. Linfoot, J. A., and Greenwood, F. C.: Letter to the editor. Growth hormone in acromegaly: effect of heavy particle irradiation. *J. Clin. Endocrinol.* 25: 1515-1518, 1965.
 10. Hoffman, W. S.: A rapid photoelectric method for the determination of glucose in blood and urine. *J. Biol. Chem.* 120: 51-55, 1937.
 11. Yen, S. S. C.; Pearson, O. H., and Stratman, S.: Growth hormone levels in maternal and cord blood. *J. Clin. Endocrinol.* 25: 655-660, 1965.
 12. Greenwood, F. C.; Hunter, W. M., and Kloppe, A.: Assay of human growth hormone in pregnancy at parturition and in lactation; detection of a growth-like substance from the placenta. *Brit. M. J.* 1: 22-26, 1964.
 13. Pearson, O. H.: Personal communication, May 1966.
 14. Clark, E. P., and Collip, J. B.: A study of the Tisdall method for the determination of blood serum calcium with a suggested modification. *J. Biol. Chem.* 63: 461-464, 1925.
 15. Fiske, C. H., and Subbarow Y.: The colorimetric determination of phosphorus. *J. Biol. Chem.* 66: 375-400, 1925.
 16. Marsh, W. H.; Fingerhut, B., and Kirsch, E.: Adaptation of an alkaline phosphatase method for automatic colorimetric analysis. *Clin. Chem.* 5: 119-126, 1959.
 17. Klendshoj, N. C.; Feldstein, M., and Sprague, A.: Determination of 17-ketosteroids in urine. *J. Clin. Endocrinol.* 13: 922-927, 1953.
 18. Ware, A. G.; Demetrios, J. A.; Notrica S.; Searcy, R.; Walberg, C., and Cox, F.: Elimination of interfering chromogens in the Zimmermann reaction for measuring 17-ketosteroids. *Clin. Chem.* 5: 479-487, 1959.
 19. Reddy, W. J.; Jenkins, D., and Thorn, G. W.: Estimation of 17-hydroxycorticoids in urine. *Metabolism* 1: 511-527, 1952.
 20. Gorbman, A.: Ultrafiltration of urine for collection and biological assay of excreted hypophyseal hormones. *Endocrinology* 37: 177-190, 1945.
 21. Liddle, C. W.; Estep, H. L.; Kendall, J. W., Jr.; Williams, W. C., Jr., and Townes, A. W.: Clinical application of a new test of pituitary reserve. *J. Clin. Endocrinol.* 19: 875-894, 1959.
 22. Leonards, J. R., and Davoren, P. R.: A semi-automatic determination of protein-bound iodine. *Ann. New York Acad. Sci.* 102: 83-86, 1962.
 23. Roth, J.; Glick, S. M.; Yalow, R. S., and Berson, S. A.: Hypoglycemia: a potent stimulus to secretion of growth hormone. *Science* 140: 987-988, 1963.
 24. Frantz, A. G., and Rabkin, M. T.: Human growth hormone; clinical measurement, response to hypoglycemia and suppression by corticosteroids. *New England J. Med.* 271: 1375-1381, 1964.
 25. Hunter, W. M., and Greenwood, F. C.: Radio-immuno-electrophoretic assay for human growth hormone. *Biochem. J.* 91: 43-56, 1964.
 26. Roth, J.; Glick, S. M.; Yalow, R. S., and Berson, S. A.: The influence of blood glucose on the plasma concentration of growth hormone. *Diabetes* 13: 355-361, 1964.
 27. Hartog, M.; Gaafar, M. A.; Meisser, B., and Fraser, R.: Immunoassay of serum growth hormone in acromegalic patients. *Brit. M. J.* 2: 1229-1232, 1964.