

A CHARACTERIZATION OF FOCAL LYMPHOCYTIC THYROIDITIS

DONALD R. WEAVER, M.D.,* SHARAD D. DEODHAR, M.D., PH.D., AND
JOHN BEACH HAZARD, M.D.

Division of Pathology

OF the various benign, inflammatory lesions affecting the thyroid gland, focal lymphocytic thyroiditis has been one of those most neglected in the past. Recently, interest in this lesion has grown, primarily to determine its true significance and, more specifically, its relationship to the diffuse form of lymphocytic thyroiditis (struma lymphomatosa)† described by Hashimoto¹ in 1912. The diffuse form is a recognized clinicopathologic entity, and in accord with recent studies on the association of circulating, thyroid autoantibodies with human and experimental thyroiditis,² struma lymphomatosa is now widely regarded as the prototype of autoimmune disease. Morphologically, the focal type of lymphocytic thyroiditis appears to be a patchy variety of the diffuse type. It has been suggested^{3, 4} that the focal lesion represents the earliest morphologic evidence of immunologic damage to the thyroid gland. If the concept is correct, then one would expect to find a significant frequency of association of this focal lesion with many of the possibly autoimmune diseases. Indeed, such association has been reported between focal lymphocytic thyroiditis and collagen diseases,⁵ diabetes mellitus,⁶ and pernicious anemia.^{7, 8}

In view of the great interest, at this institution, in thyroid pathology, and the availability of a large volume of appropriate surgical and autopsy material, a study was undertaken to explore further the nature and the significance of focal lymphocytic thyroiditis and its relationship to other thyroid and systemic diseases.

MATERIALS AND METHODS

Plan of study. In this study, 797 thyroid glands, 397 removed at operations and 400 at autopsies, were examined. It was believed that the surgical cases would reflect thyroiditis in patients who had clinically evident thyroid diseases, whereas, the autopsy cases, representing a much more random group, would provide correlation with other disease processes not limited to the thyroid gland. Biopsy specimens were not included in this study. Thyroid

* Currently Fellow in the Department of Clinical Pathology.

† The terms *diffuse lymphocytic thyroiditis*, *struma lymphomatosa*, and *Hashimoto's thyroiditis* are used synonymously.

antibody tests were performed in certain phases of the study.* In addition, sera from a separate group of diabetic patients and nondiabetic control patients were tested for thyroid antibodies.

Surgical series. The microscopic sections and reports for all surgical specimens of thyroid glands, exclusive of biopsies, examined in the Department of Pathology in the years 1948 (267 cases) and 1962 (130 cases) were reviewed, and the presence of lymphocytic thyroiditis and concomitant thyroid pathologic changes was noted. Each specimen was classified according to the sex and age of the patient. The years 1948 and 1962 were specifically chosen in order to give a lapse of time sufficient to indicate any possible trend in incidence.

When focal thyroiditis was present, an attempt was made to grade the severity of the process. In all instances the lymphocytic infiltration was focally dense and the lymphocytes were in contact with follicular epithelium. Initially a grading system of 1 to 4 was devised, based on the number of foci of lymphocytes present in an area of 110 square millimeters (4 microscopic fields at magnification $\times 35$). However, it became evident that two categories could adequately define the extent of the lesion, namely, mild focal thyroiditis and severe focal thyroiditis. In the mild group, less than 12 foci of lymphocytes were present in any reference area of 110 square millimeters (*Fig. 1*). In the severe group (*Fig. 2*), the number of lymphocytic foci ranged from 13 to 35. Often large areas were infiltrated with interfollicular collections of lymphocytes and plasma cells resembling a miniature localized form of struma lymphomatosa. Follicle formation of lymphocytes and focal folliculitis, characterized by a localized, severe, inflammatory reaction in the follicle wall and intrafollicular collections of histiocytes and lymphocytes were more frequently present in the severe form of focal thyroiditis than in the mild form. Epithelial hypertrophy or oxyphilia was always present in at least one area in the cases of severe focal thyroiditis. These epithelial changes were only occasionally present in the mild cases.

Foci of lymphocytes and plasma cells not in contact with epithelium but occurring in areas of fibrosis were not considered as lymphocytic thyroiditis, since an infiltrate of this nature most likely represents a nonspecific inflammatory change.

Autopsy series. The series comprised 400 consecutive autopsies, beginning in 1962 and extending into 1964, in which the thyroid gland was available for examination. Microscopic sections of four tissue blocks (two from each lobe) from each thyroid gland were studied, and focal lymphocytic thyroiditis was graded according to the system already described: mild and severe

* We gratefully acknowledge the competent assistance of Miss Marion Sue Matz in performing all the thyroid antibody tests.

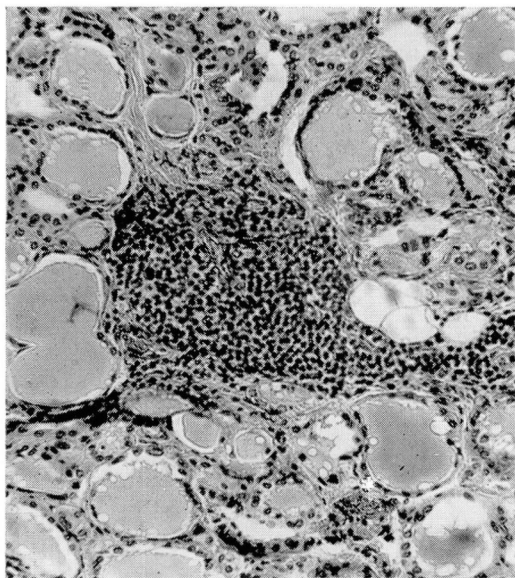


Fig. 1. Section of surgically removed thyroid gland showing mild focal lymphocytic thyroiditis, and isolated focus of lymphocytes without epithelial change. Hematoxylin and eosin stain; magnification $\times 100$.

types. Each case was classified according to the patient's age and sex, local pathologic changes of the thyroid, and systemic disease.

Our autopsy series of 400 cases included 19 cases of diabetes mellitus. In order to make this number more significant, an additional 27 diabetic cases for which microscopic slides of the thyroid gland were available were obtained from the 500 autopsies preceding the present series. The incidence of focal lymphocytic thyroiditis in these 46 diabetic cases was determined.

Of the 400 autopsy cases, three were cases in which the patient had scleroderma. This number of cases of scleroderma was increased to nine from those of autopsies preceding the series selected for our study.

Antibody studies. Circulating thyroid antibodies were determined by the tanned-red-cell agglutination and complement fixation technics as described by Doniach and Roitt and their associates.^{9, 10} The reagents used in this study were obtained from the Burroughs Wellcome & Co. (The Wellcome Foundation Ltd.) London, England. The antibody titer in each case was indicated by the highest dilution of the test serum at which positive agglutination or complement fixation was noted. Both of these procedures were performed in all cases, but for the sake of simplicity only the tanned-red-cell agglutination results are used in this report.

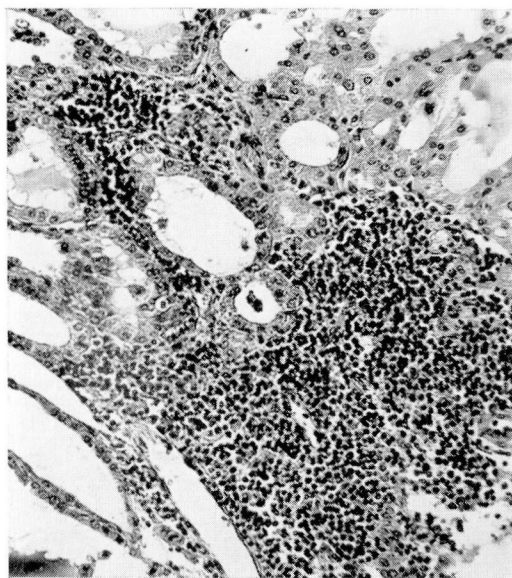


Fig. 2. Section of surgically removed thyroid gland showing severe focal lymphocytic thyroiditis with hypertrophy of the epithelial cells; these were oxyphilic in character. Large areas of this gland were similar to this section in appearance. Hematoxylin and eosin stain; magnification $\times 100$.

During the years 1963 and 1964, sera from 387 (244 men and 143 women) autopsy cases were analyzed for the presence of thyroid antibodies. Of these cases, 163 were from the autopsy series in which the thyroid glands were examined microscopically. In these latter cases a direct correlation between the presence of thyroid antibodies in the serum and lymphocytic thyroiditis in the thyroid gland could be made.

The correlation between circulating thyroid antibodies and diabetes mellitus was studied by determining the thyroglobulin antibody titer in the sera of 73 diabetic patients from the hospital and the Clinic. A like number of nondiabetic control patients, matched with respect to age and sex, were tested.

ANALYSIS OF DATA

Overall incidence. The results of the surgical group reflected the incidence of lymphocytic thyroiditis in thyroid glands that were removed surgically as treatment for clinically apparent thyroid disease. The percentages give a true representation of focal lymphocytic thyroiditis but not of the diffuse variety. The latter disease was usually suspected clinically and diagnosed by needle biopsy. Since data from needle biopsies were not included in this

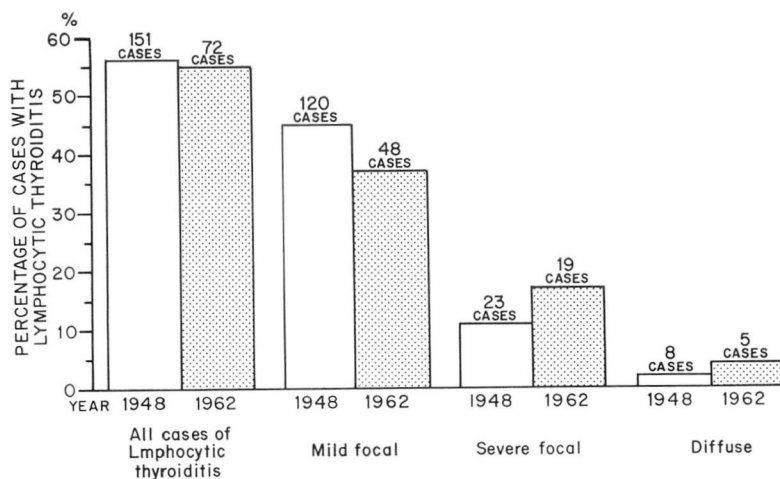


Fig. 3. Graph showing incidence of lymphocytic thyroiditis in 267 surgical cases in 1948, and in 130 surgical cases in 1962.

study, the majority of cases of struma lymphomatosa seen at this institution are not represented in this report. *Figure 3* illustrates graphically the incidence of lymphocytic thyroiditis in the two years 1948 and 1962. The total incidences were almost identical: 56 percent in 1948, and 55 percent in 1962. One hundred twenty patients (45 percent) had mild focal thyroiditis, in 1948, whereas 48 patients (37 percent) had this variety in 1962. Severe focal thyroiditis was present in 23 patients (11 percent) in 1948, and in 19 patients (17 percent) in 1962. These differences in percentage are regarded as not significant.

Of the 400 autopsy cases studied, in 113 there was some degree of lymphocytic thyroiditis (28 percent): the mild focal form, 21 percent; the severe focal form, 3.5 percent; and struma lymphomatosa representing 3.5 percent.

Sex incidence. In the surgical series there was no significant difference between the percentages of each sex with lymphocytic thyroiditis (*Fig. 4*). For a combination of the data for both years in the surgical series the overall incidence is 58 percent in 308 females and 50 percent in 89 males. The mild focal type was present in almost identical percentages of males (42 percent) and of females (43 percent), while the severe focal variety was somewhat more common in females (12 percent) than in males (4.5 percent).

In the autopsy group there was a female predominance (*Fig. 4*). Thirty-six percent of the 220 females and 18 percent of the 180 males had some degree of lymphocytic thyroiditis. For the mild-to-severe focal types, the female-to-male ratio was approximately 2:1, whereas it was greatly increased to 12:1 for the diffuse type.

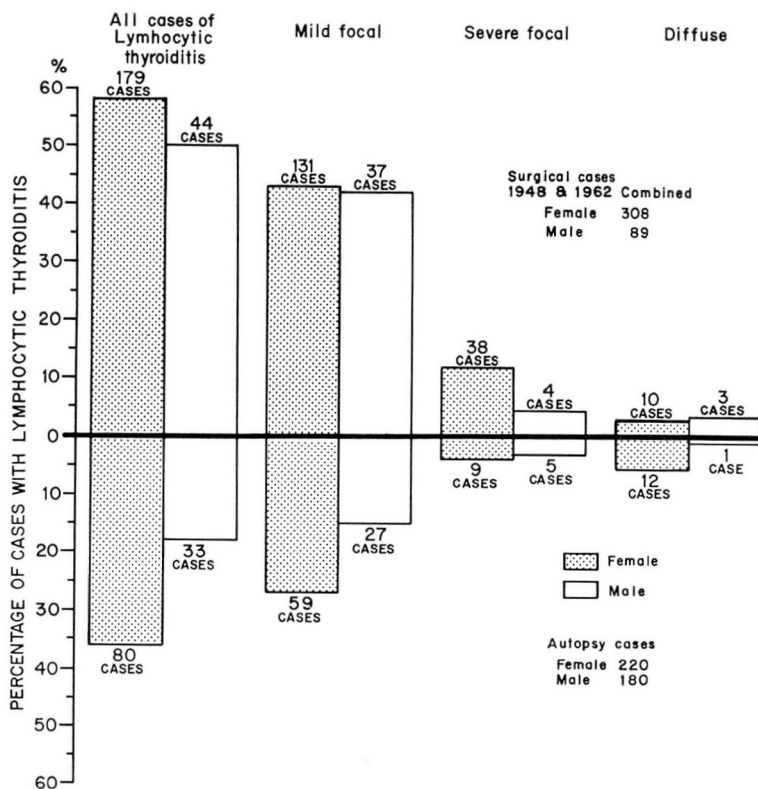


Fig. 4. Graph showing the distribution of lymphocytic thyroiditis by sex of the patient, in the surgical and in the autopsy series.

Age incidence. Age distribution of the patients with thyroiditis whose cases are in the surgical and autopsy series is illustrated in Figure 5. In the surgical cases, mild focal thyroiditis showed its peak incidence in the third decade, from which time on it slowly declined throughout the remainder of the age ranges. The incidence of the severe focal type decreased sharply after the fourth decade, and thereafter remained at a steady level. For the few cases of struma lymphomatosa in the series the highest incidence was after the sixth decade.

In the autopsy series, the incidence of mild focal thyroiditis reached a peak in patients in the fourth decade, with a second greater rise in incidence after the sixth decade. Severe focal thyroiditis did not appear in any patient less than 40 years of age, and showed no definite trend after this age. Struma lymphomatosa gradually increased in incidence after patients were 50 years of age.

Association with other thyroid pathologic changes. Of the associated

CHARACTERIZATION OF FOCAL LYMPHOCYTIC THYROIDITIS

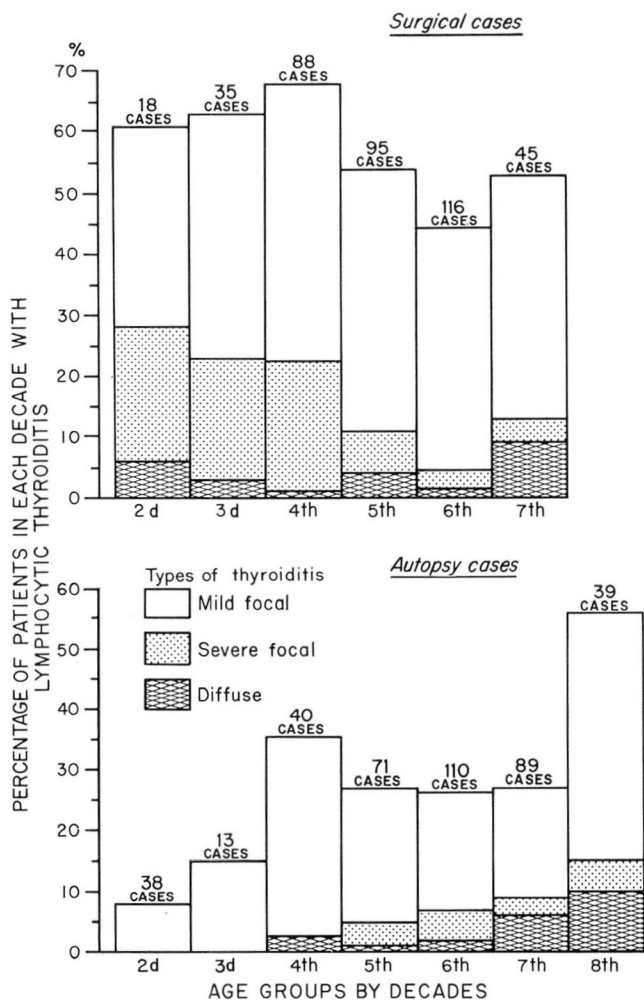


Fig. 5. Graph showing the age distribution of patients with lymphocytic thyroiditis in the surgical and in the autopsy series.

pathologic changes in the 397 thyroid glands in the surgical series, nodular goiters, adenomas, diffuse goiters with hyperthyroidism, and papillary carcinomas accounted for the majority of the cases, representing 174, 111, 49, and 29 cases, respectively (*Fig. 6*). Other lesions, such as follicular, medullary, undifferentiated, and secondary carcinomas were infrequently found (less than 10 each). Some degree of lymphocytic thyroiditis occurred most frequently in the diffuse goiter with hyperthyroidism group (73 percent). This incidence is consistent with the long-established observation that lymphocytic infiltration is frequently associated with diffuse, toxic goiter. Papil-

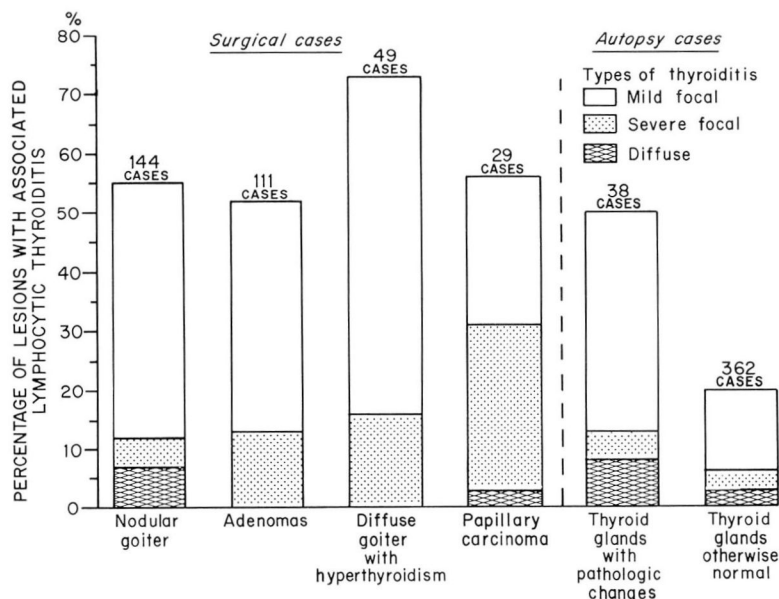


Fig. 6. Graph showing the association of lymphocytic thyroiditis with other pathologic changes of the thyroid gland.

lary carcinomas had the next highest percentage of association with focal thyroiditis generally (59 percent), and the highest percentage with the severe type (28 percent). The number of cases in this latter group was small, however. Only twice in the surgical series was the diagnosis of focal lymphocytic thyroiditis made exclusively without other thyroid disease. Both cases were of the severe focal type in diffusely enlarged glands, but without other recognizable thyroid disease. This illustrates how infrequently, in our experience, focal lymphocytic thyroiditis alone causes clinically detectable lesions.

At autopsy, significant pathologic changes other than lymphocytic thyroiditis were present in 38 of the 400 glands examined: 15 nodular goiters, 5 papillary carcinomas, 8 secondary carcinomas, 8 adenomas, and 2 cases of radioiodine effect.

In this group of 38 with coincident thyroid disease, the total incidence of lymphocytic thyroiditis was 50 percent, almost twice that (26 percent) found in the remaining 362 thyroid glands. All these glands in the latter group were either entirely normal, other than the lymphocytic thyroiditis present, or else showed only slight and insignificant microscopic changes, such as slight nodular change or slight interfollicular fibrosis. In this autopsy series,

focal lymphocytic thyroiditis alone was primarily associated with thyroid enlargement in only one instance. That gland weighed 48 gm. and had a severe focal type of thyroiditis.

In the thyroids with pathologic changes in addition to thyroiditis, the increase in incidence of focal thyroiditis was reflected both in mild and in severe forms. The 50 percent occurrence of lymphocytic thyroiditis in this portion of the autopsy series and the 56 percent incidence in the corresponding surgical group would seem to indicate that the thyroid gland in which there is a pathologic change is more susceptible to the development of lymphocytic thyroiditis, than the gland without such change.

Thyroid antibody study in the autopsy cases and correlation with lymphocytic thyroiditis. The overall incidence of thyroglobulin antibodies in the sera in the 387 autopsy cases which were tested was 26 percent. Thirty-three percent of the 143 women and 18 percent of the 244 men had antibodies, a female-to-male ratio of slightly less than 2:1. The incidence of lymphocytic thyroiditis was 28 percent in the autopsy series and the female-to-male ratio was 2:1.

In the 163 autopsy cases in which the thyroid glands were examined microscopically and the sera were tested for thyroglobulin antibodies, there was a direct correlation between the presence of lymphocytic thyroiditis and thyroglobulin antibodies. In 128 cases (73 percent) there was complete agreement, with 105 cases showing a negative correlation (absence both of thyroiditis and of antibody) and 23 showing a positive correlation (presence of both). In this latter group of 23, there appeared to be no definite relationship between the severity of the histologic change and the magnitude of the antibody titer (*Table 1*). It should be pointed out that the total number of cases in this group is too small to have adequate representation in each category as shown in *Table 1*.

In 15 cases, no lymphocytic thyroiditis was evident, although the antibody titer ranged from 1:5 to 1:250 in 13 cases, and was 1:2,500 in two cases. In six of these cases, death was due to complications of atherosclerosis; whereas

Table 1.—*Relationship between type of lymphocytic thyroiditis and thyroglobulin antibody titer in 23 cases at autopsy*

Type of lymphocytic thyroiditis	Antibody titer, number of cases				
	1:5	1:25	1:250	1:2,500	1:25,000
Mild focal	5	2	4	0	4
Severe focal	0	1	2	0	1
Diffuse (struma)	1	0	0	1	2

the other nine cases represented a wide variety of other disease processes. Whether these 15 cases represent truly false-negative tests, or whether they are due to inadequate sampling of thyroid tissue, is not yet clear.

In 20 cases, no thyroid antibodies could be detected, although there was evidence of some degree of lymphocytic thyroiditis. In 18 of these cases, it was only of the mild focal type; in the other two cases it was the diffuse type. It has been reported previously³ that thyroglobulin antibodies may be absent in focal lymphocytic thyroiditis and in a small percentage of cases of struma lymphomatosa. Another factor, which should be considered in the analysis of these 20 cases, is the processing of postmortem sera for antibody studies. We have observed that sera, with hemolyzed red cells and those collected after an unusually long interval between death and autopsy, frequently give erroneous results in the antibody analysis.

Association with systemic diseases. Scleroderma. Thyroid glands were obtained at autopsy from nine patients who had scleroderma. Of the nine cases in only one was there lymphocytic thyroiditis, and this was of the mild focal variety. Five of the nine patients had not been treated with steroids, and none of these had lymphocytic thyroiditis. This seems especially significant, since the absence of lymphocytic change in those cases could not be attributed to the lymphocyte-suppressing action of steroids.

Of the 46 thyroid glands obtained at autopsy from diabetic patients, only nine (approximately 20 percent) showed a degree of lymphocytic thyroiditis (*Table 2*). Of these nine, eight had the mild focal type while one had struma lymphomatosa. Thus, there was no evidence of an increased incidence of lymphocytic thyroiditis in the diabetic patients.

For the thyroid antibody study of diabetic patients, sera was collected from 72 patients with diabetes mellitus and from an equal number of subjects of a control, nondiabetic group, matched approximately in regard to age and sex. Any patient with clinically evident thyroid disease was excluded from this study. Eleven (15 percent) of the 73 diabetics gave a positive thyroglobulin antibody titer. In almost all cases this was in the range of 1:5 or through 1:250, which is considerably below that usually obtained in patients with struma lymphomatosa. Only one diabetic patient had a titer of 1:2,500. Within this group of 11, there appeared to be no correlation between the height of the antibody titer and the severity or duration of the diabetes, and the age and the sex of the patient.

Of 73 subjects in the control group, 10 (14 percent) subjects gave a positive titer, with eight in the range of 1:5 through 1:250, and two with a titer of 1:2,500. Thus, in our study, there appeared to be no significant difference in the incidences of thyroid antibodies in the diabetic and in the nondiabetic groups.

Other systemic diseases. Some of the systemic diseases associated with

Table 2.—*Systemic diseases associated with lymphocytic thyroiditis*

Group	Disease	Total number of cases	Number of cases of lymphocytic thyroiditis		
			Mild	Se- vere	Dif- fuse
1. Disease of possibly au- toimmune origin	Scleroderma	9	1	0	0
	Diabetes mellitus	46	8	0	1
	Rheumatoid arthritis	2	0	1	1
	Hypersensitivity angiitis	4	2	0	0
	Drug allergy	17	5	0	0
	Lupus erythematosus	2	0	0	0
	Glomerulonephritis	20	5	0	0
	Chronic ulcerative colitis	1	1	0	0
2. Malignant disease	Lymphoma	21	3	1	0
	Leukemia	17	2	0	0
	Carcinoma, various sites	86	20	3	1
	Sarcoma, various sites	6	2	0	0
3. Hepatic disease	Biliary cirrhosis	1	1	0	0
	Nutritional cirrhosis	8	1	0	0
	Postnecrotic cirrhosis	3	1	0	0

the thyroiditis in the autopsy series are listed in *Table 2*. For most of the diseases represented in *Table 2*, the number of cases was insufficient and therefore not significant, but they were considered primarily because of the current interest in their association with lymphocytic thyroiditis.

In group 1, representing diseases of possibly autoimmune origin, in both cases of rheumatoid arthritis there was associated lymphocytic thyroiditis (one severe focal and one diffuse). In two of four cases classified as hypersensitivity angiitis there was associated mild focal thyroiditis. In the other diseases in group 1 the association with lymphocytic thyroiditis was no more frequent than that occurring in the autopsy group as a whole. Group 2 (malignant disease) also showed no significant correlation with thyroiditis. In group 3 (hepatic disease) the number of cases studied was small, and again there was no striking correlation.

DISCUSSION

The true nature and significance of focal lymphocytic thyroiditis as yet remains undetermined. The presence of focal lymphocytic infiltrate, in association with diffuse, toxic goiter, has been known for a long time. It has also been noted to be frequently present in thyroid glands in which there are other

pathologic changes, such as nodular goiter and neoplasia,^{3, 4} and, sometimes, as an incidental finding at autopsy.⁸ Recently it was suggested that focal lymphocytic thyroiditis might represent the early stages of the diffuse type and that both lesions are most likely of autoimmune origin.^{3, 4} The possibility that such a relationship exists is supported by the following evidence: First, morphologically, focal lymphocytic thyroiditis appears to be a patchy variety of the diffuse lesion. Secondly, thyroid antibodies have been found in the sera of patients with focal lymphocytic thyroiditis. Senhauser³ demonstrated that both the frequency of occurrence and the height of the titer of the antibodies increase as the severity of the focal thyroiditis increases. Thirdly, both types of lymphocytic thyroiditis have been produced experimentally in guinea pigs by injections of homologous thyroid extract and Freund's adjuvant.¹¹ In addition, reports by others have demonstrated a significantly higher incidence of focal lymphocytic thyroiditis and circulating thyroid antibodies in association with collagen diseases,⁵ and other diseases of possibly autoimmune origin such as pernicious anemia^{7, 8, 12} and diabetes mellitus.⁶ Although it has been questioned in a recent paper,¹³ a relationship between struma lymphomatosa and systemic diseases of possibly autoimmune origin has been generally accepted in recent years.

Attempts have been made to demonstrate a progression in the severity of the inflammatory change in lymphocytic thyroiditis, mostly with respect to the diffuse variety. Vickery and Hamlin¹⁴ found only slight progression of severity in four of 16 cases. Woolner, McConahey, and Beahrs⁴ reported finding diffuse thyroiditis in the remaining thyroid lobe of a patient several years after partial thyroidectomy had revealed focal lymphocytic thyroiditis. The results of our study suggest that, although diffuse lymphocytic thyroiditis might originate as a focal lesion resembling focal lymphocytic thyroiditis as that described here, the majority of cases of the focal type did not progress to the diffuse type. The natural histories of the two lesions appeared to be entirely different. The age and sex distributions of the patients in regard to the two lesions varied widely. In our study in the autopsy series, the focal lesion was twice as common in women as in men, while the diffuse type was 12 times more common in women than in men. Although the number of cases of the diffuse type was small in our series, the female-to-male ratio of incidence appears to be in agreement with that reported by Woolner, McConahey, and Beahrs.⁴ Yet the female-to-male ratio of 2:1 for focal lymphocytic thyroiditis in our series differs greatly from the 20:1 ratio reported by those authors. However, the ratio we found is in agreement to that (2:1) in the series reported by Williams and Doniach.⁸

The results of our study showed no significant association of focal lymphocytic thyroiditis with scleroderma and diabetes mellitus on histologic or

serologic grounds. With certain other diseases such as rheumatoid arthritis and hypersensitivity angitis, the number of cases studied was too small to permit definitive evaluation.

In our study, focal lymphocytic thyroiditis was associated most commonly with other pathologic changes in the thyroid gland. Thus, in the autopsy series and the surgical series, more than 50 percent of the glands affected with various lesions showed lymphocytic thyroiditis. When the gland was otherwise normal, as in 362 of the autopsy cases, only 25 percent of these showed lymphocytic thyroiditis. It was interesting that circulating thyroid antibodies also were present in the sera of about 25 percent of the autopsy cases. Moreover, in a significant number of cases, there appeared to be a direct qualitative correlation between the presence of lymphocytic thyroiditis and the thyroglobulin antibody.

It is our current belief that focal lymphocytic thyroiditis, as it occurs in most cases, represents an immunologic response on the part of the thyroid gland to varied stimuli. Focal lymphocytic thyroiditis seems to bear no special relationship to struma lymphomatosa, scleroderma, diabetes mellitus, or various other diseases. The natural history of focal lymphocytic thyroiditis, in the majority of the cases, is entirely different from that of struma lymphomatosa. Focal lymphocytic thyroiditis does bear a relationship to local pathologic changes within the thyroid gland, and it seems possible that in some instances these changes could be the initiating stimulus of this immunologic response.

SUMMARY

1. The significance and relationship of focal lymphocytic thyroiditis to struma lymphomatosa and other diseases of possibly autoimmune origin were investigated through examination of 797 thyroid glands obtained at surgery or at autopsy. Circulating thyroid antibodies to thyroglobulin were determined also, in certain selected cases.

2. The age and sex distributions of patients having lymphocytic thyroiditis were different from those of patients having struma lymphomatosa. The natural history of focal lymphocytic thyroiditis, in the majority of the cases, was entirely different from that of struma lymphomatosa.

3. No significant association could be histologically or serologically demonstrated between focal lymphocytic thyroiditis and scleroderma or diabetes mellitus, or the other systemic diseases investigated.

4. Focal lymphocytic thyroiditis was twice as common in thyroids affected by other disease processes as compared with those that were otherwise normal. The presence of circulating antibodies to thyroglobulin in sera correlated well with the occurrence of focal thyroiditis in the autopsy series.

These findings suggest that, in many instances, the focal type of thyroiditis is an immunologic response initiated by local tissue damage within the thyroid gland.

REFERENCES

1. Hashimoto, H.: Zur Kenntniss der lymphomatösen Veränderung der Schilddrüse (struma lymphomatosa). *Arch. f. klin. Chir.* **97**: 219-248, 1912.
2. Roitt, I. M., and Doniach, D.: Lymphoid thyroiditis as a model for auto-immune disease. *Acta Allerg.* **18**: 474-478, 1963.
3. Senhauser, D. A.: Immunologic Correlations in Thyroid Diseases, chap. 10, p. 167-182, in Hazard, J. B., and Smith, D. E. (editors): *International Academy of Pathology Monograph, The Thyroid*. Baltimore: The Williams & Wilkins Company, 1964, 288 p.
4. Woolner, L. B.; McConahey, W. M., and Beahrs, O. H.: Struma lymphomatosa (Hashimoto's thyroiditis) and related thyroidal disorders. *J. Clin. Endocrinol.* **19**: 53-83, 1959.
5. Ferguson, R. H., and Becker, K. L.: Hashimoto's thyroiditis and the collagen diseases. *Postgrad. Med.* **36**: 270-273, 1964.
6. Moore, J. M., and Neilson, M. M.: Antibodies to gastric mucosa and thyroid in diabetes mellitus. *Lancet* **2**: 645-647, 1963.
7. Mackay, I. R.: Autoimmune serological studies in chronic gastritis and pernicious anaemia. *Gut* **5**: 23-26, 1964.
8. Williams, E. D., and Doniach, D.: The post-mortem incidence of focal thyroiditis. *J. Path. & Bact.* **83**: 255-264, 1962.
9. Doniach, D., and Roitt, I. M.: Auto-antibodies in disease. *Ann. Rev. Med.* **13**: 213-240, 1962.
10. Fulthorpe, A. J.; Roitt, I. M.; Doniach, D., and Couchman, K.: A stable sheep cell preparation for detecting thyroglobulin auto-antibodies and its clinical applications. *J. Clin. Path.* **14**: 654-660, 1961.
11. Rose, N. R., and Witebsky, E.: Studies on organ specificity. V. Changes in the thyroid glands of rabbits following active immunization with rabbit thyroid extracts. *J. Immunology* **76**: 417-427, 1956.
12. Goudie, R. B.; Anderson, J. R., and Gray, K. G.: Complement-fixing antithyroid antibodies in hospital patients with asymptomatic thyroid lesions. *J. Path. & Bact.* **77**: 389-400, 1959.
13. Masi, A. T.; Hartmann, W. H.; Hahn, B. H.; Abbey, H., and Shulman, L. E.: Hashimoto's disease: a clinicopathologic study with matched controls; lack of significant association with other "autoimmune" disorders. *Lancet* **1**: 123-126, 1965.
14. Vickery, A. L., and Hamlin, E., Jr.: Struma lymphomatosa (Hashimoto's thyroiditis). Observations on repeated biopsies in sixteen patients. *New England J. Med.* **264**: 226-229, 1961.