

## BIOPSY OF SCALENE AND SUPRACLAVICULAR LYMPH NODES: VALUE IN DIAGNOSIS

WILLIAM E. MILLER, M.D.,\* and ALFRED M. TAYLOR, M.D.

*Department of Internal Medicine*

**T**O determine the diagnostic value of biopsy of scalene and supraclavicular lymph nodes the pertinent clinical records and surgical pathologic reports over a 12-year period, from 1950 to 1962, were studied.

### Material and Methods

The records of the findings on 500 consecutive unilateral biopsies in 500 patients were reviewed. Included were 305 males and 195 females with ages ranging from 11 to 85 years; 442 were white and 58 were Negro.

All biopsies were done by members of the Department of Thoracic and Cardiovascular Surgery, of Plastic Surgery, or of General Surgery. All the scalene biopsies were performed by members of the former two departments. For scalene nodes the technic of Daniels<sup>1</sup> was followed without the modification of Harken and associates.<sup>2</sup>

Since a description of the precise site of biopsy was not always available, we classified the lymph nodes that were clinically palpable as supraclavicular and those that were nonpalpable as scalene.

A biopsy was considered to be positive when a significant lesion was found, and to be negative when an insignificant or no lesion was found.

### Results

In *Figure 1* percentages of positive biopsies of palpable and nonpalpable lymph nodes are compared. The percentage of positive results was higher in the group of palpable nodes (98.3 percent of 323 specimens) than in the group of nonpalpable nodes (75.7 percent of 177 specimens). This has been the experience of others.<sup>3-7</sup>

*Bronchogenic carcinoma.* The primary disease in the largest single group of cases in this series was bronchogenic carcinoma. Of the 138 cases, biopsies were positive in 104: 72 of the 75 in the supraclavicular site and 32 of the 63 in the scalene area.

The pattern of metastatic spread of the primary pulmonary lesion to the lymph nodes is shown in *Table 1*. Fifty-three of 59 lesions on the right side involved the ipsilateral supraclavicular nodes. Lesions of the left upper lobe metastasized to the left supraclavicular nodes in 25 of 28 instances. However, carcinoma of the left lower lobe showed a nearly equal involvement of the right (8 cases) and left (9 cases) supraclavicular lymph nodes. This conforms with Rouvière's<sup>8</sup> anatomic description of the pulmonary lymph drainage.

\*Fellow in the Department of Internal Medicine.

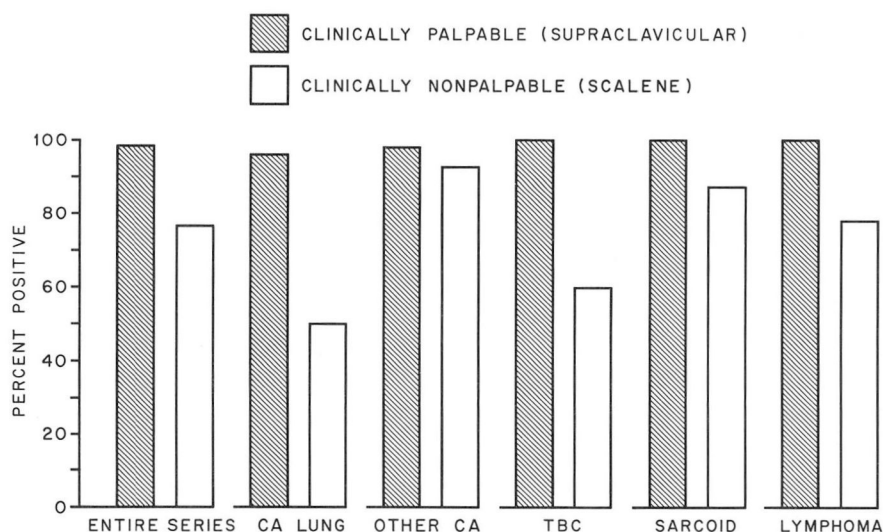


Fig. 1. Comparison of percentages of positive biopsies of palpable and nonpalpable lymph nodes. Tuberculous adenitis (TBC).

Table 1.—Bronchogenic carcinoma: pattern of metastatic spread in 104 cases

Location of primary carcinoma	Location of lymph nodes		Total number of cases
	Right side	Left side	
	Number of cases		
Right side	53	6*	59
Left side	11	34	45
Upper lobe	3*	25	28
Lower lobe	8	9	17

\*It should be noted that 8 of 9 biopsies from areas that did not follow the usual pulmonary lymph drainage were from palpable nodes.

*Other carcinomas.* The primary disease in 152 cases in this series was carcinoma in a variety of sites other than the lungs (Table 2). In 69 of the 152 patients, the primary site of the neoplasm was not known.

Biopsies were positive in 122 (98 percent) of the 124 cases of palpable lymph nodes (supraclavicular) and in 26 (93 percent) of the 28 cases of nonpalpable (scalene) lymph nodes. Malignant tumors originating in the peritoneal area most frequently involved the left supraclavicular nodes (44 of 59 instances), coinciding

**Table 2.**—Incidence of primary carcinoma in locations other than lungs

Location	Number of cases
Stomach	17
Other gastrointestinal areas	26
Breast	17
Pelvis (female)	11
Genitourinary tract	8
Thyroid	4
Not known	69
Total	152

with the predominant lymphatic drainage of the abdomen and pelvis. Ipsilateral spread occurred in 14 of 17 patients with breast carcinoma.

*Tuberculous adenitis.* The diagnosis of tuberculosis was made on the basis of lymph node biopsy in 19 cases, 16 from supraclavicular nodes and 3 from scalene nodes. In two additional cases biopsy was negative although the presence of pulmonary tuberculosis had been confirmed by the findings on sputum culture. A significant number of the lymph nodes were positive for *Mycobacterium tuberculosis* on culture.

*Sarcoid.* The pathologic findings on biopsy were consistent with a diagnosis of sarcoid in 47 of the 52 proved cases of this disease. All 12 biopsies from the supraclavicular area were positive and 35 of 40 from the scalene region. In five cases the biopsies were negative, despite the proved existence of the disease.

*Lymphoma.* Eighty patients with lymphoma were included in this series. In all 66 patients with supraclavicular nodes the clinical diagnosis was confirmed by biopsy. In 11 of the 14 patients with scalene nodes the biopsy was positive. The majority of nodes involved by the lymphomas were on the left, a finding that substantiates the suggestion of Jackson and Parker<sup>9</sup> in 1944 that lymphoma has a central or truncal origin.

*Miscellaneous conditions.* The miscellaneous diagnoses in 11 cases are listed in Table 3.

*No pathologic diagnosis.* In 46 of the 500 patients, no pathologic diagnosis could be made by clinical investigation or lymph node biopsy. Twenty-six had a scalene node biopsy, the other 20 a supraclavicular procedure.

*Complications of biopsy.* In the 500 cases of this series, complications consequent to biopsy were of a minor nature: bleeding at the time of biopsy or transient lymphorrhea lasting a few days. These complications have been noted by others.<sup>3, 10</sup> In one patient not included in this series, cardiac arrest or air embolism developed at the time of skin incision for biopsy. Resuscitative measures were promptly

**Table 3.**—*Incidence of miscellaneous diagnoses*

Diagnosis	Number of cases
Neurilemmoma	3
Plasmacytoma	3
Seminoma	1
Infectious mononucleosis	1
Chronic granulocytic leukemia	1
Sympathicoblastoma	1
Eosinophilic infiltration	1
Total	11

initiated, but she died 30 hours later. At postmortem examination no specific cause of death was found.

### Conclusions

The findings of this study indicate that supraclavicular and scalene lymph node biopsy is a worthwhile diagnostic procedure, but minor complications, such as bleeding at the time of biopsy or transient lymphorrhea, sometimes occur. The possibility, although slight, of the development of fatal air embolism at the time of skin incision for biopsy must also be considered.

Our findings that biopsies of palpable nodes in the supraclavicular area are more frequently positive than those of nonpalpable nodes in this area are similar to those of others.<sup>3-7</sup> Any palpable node in this region should be biopsied in cases of undiagnosed intrapulmonary disease or systemic illness.

In any diagnostic problem when all indicated studies have been inconclusive and no significant nodes are palpable, strong consideration should be given to biopsy of the deeper scalene nodes. If the initial biopsy is negative, contralateral biopsy should be considered. A positive biopsy, when correlated with the clinical picture, can often spare the patient prolonged diagnostic studies.

Biopsy should be done by experienced surgeons. On the right side, particular attention should be given to the node or nodes in the angle of the internal jugular and subclavian veins; and, on the left, to those nodes that are in the region of the thoracic duct and subclavian vein.

The high incidence of positive biopsies in this series is believed to result from the following factors: (1) the procedure was frequently incorporated with bronchoscopy, (2) patients were usually examined here relatively late in their disease after having been seen by other physicians or after having been in another diagnostic center, (3) repeated palpation of the supraclavicular area was performed by several observers, and (4) there was prompt biopsy of questionable lymph nodes in instances of diagnostic problems.

In the patients in whom the pattern of metastatic spread to lymph nodes conflicted with our knowledge of normal lymphatic anatomy, anomalous lymphatic channels or malignant obstructions with alternate lymphatic flow probably were present.

### Summary

In this series of 500 biopsies, findings were positive in 318 (98.3 percent) of the 323 from the supraclavicular (palpable) nodes and in 134 (75.7 percent) of the 177 from the scalene (nonpalpable) nodes. Complications consisting of bleeding and lymphorrhea were infrequent and self-limited, not prolonging convalescence. The procedure has been most helpful in the diagnosis of sarcoid, bronchogenic carcinoma and malignant lymphoma involving the lung parenchyma, hilar or mediastinal nodes. Positive biopsies of scalene nodes on the right side are usually the result of disease in the right lung and in the lower lobe of the left lung. Positive biopsies of scalene nodes on the left side may indicate disease in the left lung or below the diaphragm. It is recommended in any case of obscure disease that careful examination of the supraclavicular areas be done by at least one or possibly several examiners, and that any biopsy of this area be performed by an experienced surgeon.

### References

1. Daniels, A. C.: Method of biopsy useful in diagnosing certain intrathoracic diseases. *Dis. Chest.* 16: 360-367, 1949.
2. Harken, D. E.; Black, H.; Clauss, R., and Farrand, R. E.: Simple cervicomediastinal exploration for tissue diagnosis of intrathoracic diseases with comments on recognition of inoperable carcinoma of lung. *New England J. Med.* 251: 1041-1044, 1954.
3. Skinner, D. B.: Scalene-lymph-node biopsy. Reappraisal of risks and indications. *New England J. Med.* 268: 1324-1329, 1963.
4. Bansmer, G.; Lawrence, G. H., and Hill, L. D.: Scalene lymph node biopsy. *J. Thoracic Surg.* 37: 305-313, 1959.
5. Lal, S., and Poole, G. W.: Scalene-node biopsies. *Lancet* 2: 112-113, 1963.
6. Hellwig, C. A.; Dreese, W. C.; Welch, J. W., and McCusker, E. N.: How useful is biopsy of supraclavicular lymph nodes? *Surgery* 51: 592-596, 1962.
7. Beahrs, O. H.; Hunt, O. R., Jr.; Storsteen, O. M., and Bernatz, P. E.: Value of biopsy of lower deep jugular (scalene) nodes as diagnostic procedure. *Minnesota Med.* 40: 152-155, 1957.
8. Rouvière, H.: *Anatomy of Human Lymphatic System*. Translated by M. J. Tobias. Ann Arbor, Michigan: Edwards Brothers, Inc., 1938; 318 p.
9. Jackson, H., and Parker, F., Jr.: Hodgkin's disease; pathology. *New England J. Med.* 231: 35-44, 1944.
10. Skinner, D. B.: Scalene lymph node biopsy. *Hospital Med.* 1: 20-24, 1965.