

SPONTANEOUS PNEUMOPERITONEUM WITHOUT PERITONITIS

Report of a Case

JOHN P. PAPP, M.D.,* and B. H. SULLIVAN, JR., M.D.

Department of Gastroenterology

FREE air in the abdominal cavity is almost always evidence of perforation of a hollow viscus as the consequence of serious organic disease. Surgical intervention is often required. In rare instances, spontaneous pneumoperitoneum may appear without peritonitis and may be managed expectantly; laparotomy is undesirable and unnecessary. This report concerns such a case associated with aerophagia.

Report of a Case†

A 57-year-old woman was first examined at the Cleveland Clinic on January 22, 1965, because of severe intermittent abdominal pain for the preceding three months. For six years there had been episodes of abdominal distention, intestinal cramping, flatulence, constipation, and a retrosternal burning pain. Some relief of abdominal distention was obtained by belching or passing of flatus. Radiographic studies in 1960 were said to demonstrate a hiatus hernia and diverticula of the colon. On October 26, 1964, the patient underwent surgical repair of the hiatus hernia and obtained relief of the symptom of retrosternal burning. On the first postoperative day superficial thrombophlebitis of the right lower extremity developed, which responded to bed rest, elevation of the leg, and anticoagulants given orally. She was discharged from the hospital after 12 days, and did well at home except for intermittent episodes of cramping abdominal pain. On December 13, 1964, she was readmitted to the hospital because of severe colicky abdominal pain associated with pain in the left upper region of the chest and the shoulder. A roentgenogram of the abdomen demonstrated evidence of a large distended stomach and gas-filled large bowel and small bowel (Fig. 1). A roentgenogram made with the patient standing showed evidence of free air in the peritoneal cavity, and also elevation of the left diaphragm (Fig. 2). Prompt relief of these symptoms was obtained by the use of nasogastric suction. On January 11, 1965, she was readmitted to the hospital because of a recurrence of the colicky abdominal pain. She was afebrile. Roentgenographic studies did not demonstrate free air in the abdominal cavity at that time (Fig. 3). Roentgenograms of the upper gastrointestinal tract, the colon, and the gallbladder showed normal structures. She was discharged from the hospital, and at home she secured relief from abdominal distention and fullness by herself passing a tube into the stomach or into the rectum "to let out the gas." On January 21, 1965, she experienced some severe colicky pains in the left lower abdominal quadrant, abdominal distention, pain in the left shoulder, and difficulty in breathing.

Physical examination disclosed a 5 ft. 8 in. tall, moderately obese woman weighing 149 pounds. She was in mild distress, oriented, and cooperative. Her blood pressure was 130/70 mm. of Hg. The pulse rate was 80, and the temperature, 98 F. The head, eyes, ears, nose, mouth, neck, chest, and breasts were normal. A healed surgical scar was present in the left eighth intercostal space and in the right lower quadrant of the abdomen. A small umbilical hernia was present. On percussion of the abdomen, there was tympany, especially in the left upper quadrant. The abdomen was not tender. There were hyperactive bowel sounds without visible peristaltic waves. The remainder of the physical examination disclosed normal findings, except for superficial varicose veins of the lower extremities. An upright and left decubitus roentgenogram of the abdomen on January 26, 1965, demonstrated a large amount of free air in the abdominal cavity (Fig. 4). A roentgenogram after barium enema showed normal structures except for numerous diverticula of the left colon. A roentgenogram of the chest was interpreted as being normal, as was an electrocardiogram.

The laboratory test results were: blood hemoglobin, 11.7 gm. per 100 ml.; hematocrit read-

*Intern, Cleveland Clinic Hospital.

†The authors are indebted to Charles E. Staats, M.D., of Staats Hospital, Charleston, West Virginia, for permission to publish the roentgenograms in Figures 1, 2, and 3.

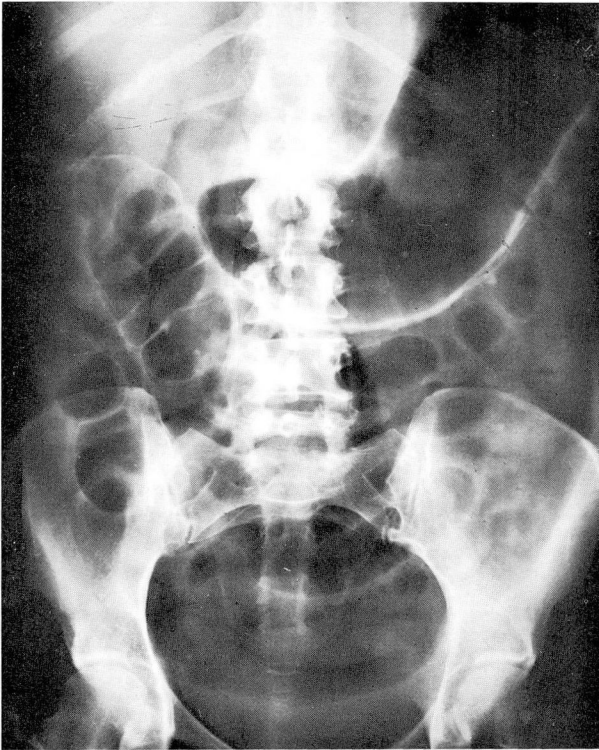


Fig. 1. Roentgenogram of the abdomen on December 13, 1964, with the patient supine. A large distended stomach and minimal distention of the large and small bowel are evident. (Courtesy of Charles E. Staats, M.D., Charleston, West Virginia.)

ing, 34 ml. per 100 ml.; leukocyte count, 5,000 per cubic millimeter; serum amylase value, 188 Somogyi units per 100 ml.; serum alkaline phosphatase, 12 King-Armstrong units; and gastric acidity, after Histalog stimulation, revealed 106 degrees of free hydrochloric acid. The urinalysis, determinations of blood urea, 3-hr. glucose tolerance test, sulfobromophthalein retention, fasting blood sugar, serum glutamic oxalacetic transaminase, and serologic and thymol turbidity tests were normal.

The patient was given 5-mg. doses of diazepam* three times daily while in the hospital. She was afebrile, had no abdominal pains, passed decreasing amounts of flatus, and had a soft abdomen that was not tender to palpation during the hospitalization. After five days of treatment, she was discharged from the hospital.

Discussion

Spontaneous pneumoperitoneum may occur as a result of air entering the peritoneal cavity by way of the female genital tract, the gastrointestinal tract, or the respiratory tract. Entrance through the female genital tract by way of the vagina, uterus, and patent fallopian tubes may occur after knee-chest postpartum exercises, the Rubin test,¹ or douching. Spontaneous pneumoperitoneum incident to air-

**Valium*, Roche Laboratories.

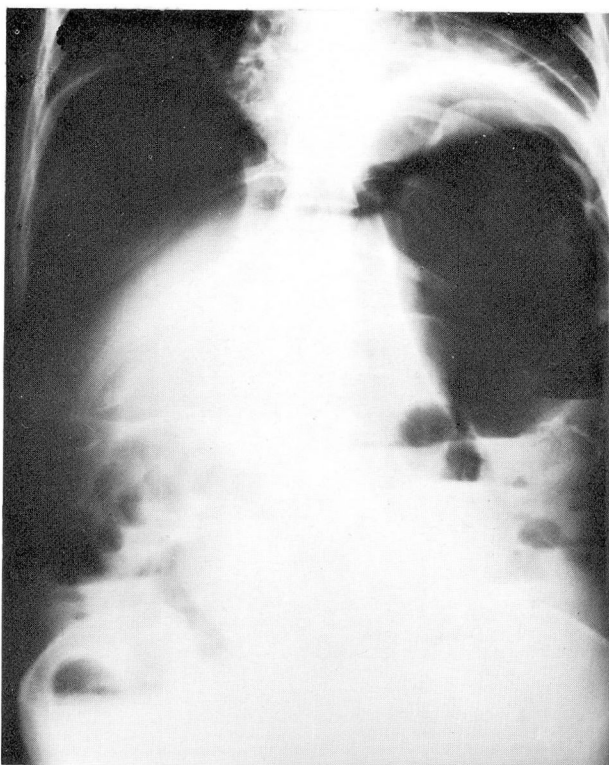


Fig. 2. Roentgenogram of the abdomen on December 13, 1964, with the patient standing. A large amount of free air in the peritoneal cavity is evident, associated with elevation of the diaphragm. Air-fluid levels are present in minimally distended large and small intestines. (Courtesy of Charles E. Staats, M.D., Charleston, West Virginia.)

contrast visualization of the colon,² gastroscopy,³⁻⁵ or as a complication of abnormal swallowing of air owing to relaxation of the esophageal sphincter or its destruction by operative procedures⁶ has been noted. Hinkel⁷ reported that spontaneous pneumoperitoneum occurred after rupture of an emphysematous bleb adjacent to the diaphragm.

Excluding surgically induced pneumoperitoneum, the most frequent cause is the perforation of some portion of the gastrointestinal tract as a result of disease or trauma. Duodenal and gastric ulcer perforations account for almost 90 percent of the recognized cases of pneumoperitoneum. Other causes are perforation of the colon in ulcerative colitis, rupture of a gangrenous appendix, perforation of a colonic diverticulum or of a Meckel's diverticulum, perforation of amebic, typhoid, or paratyphoid ulcers, or rupture of a viscus after trauma. Occasionally pneumoperitoneum without peritonitis may result from rupture of the blebs or cysts in pneumatosis cystoides intestinalis.

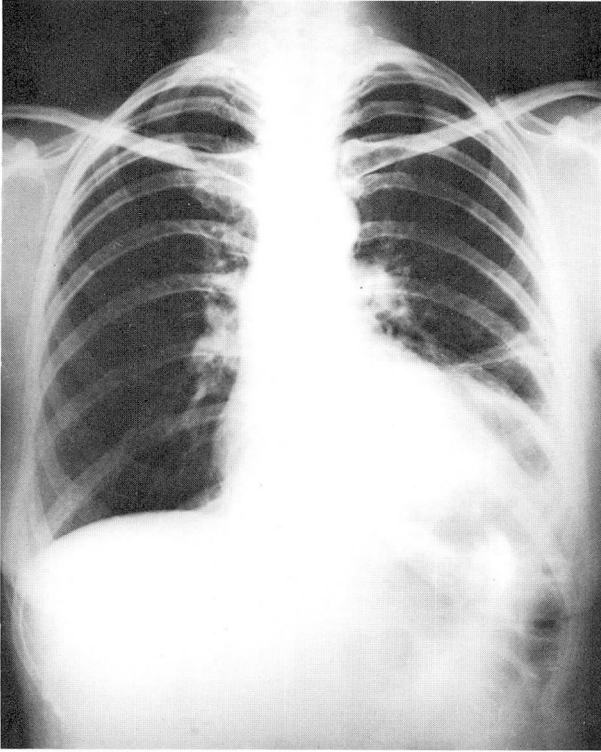


Fig. 3. A posteroanterior roentgenogram of the chest and upper abdomen on January 13, 1965, with the patient standing. No free peritoneal air is evident. Pleural reaction obscures the left lower lung and left hemidiaphragm. (Courtesy of Charles E. Staats, M.D., Charleston, West Virginia.)

More than 20 cases of pneumoperitoneum have been reported as occurring after gastroscopy. In a majority of the patients who underwent laparotomy there was no perforation of the gastric wall.^{4, 5} Myhre and Wilson⁸ performed routine roentgen examinations of 119 consecutive patients, after gastroscopy, and found no cases of pneumoperitoneum. Evidence suggestive of emphysema of the stomach wall was present in two patients. Chamberlin,⁹ Schindler,⁵ and Ylvisaker and Myhre¹⁰ reported that after gastroscopy, emphysematous blebs developed on the subserosal surface of the stomach, in the greater and lesser omentum, and in the gastrohepatic ligament. Chamberlin⁹ attributed the interstitial emphysema to the forcing of air into perineural and lymphatic vessels at the base of a gastric ulcer. He postulated that when the pressure in the subserosal blebs reached a maximum level, the blebs ruptured, resulting in pneumoperitoneum. In his patient, dilated lymphatic and perineural vessels were observed on microscopic examination of the base of the gastric ulcer.

It is well recognized that 'intestinal gas' represents air that enters the gastro-

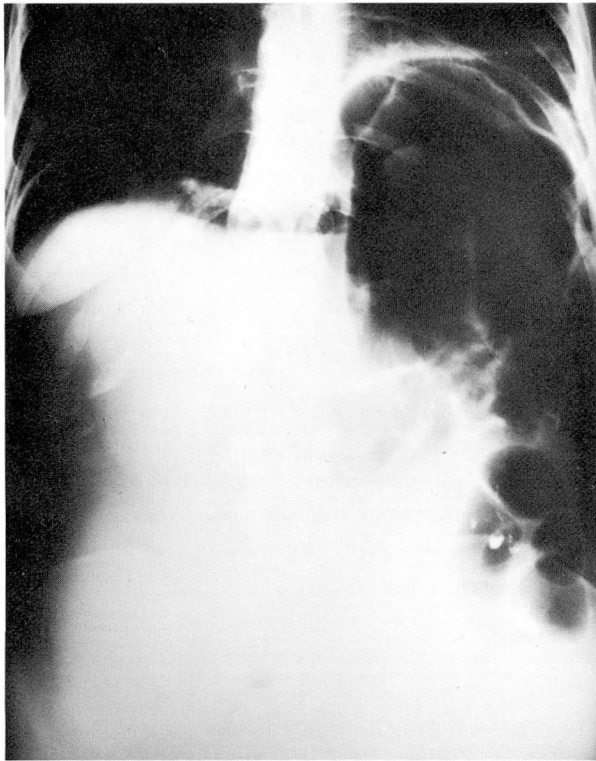


Fig. 4. Roentgenogram of the abdomen on January 26, 1965, with the patient standing. Recurrent pneumoperitoneum and distention of bowel are evident. Barium is seen in three sigmoid diverticula.

intestinal tract by way of the mouth. Aerophagia is seen as a common clinical problem. It does not often produce severe gastric distention, certainly not of sufficient magnitude to lead to pneumoperitoneum. Morris, Ivy, and Maddock¹¹ demonstrated that the superior esophageal sphincter (cricopharyngeal sphincter) normally is closed and prevents the entrance of air into the esophagus. The swallowing reflex opens this sphincter, and some patients are able to ingest air without food. If the superior esophageal sphincter is relaxed and the glottis closed, air may be sucked into the esophagus by inspiration, owing to negative intraesophageal and intragastric pressures. This mechanism is employed by persons who must utilize esophageal speech. It also may occur when a patient is under the effect of general anesthesia, particularly when surgical procedures are performed about the mouth and neck. Olsen and Foley⁶ reviewed three case reports from the recent literature and reported one case of their own in which gastric distention had become so great that it caused a rent on the anterior wall of the pars media of the stomach. The defect in the gastric wall was 1.5 cm., but the serosal tear was 3 cm. long.

Since laparotomy was not performed in the case we report, there can be no unequivocal statement as to the cause of the pneumoperitoneum. However, the evidence of a large, dilated, air-filled stomach and pneumoperitoneum on roentgenograms suggests that air may have extravasated through the gastric wall into the peritoneal cavity by a mechanism comparable to that occurring after gastroscopy. The patient had experienced swallowing of air for several years before undergoing operative repair of the hiatus hernia, but as far as we can ascertain, no episodes of pneumoperitoneum had occurred before last fall. The fact that two separate episodes of pneumoperitoneum without peritonitis occurred, and subsided spontaneously, supports our postulation that spontaneous pneumoperitoneum occurred in this patient as a result of aerophagia.

Summary

A case of spontaneous pneumoperitoneum apparently due to aerophagia is reported. There were two separate episodes of massive pneumoperitoneum, both of which subsided without treatment and with no evidence of peritonitis. Medical management was the treatment of choice and not surgical intervention.

References

1. Wright, A. R.: Case reports. Spontaneous pneumoperitoneum. *A.M.A. Arch. Surg.* 78: 500-502, 1959.
2. Brown, S., and Fine, A.: Diffuse emphysema following double contrast enema. *Radiology* 37: 228-229, 1941.
3. Schiff, L.; Stevens, R. J., and Goodman, S.: Case reports. Pneumoperitoneum following use of flexible gastroscope. *Ann. Int. Med.* 14: 1283-1287, 1941.
4. Gilbert, R. L.; Knight, W. A., Jr., and Dalton, A. R.: Case reports. Pneumoperitoneum following gastroscopy without demonstrable perforation at laparotomy. *Gastroenterology* 12: 139-141, 1949.
5. Schindler, R.: Passage of air through gastric wall during gastroscopy, with no wound demonstrable three hours later. *Gastroenterology* 5: 34-36, 1945.
6. Olsen, V. B., and Foley, T. J.: Air-sucker's gastric rupture syndrome. *Am. J. Surg.* 102: 602-606, 1961.
7. Hinkel, C. L.: Spontaneous pneumoperitoneum without demonstrable visceral perforation. *Am. J. Roentgenol.* 43: 377-382, 1940.
8. Myhre, J., and Wilson, J. A.: Study on occurrence of pneumoperitoneum after gastroscopy and observance of interstitial emphysema of stomach. *Gastroenterology* 11: 115-119, 1948.
9. Chamberlin, D. T.: Pneumoperitoneum following gastroscopy apparently without perforation; report of case. *New England J. Med.* 237: 843-845, 1947.
10. Ylvisaker, R. S., and Myhre, J.: Management of pneumoperitoneum after gastroscopy. *Gastroenterology* 18: 463-465, 1951.

11. Morris, C. R.; Ivy, A. C., and Maddock, W. G.: Mechanism of acute abdominal distention; some observations. *Arch. Surg.* 55: 101-124, 1947.