

BARIUM-SPRAY EXAMINATION OF THE STOMACH— PRELIMINARY REPORT OF A NEW ROENTGENOGRAPHIC TECHNIC

EDWARD BUONOCORE, M.D., and THOMAS F. MEANEY, M.D.

Department of Hospital Radiology

THE mainstay of the radiographic study of the upper gastrointestinal tract has been the abdominal roentgenograms after barium swallow. There are frequent occasions when the radiographic configuration of the stomach after barium swallow will not allow differentiation between a normal and a pathologic stomach. Newer diagnostic procedures have been developed to aid in diagnosing gastric lesions; these include gastroscopy, gastric cytologic examination, and angiography. The purpose of this report is to give the preliminary experience with another technic of gastric examination using barium spray.

The roentgenographic barium-spray examination of the stomach is a technic whereby roentgenograms of the abdomen are made after barium is nebulized into the stomach through a special tube, and a double-contrast study of the mucosa of the stomach is obtained. This procedure was used to examine 25 patients during this last year at the Cleveland Clinic Hospital. In each of four patients a pneumoperitoneum also was induced by the technic of Frimann-Dahl and Traetteberg¹ and a triple-contrast study of the stomach was made.

The need for additional roentgenographic study was most frequent in patients with suspected lesions in the fundus and cardia of the stomach. The inaccessibility of the gastric fundus to the roentgenologist's palpating hand and the absence of visible peristalsis in the proximal part of the stomach necessitate further diagnostic approaches for this region. Unfortunately the gastric fundus is also inapproachable by the present technic of gastroscopy. The wide variation in tone of the proximal part of the stomach among patients produces numerous distorted shapes, often making the normal stomach indistinguishable from malignant tumor infiltration. Hence a double-contrast method of examination of the fundus of the stomach, combined with inflation of the stomach, was the aim of developing the roentgenographic barium-spray technic.

In each case the barium-spray examination was used to supplement the conventional study (after barium swallow) when the latter suggested an abnormality but was not considered adequate to disclose fully the clinical problem.

Technic

A tube was devised* that would permit the examiner to put a nebulized spray of barium and gas into the stomach safely, readily, and without discomfort to the

*The authors were assisted in developing and making the barium-spray tube by the Marlen Manufacturing Company, Bedford, Ohio.

patient. The sprayer is a small tube within a larger outer tube (Fig. 1A and B). The barium is slowly injected into the outer tube by hand while a jet of compressed carbon dioxide is introduced into the inner tube at a rate of 7 l. per minute. The

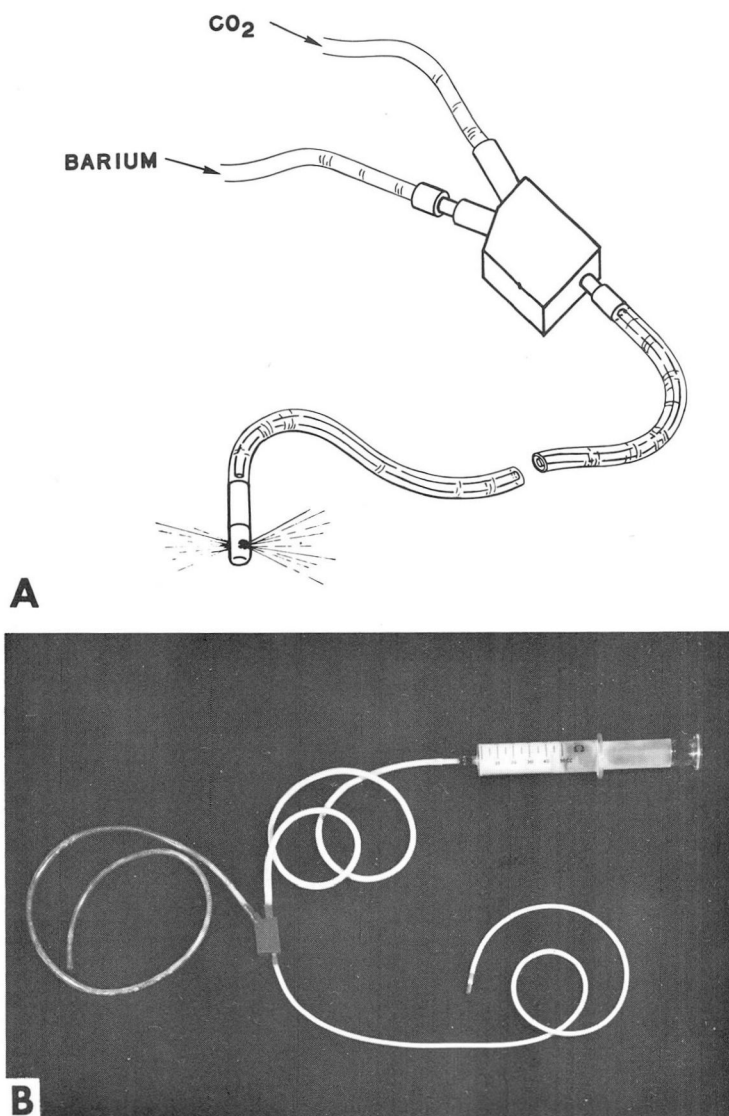


Fig. 1. A, Diagrammatic sketch of the tube used for barium spray. Small tube is within a large outer tube sealed at its distal end except for two small perforations. Barium is injected into the outer tube by hand while carbon dioxide flows through the inner tube at a rate of 7 l. per minute, 'blowing' out the barium and producing a fine spray. B, Photograph of the barium-spray tube.

distal end of the tube is closed, except for two small perforations. The flow of compressed carbon dioxide acts to propel the barium through the orifices producing a fine spray.

During the spraying procedure, spot and survey roentgenograms are made in multiple oblique, lateral, and frontal views. Pneumoperitoneum was induced by injecting approximately 2 l. of carbon dioxide into the abdominal cavity through a long 20-gauge needle placed percutaneously into the peritoneum in the left lower quadrant of the abdomen.

Twenty-five patients were examined with the barium-spray technic after the conventional barium-swallow examination suggested an abnormal configuration of the stomach and further diagnostic study was required.

Results

The barium-spray examinations were normal in 18 of the 25 patients examined despite the fact that the conventional barium-swallow studies suggested abnormal changes. Reasons for the apparent abnormality on conventional roentgenograms after barium swallow are listed in *Table 1*.

Table 1.—*Findings on conventional barium-swallow roentgenograms which suggested lesions; findings on barium-spray studies were normal*

Conventional roentgenograms	Number of patients
Unusual shape of the fundus presumed to be due to incomplete filling	9
Stomach deformed because of extrinsic pressure	5
Caused by colon	3
Caused by spleen	2
Large gastric folds	3
Suspected gastric ulcer	1
Total	18

In seven patients the barium-spray studies did show pathologic changes as listed in *Table 2*.

The following representative case material illustrates the technic and its value.

Normal stomach. *Figure 2A* is an anteroposterior conventional roentgenogram, after barium swallow, of a 70-year-old woman with nonspecific intestinal symptoms. Irregularity of the cardia and fundus of the stomach was seen on several roentgenograms, raising the suspicion of carcinoma. *Figure 2B, C, and D* show roentgenograms of the stomach after barium spray was used; a normal gastric fundus is outlined. A normal contour of the stomach is demonstrated, and normal gastric folds are well

Table 2.—*Abnormalities disclosed by barium-spray studies of seven patients with suggestive changes on roentgenograms after barium swallow*

Pathologic change	Number of patients
Gastric carcinoma	2
Polypoid	1
Infiltrating	1
Gastric and esophageal varices	2
Gastritis, cobblestone mucosal pattern (confirmed by gastroscopy and operation)	2
Gastric ulcer	1
Total	7

outlined by the double-contrast technic. An eight-month progress physical examination indicated that the patient's normal status was unchanged.

Gastritis. Figure 3A is a roentgenogram of the abdomen, after barium swallow, of a 77-year-old man who had abdominal cramps, anorexia, and weight loss. Gastroscopy revealed pale elevated mucosa along the mid greater curvature of the stomach. Gastric cytologic analysis was negative. Because of the irregularity of the greater curvature a triple-contrast study was performed. Figure 3B is a view of the mid portion of the stomach after barium spray was used and induction of pneumoperitoneum. Figure 3C is an additional triple-contrast roentgenogram outlining the wall of the greater curvature of the stomach. The mucosa is well delineated and suggests the cobblestone appearance of gastritis. The thickness of the gastric wall is well demonstrated and is normal, with no areas of unusual thickening.

Carcinoma in the gastric cardia and fundus. Figure 4 is a roentgenogram of the abdomen, after barium swallow, of a 69-year-old woman who had weight loss and abdominal pain; the gastric fundus is abnormal. Gastric cytologic analysis revealed dysplastic cells that were suspicious but not diagnostic. The roentgenograms after barium spray (Fig. 4B and C) clearly demonstrate a large exophytic tumor occupying the gastric cardia and fundus, which was found to be an adenocarcinoma at operation.

Gastric and esophageal varices. Figure 5A and B are abdominal roentgenograms, after using the barium spray, of a 71-year-old man. The use of the double-contrast spray technic of the esophagus and stomach demonstrates varices. The gastric varices are quite prominent, and a gastric neoplasm was suspected on the prior examination, after barium swallow, performed at the referring hospital. In this patient the roentgenogram, after using the barium spray, demonstrates the pliability of the stomach and unquestionably outlines the large varices in double contrast, with no evidence of tumor which was confirmed at operation.

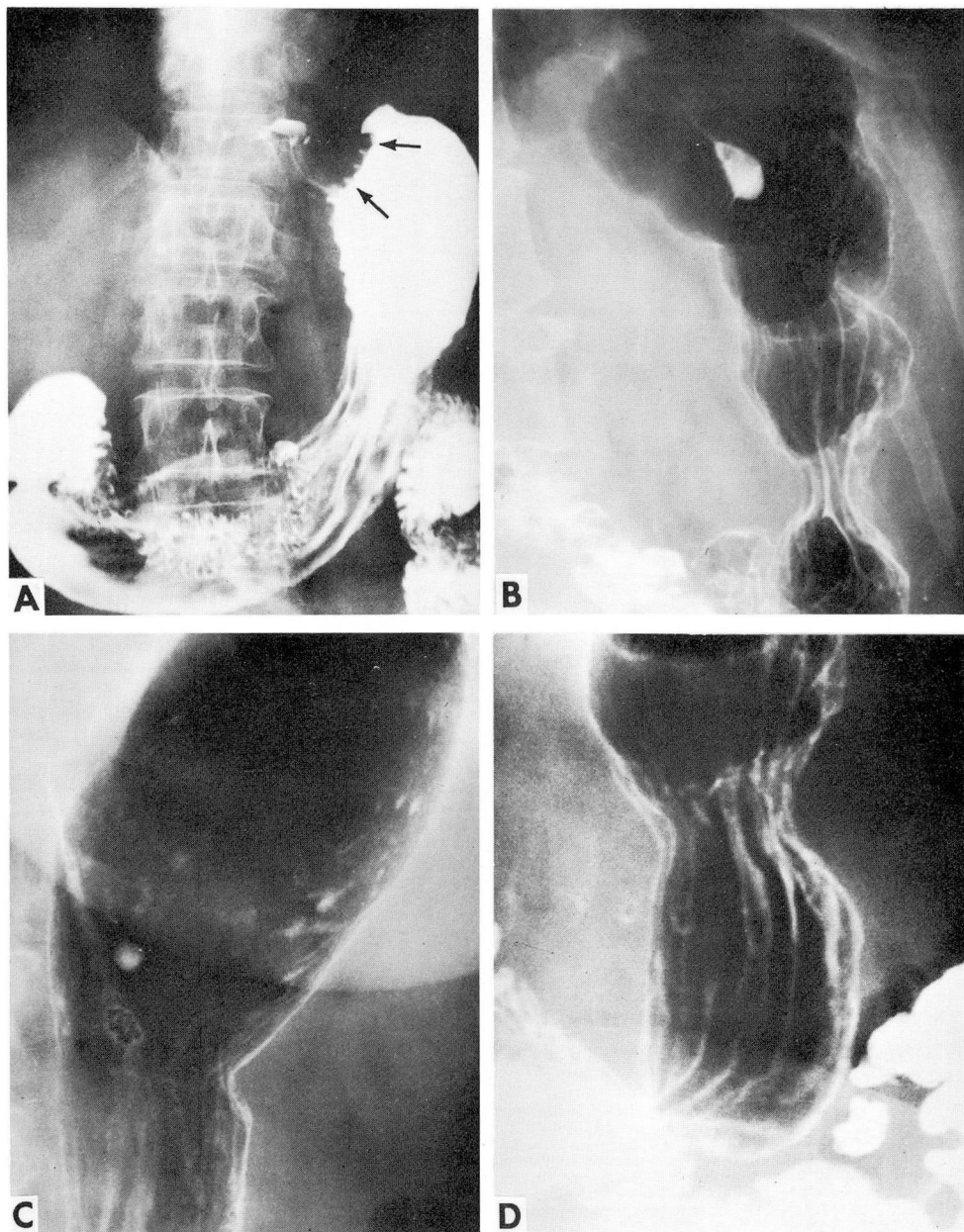


Fig. 2. A, Anteroposterior roentgenograms, after conventional barium swallow, showing a suspicious deformity (arrows) in the cardia and fundus of the stomach. B, Barium-spray study of the stomach, showing a normal mucosal pattern with no evidence of tumor. C, Spot view of fundus shows no deformity. D, Spray study of the body of the stomach showing normal mucosal pattern in double contrast.

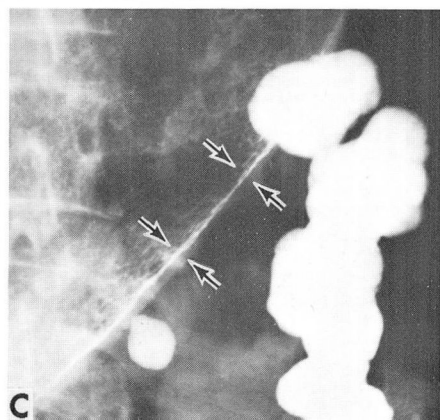
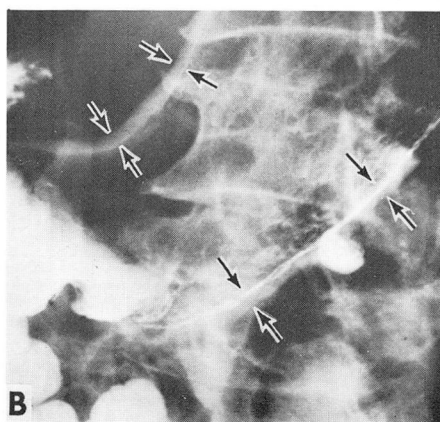
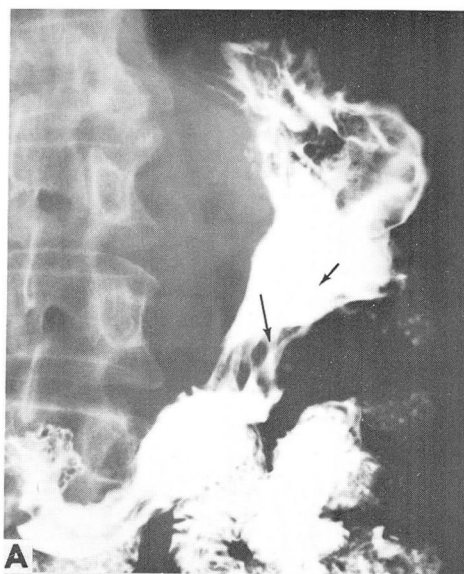


Fig. 3. A, Roentgenogram, after conventional barium swallow, showing suspicious deformity (arrows) along the greater curvature. B and C, The triple-contrast study of the stomach (barium spray combined with pneumoperitoneum). B, Normal thickness of the wall of the body of the stomach is delineated by arrows. C, Selective view of the wall of the greater curvature of the stomach, showing the cobblestone appearance of gastritis, but no evidence of infiltrating tumor.

Discussion

The aim of double-contrast roentgenographic examination of the gastrointestinal tract is to provide a basis for evaluating small mucosal abnormalities that ordinarily might be obscured by the barium but which are set into relief by the gas and barium. The air-contrast examination is a standard part of the roentgenographic

study of the large bowel, particularly the left side of the colon.² It certainly would be of value to be able readily to achieve a similar selective roentgenographic study

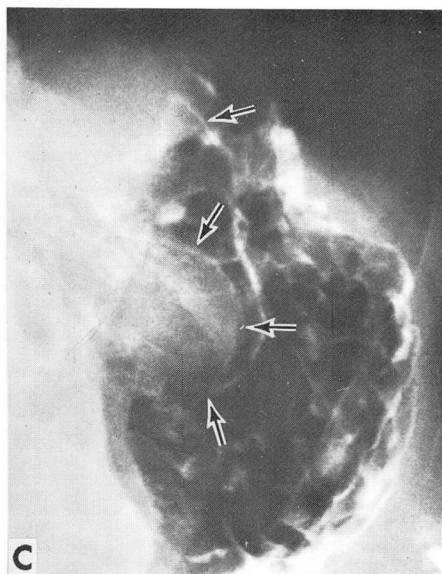
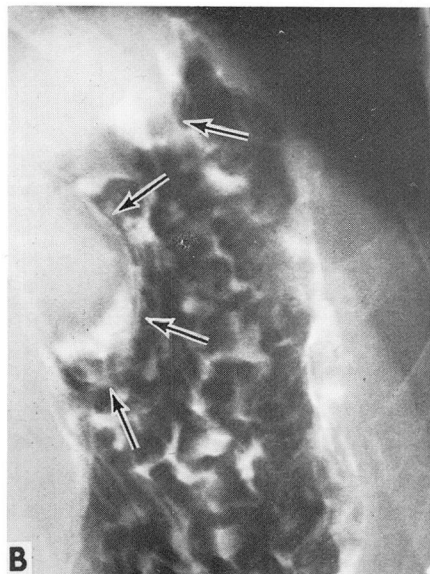
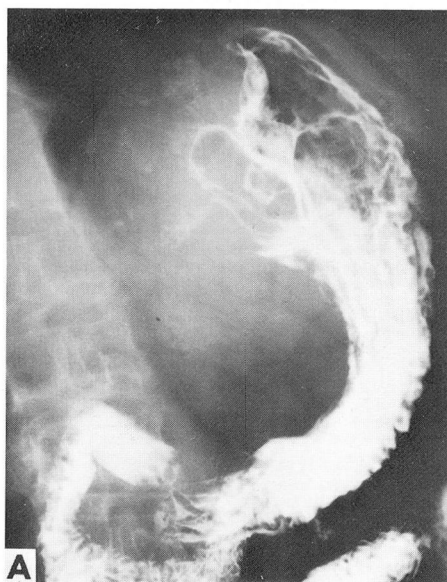


Fig. 4. A, Roentgenogram, after conventional barium swallow, showing an abnormal gastric fundus. B and C, Barium spray of the gastric fundus has outlined an air-contrast view of a large exophytic gastric neoplasm (arrows) that was found to be an adenocarcinoma at operation.

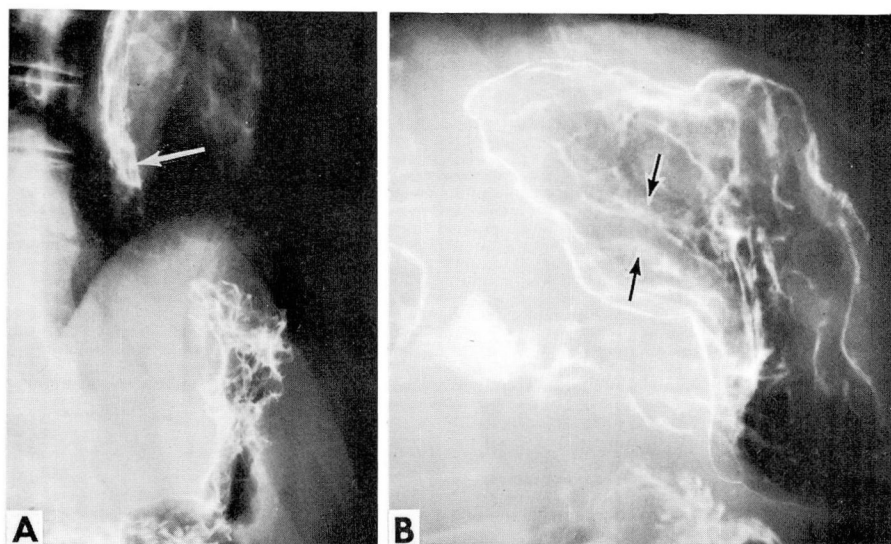


Fig. 5. A and B, Air-barium spray study reveals large varices of the esophagus (white arrow) and stomach (black arrows), which were confirmed at operation.

of any portion of the esophagus, stomach, small intestine, or cecum. It was with this purpose in view that the spray technic was devised.

The inaccessibility of the fundus of the stomach and its numerous irregular configurations, owing in part to its location above the cardioesophageal junction, makes it an ideal region to be examined by the air-contrast technic.

Other methods of double-contrast examinations of the proximal part of the stomach have been attempted using Seidlitz powders and rapid changing of the patient from the supine to the erect position. These technics have not given consistently good results, and lack the ability to control the optimum amount of gas-barium mixture for evaluation of the pliability of the wall of the stomach.

The standard gastrointestinal examination after barium swallow also does not allow distinction between the various portions of the wall of the stomach and does not permit determination of thickness of the gastric wall. Recent work using angiography of the celiac axis after augmented histamine injection, pneumoperitoneum, and gas insufflation of the stomach, has attempted to remedy this deficiency of the gastrointestinal examination by producing a triple-contrast view of the wall of the stomach.³ When indicated, pneumoperitoneum may be used along with barium spraying of the stomach and will clearly delineate the gastric wall thickness on roentgenograms, and at the same time highlight the mucosal detail of the stomach. It is anticipated that the barium-spray technic will be most valuable in detecting exophytic and polypoid lesions. The combined pneumoperitoneum with spray should be most useful in evaluating infiltrating tumors of the gastro-

intestinal tract. Induction of pneumoperitoneum is not without hazard and should be reserved for selected cases.

Work is now in progress to develop a longer tube of a similar type so that selective double-contrast roentgenograms may be obtained in any portion of the gastrointestinal tract, particularly the small intestine or the cecum. The standard roentgenograms of the maze of the small bowel filled with barium quite often fail to reveal a tumor until obstruction has occurred. Segment-by-segment evaluation of the small intestine by the spray technic may be possible and be of assistance in further diagnosis of small-bowel tumors.

The barium-spray examination of the stomach has been safe and readily performed in all patients—outpatients as well as inpatients—without complication or undue discomfort.

Summary

A new technic of examination of the stomach is described using nebulized barium sprayed into the stomach through a specially devised tube. Barium-spray studies were used in 25 patients who had suggestive abnormalities on roentgenograms after conventional barium swallow. In 18 patients the barium-spray studies were found to be normal, and in each of 7 patients a gastric lesion was confirmed.

The induction of a pneumoperitoneum in each of four patients proved of value to measure the thickness of the gastric wall. In the 25 patients examined the barium-spray technic was of value to supplement the conventional barium-swallow examination in problem cases.

References

1. Frimann-Dahl, J., and Traetteberg, K.: Parietography of stomach. *Brit. J. Radiol.* 35: 249-254, 1962.
2. Welin, S.; Youker, J., and Spratt, J. S., Jr.: Rates and patterns of growth of 375 tumors of large intestine and rectum observed serially by double contrast enema study (Malmö technique). *Am. J. Roentgenol.* 90: 673-687, 1963.
3. Taylor, D. A.; Macken, K. L.; Bachman, A. L., and Seaman, W. B.: New method for visualization of gastric wall: preliminary report. *Radiology* 84: 351-353, 1965.