

POSTGASTRECTOMY ARTERIOVENOUS FISTULA OF THE GASTRODUODENAL VESSELS

Report of a Case

LAWRENCE B. LANGSAM, M.D.,* and ROBERT E. HERMANN, M.D.

Department of General Surgery

ARTERIOVENOUS fistulas occur as congenital lesions, as acquired lesions after penetrating injuries, as a result of the erosion of aneurysms into the accompanying vein, or as a complication of venipunctures or surgical procedures. A wide variety of the latter, from thyroidectomy to hysterectomy, have been reported to have resulted in arteriovenous fistula. So far as we can determine, however, there has been only one previous report of an arteriovenous fistula as a complication of gastrectomy: Reams¹ described a fistula that developed between the middle colic artery and vein. The purpose of our paper is to report the development of a fistula, after gastric resection, between a branch of the gastroduodenal artery and vein, a fistula previously unreported as a complication of subtotal gastrectomy.

Report of a Case

A 48-year-old white man was admitted to the Cleveland Clinic Hospital on November 8, 1963.† The patient had consulted his physician in March, 1963, because of an aching sensation in the right upper quadrant of the abdomen, and a murmur was heard in this area. In October, 1963, at another hospital, an intravenous aortogram revealed the presence of an abnormally dilated vessel in the region of the right renal artery. It was believed that this represented a fistula between one of the renal arteries and the renal vein. Significant in the patient's history was the fact that in June, 1960, he had undergone a subtotal gastric resection with gastrojejunal anastomosis, for two gastric ulcers.

On physical examination, the patient's temperature was normal; his pulse was 80 (regular); and the blood pressure was 124/70 mm. of Hg. The only significant abnormal finding was that of a loud, continuous, high-pitched murmur in the right upper quadrant of the abdomen. Results of all laboratory tests were normal. The chest roentgenogram showed normal structures.

Translumbar renal angiography was performed, and revealed three renal arteries supplying the right kidney and two supplying the left. The contrast-medium-filled structure evident on the previous transvenous study was not seen, indicating that it probably did not take its origin from the renal arteries or from the aorta below. Selective celiac angiography‡ was then performed via a catheter introduced through the left femoral artery. The hepatic and gastroduodenal arteries were found to be abnormally large. The gastroduodenal artery was tortuous and elongated, overlying the hilus of the right kidney; contrast medium was seen to flow promptly into a dilated vascular structure to the right of the midline and then to empty into the portal vein (Fig. 1).

On November 13, 1963, laparotomy was performed and an arteriovenous fistula was found in the region of the closed duodenal bulb, immediately beneath the liver. The involved artery was a branch of the gastroduodenal artery; the vein was the accompanying vein that returned the blood flow into the portal venous system. The other intraabdominal organs were normal. The artery and vein involved in the fistula were dissected out, divided, and separately ligated; the fistula was removed (Fig. 1). The patient made an uneventful recovery and was discharged from the hospital on the seventh postoperative day.

*Fellow in the Department of General Surgery.

†The patient was referred to Eugene F. Poutasse, M.D., formerly member of the staff; present address: 801 Medical Tower, Norfolk, Virginia.

‡Angiography was performed by Thomas F. Meaney, M.D., of the Department of Hospital Radiology.

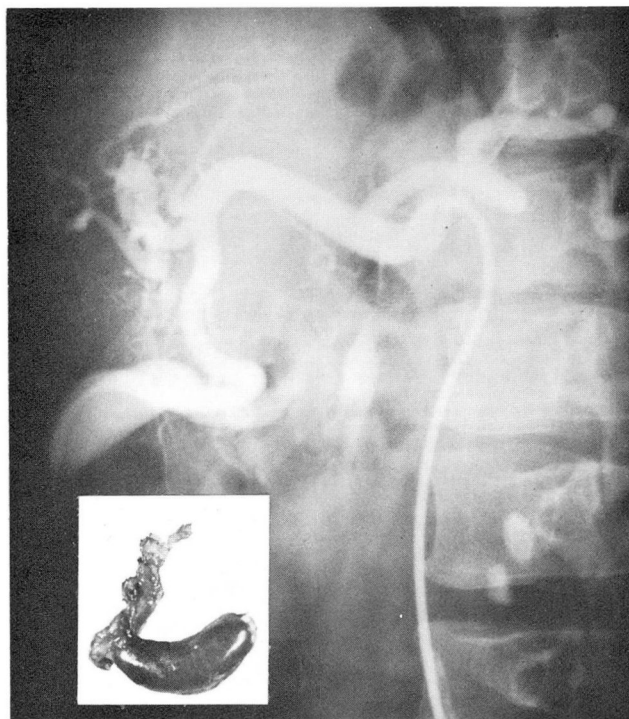


Fig. 1. This montage shows the selective celiac angiogram with a photograph of the resected arteriovenous fistula superimposed. The catheter is seen in the orifice of the celiac axis, and contrast material outlines the hepatic and gastroduodenal arteries. The arteriovenous fistula and dilated gastroduodenal vein are visualized. Later sequential angiograms demonstrated the portal vein.

Discussion

An arteriovenous fistula was accurately described by Hunter in 1757, when he noted an abnormal communication between an artery and a vein after an attempted venipuncture.^{2,3} Since then it has been recognized that arteriovenous fistulas can result from various causes. Arteriovenous fistulas after surgical procedures are being reported more frequently, because of greater awareness by clinicians, and improved technics of diagnosis. Munnell, Mota, and Thompson³ reviewed the literature and found 47 arteriovenous fistulas reported as a result of surgical procedures; to date the total is 63 cases reported (*Table 1*).

It is reasonable to conclude that any concomitant injury to an adjoining artery and vein may give rise to an arteriovenous fistula. Most authors have implicated mass ligatures (especially transfixion sutures) of vascular pedicles as the causative factor in producing these postoperative complications.^{3-5, 13} In regard to the case reported here, we believe that the fistula may have resulted from ligatures placed

Table 1.—*Surgical and medical procedures reported to have resulted in 63 postoperative arteriovenous fistulas*

Procedures	Number of cases
Intervertebral disc excision ⁸	22
Nephrectomy ^{6,7}	9
Thyroidectomy ^{3,5}	7
Amputation ³	2
Arthrodesis ³	2
Orthopedic pin insertion ³	2
Hysterectomy ³	2
Splenectomy ¹¹	1
Intestinal resection ³	1
Gastrectomy ¹	1
Nephrolithotomy ⁶	1
Venipuncture ³	7
Diagnostic procedures ³	3
Others ³	3
Total	63

at the time of the prior gastrectomy. Gitlitz and associates,⁶ in a recent review of postnephrectomy arteriovenous fistulas, have questioned the role of an additional factor, that of preexisting or postoperative infection in the development of such fistulas. Infection was present in five of the nine cases they reviewed.

Since mass ligatures and transfixion sutures are so frequently used in surgery, it is obvious that arteriovenous fistula is a rare complication of these technics. The fact that this complication can sometimes occur is a reason for reemphasizing the surgical technic of small vascular pedicles, individually ligating arteries and veins whenever they are of significant size.

The presence of an arteriovenous fistula is most often suspected on the basis of the murmur, a continuous bruit with a systolic accentuation. Systemic signs depend largely upon the size of the fistula and the amount of blood that passes through it, its location in the arterial tree (central versus peripheral) and upon the extent of obstructed runoff that may exist in the vein leading away from the fistula. Systemic physical findings include an increased venous pressure and an increased pulse rate; cardiac hypertrophy and dilatation develop secondary to the increased venous return to the heart. A diagnostic sign, referred to as Branham's sign, described by Nicoladoni in 1875,^{2,10} is the rise in diastolic blood pressure and the decrease in pulse rate, which can be demonstrated in areas where the fistula can be compressed

manually and obliterated. When the forced increase in cardiac output exists over a sufficiently long period, it leads to congestive heart failure.⁷ Spittell and associates⁸ reported cardiac failure in two thirds of 22 patients with large arteriovenous fistulas that were complications of lumbar disc surgery. Bacterial endarteritis has also occurred in large arteriovenous fistulas.⁹

Arteriography has become an indispensable tool in the diagnosis and accurate location of arteriovenous fistulas. The case we have reported is one of the few in which selective celiac or mesenteric arteriography was performed, and points out its superiority over conventional aortography in accurately establishing the location and anatomy of intraabdominal arteriovenous fistulas.

Surgical ligation or excision of the arteriovenous fistula is the preferred treatment, and should be performed before the development of systemic cardiovascular complications. When a postoperative fistula develops between vessels that supplied an organ before its removal, simple excision may be performed.¹¹⁻¹³ In other cases, particularly when fistulas occur after lumbar disc surgery, the aorta and inferior vena cava or the iliac arteries and veins may be involved. Vascular repair or prosthetic graft replacement may be necessary in the closure of these fistulas.

Summary

A case of postgastrectomy arteriovenous fistula of the gastroduodenal vessels is reported. The cause, diagnosis, complications, and treatment of postsurgical arteriovenous fistulas are discussed. Although fortunately rare as a complication of surgical procedures, arteriovenous fistulas may now be accurately diagnosed and defined with the aid of selective arteriography. Surgical ligation or excision of the fistula should be undertaken whenever possible, before the onset of systemic cardiovascular symptoms.

References

1. Reams, G. B.: Middle colic arteriovenous fistula developing as postgastrectomy complication. *A.M.A. Arch. Surg.* 81: 757-760, 1960.
2. Allen, E. V.; Barker, N. W., and Hines, E. A., Jr.: *Peripheral Vascular Diseases*, 3d ed. Philadelphia: W. B. Saunders Company, 1962, 1044 p.; p. 475-492.
3. Munnell, E. R.; Mota, C. R., and Thompson, W. B.: Iatrogenic arteriovenous fistula: report of case involving superior mesenteric vessels. *Am. Surgeon* 26: 738-744, 1960.
4. Elkin, D. C.: Aneurysm following surgical procedures; report of five cases. *Ann. Surg.* 127: 769-779, 1948.
5. Beattie, W. M.; Oldham, J. B., and Ross, J. A.: Superior thyroid arteriovenous aneurysm. *Brit. J. Surg.* 48: 456-457, 1961.
6. Gitlitz, G. F.; Fell, S. C.; Sagerman, R. H., and Hurwitt, E. S.: Post-nephrectomy arteriovenous fistula: case report and review of literature. *Ann. Surg.* 157: 511-515, 1963.

7. Shirey, E. K.: Cardiac disease secondary to postnephrectomy arteriovenous fistula; report of case. *Cleveland Clin. Quart.* **26**: 188-200, 1959.
8. Spittell, J. A., Jr.; Palumbo, P. J.; Love, J. G., and Ellis, F. H., Jr.: Arteriovenous fistula complicating lumbar-disk surgery. *New England J. Med.* **268**: 1162-1165, 1963.
9. Hook, E. W., Jr.; Wainer, H. S.; McGee, T. J., and Sellers, T. F., Jr.: Acquired arteriovenous fistula with bacterial endarteritis and endocarditis. *J.A.M.A.* **164**: 1450-1454, 1957.
10. Durham, M. W.; Robnett, A. H.; Harper, H. P., and Yekel, R.: Arteriovenous fistula of mesenteric vessels. *West. J. Surg.* **70**: 9-11, 1962.
11. Buchholz, R. R.: Arteriovenous fistula of splenic vessels: report of case following splenectomy. *Ann. Surg.* **149**: 590-592, 1959.
12. Elkin, D. C., and Banner, E. A.: Arteriovenous aneurysm following surgical operations. *J.A.M.A.* **131**: 1117-1119, 1946.
13. Poutasse, E. F.: Renal artery aneurysm: report of 12 cases, two treated by excision of aneurysm and repair of renal artery. *J. Urol.* **77**: 697-708, 1957.