

NON-BETA ISLET-CELL CARCINOMA OF THE PANCREAS, WITH FLUSHING ATTACKS AND DIARRHEA

Report of a Case

WILLIAM H. SHAFER, M.D.,

Department of General Internal Medicine

LAWRENCE J. McCORMACK, M.D.,

Department of Anatomic Pathology

and

STANLEY O. HOERR, M.D.

Department of General Surgery

RECURRENT attacks of generalized flushing and hyperperistalsis are unusual manifestations of non-beta islet-cell tumor of the pancreas.¹ Our report concerns a patient who had severe peptic ulcer disease, and recurrent attacks of flushing and diarrhea associated with a non-beta islet-cell carcinoma of the pancreas.

Report of a Case

A 63-year-old man was examined at the Cleveland Clinic in May, 1962, because of attacks of flushing, back pain, and diarrhea. In 1958 he noted the onset of recurrent flushing attacks that would last for from a few minutes to several hours. With mild attacks the flushing would involve mainly the face, and with severe episodes the entire body. The frequency of these attacks varied considerably, with apparently no definite precipitating cause. Associated with the flushing attacks were borborygmi, cramping lower abdominal pain, back and leg pain, followed by three or four loose, watery bowel movements. In 1960 he was admitted to a hospital and underwent an exploratory laparotomy; metastatic nodules were found in the liver; the pathologic diagnosis was probable carcinoid tumor, metastatic in the liver. Argentaffin stains of the nodules were negative, but the general appearance of the neoplastic cells and their grouping were suggestive of a poorly differentiated carcinoid tumor. A urinalysis for 5-hydroxyindoleacetic acid was normal. In May, 1961, he underwent an exploratory laparotomy and plication of a perforated duodenal ulcer. In November, 1961, he was readmitted to a hospital because of upper gastrointestinal bleeding probably due to active duodenal ulcer.

The physical examination at the Cleveland Clinic disclosed no abnormality except the well-healed surgical scars. During the examination the patient had low back and leg pain, and shortly thereafter a generalized flushing attack occurred, with blotchy erythematous skin changes together with an increase in pulse rate from 88 to 113, and hyperactive bowel sounds. The flushing episode lasted about ten minutes.

The patient was admitted to the Cleveland Clinic Hospital for further studies. The blood hemoglobin content was 13.5 gm. per 100 ml., and a hematocrit reading was 42 percent. The standard urinalysis was normal. A fasting blood sugar determination, serologic tests, and serum determinations of sodium, potassium, chloride, carbon dioxide content, calcium, and phosphorus, were normal. A qualitative urinalysis for 5-hydroxyindoleacetic acid, serotonin, and 5-hydroxytryptophan was negative. A 24-hr. urine specimen showed no increased amounts of 5-hydroxyindoleacetic acid; another 24-hr. specimen after administration of 1 gm. of l-tryptophan showed little change from the previous pattern.

Roentgenograms of the chest and an intravenous urogram showed normal function. A roentgen survey of the upper and lower extremities, skull, and pelvis, showed evidence of lesions consistent with metastatic tumor in the right humerus, pubis, left femoral shaft, and the calvarium; the esophagus, stomach, and duodenum were normal; the colon showed only spasm.

The attacks of low back pain radiating into the legs, along with generalized flushing continued to recur. An attempt was made to induce flushing attacks. Intravenous injections of 2,

5, and 10 μ g. of epinephrine were given, but they produced only normal responses, as did also similar doses of isopropyl noradrenalin. The patient also complained of recurrent midabdominal pain. An episode of melena occurred and another roentgen study of the stomach showed a large penetrating ulcer several centimeters in diameter on the greater curvature of the antrum, and some irregularity of the duodenal bulb.

In view of the negative studies for a functioning carcinoid tumor, and the severe ulcer diathesis, the presence of a pancreatic islet-cell tumor with the Zollinger-Ellison syndrome was suspected. A 12-hour aspiration of the stomach yielded 1,320 ml. of gastric secretion. An exploratory laparotomy was undertaken, and a large penetrating ulcer was found two inches proximal to the pylorus. There were two small nodules in the liver, but no other evidence of metastatic disease; the nodules were removed for assay. Since the ulcer was in the stomach and the proof of a Zollinger-Ellison syndrome still lacking, a 60 percent resection of the distal portion of the stomach with a gastroduodenal anastomosis was performed. The patient had an uneventful postoperative course with relief of the abdominal pain, but mild flushing and back pain continued to recur.

The ulcer was benign by pathologic examination. The metastatic nodules showed an epithelial lesion, and the differential diagnosis was between islet-cell tumor of the pancreas, and carcinoid tumor. Argentaffin stains were negative. A fluorometric assay revealed 5 μ g. of serotonin per gram of neoplastic tissue, an amount slightly higher than that in normal tissue, but not nearly the concentration usually found in carcinoid tissue. The neoplastic tissue contained amine oxidase but did not have increased amounts of 5-hydroxytryptophan decarboxylase, and was not capable of hydroxylating tryptophan. It was thought that the biochemical data did not represent a carcinoid syndrome. A specimen of tissue submitted for gastrin assay was too small for analysis.*

After the patient was discharged from the hospital the attacks of flushing, diarrhea, abdominal cramps, and back pain became frequent. Abdominal pain usually but not always appeared with the flushing attacks. In addition, nocturnal abdominal pain (relieved by antacids) occurred. A roentgenogram of the stomach was thought to demonstrate a small marginal ulcer. Gastric analysis showed 46 units of free hydrochloric acid. Despite a strict ulcer program the symptoms progressed in severity.

The patient was readmitted to the Cleveland Clinic Hospital for a reexploratory operation and possible total gastrectomy. At operation no evidence of anastomotic ulcer was found. A thorough search disclosed no other evidence of gastric or duodenal peptic ulcer. A tiny metastatic lesion was removed from the liver. The pancreas was somewhat nodular, and a portion of the tail was removed. Since there was no evidence of recurrent ulcer a total gastrectomy was not done, but instead, a vagal transection and a conversion of the gastroduodenostomy (Billroth I) to a gastrojejunostomy (Billroth II) were carried out.

Grossly, the excised pancreas was found to contain three ill-defined nodules, each approximately 0.3 cm. in diameter. Microscopically, there could be recognized two types of lesions. One encompassed small irregular foci scattered indiscriminately throughout the gland; each of these foci consisted of cords and islands of unorganized cells that incited an intense, fibrotic reaction (Fig. 1). Individual cells were moderate in size, possessed sparse cytoplasm and nuclei containing irregular chromatin masses; occasional mitoses were noted. These cords of cells could be seen infiltrating the perineural lymphatics and peripancreatic fat in addition. Islands of similar cells could be demonstrated in the liver and in the splenic sinusoids. In contrast, occasional masses were much more reminiscent of islets of Langerhans (Fig. 2). They were round to oval. The individual cell while resembling the others formed anastomosing cords and showed peripheral margination as seen in islet-cell tumors. The incited fibroplasia was sparse in these areas. The entire lesion was interpreted as a metastasizing, non-beta islet-cell carcinoma in association with islet-cell adenomatosis of the pancreas.

The patient made an uneventful recovery; however, there has been recurrence of symptoms of flushing, abdominal cramping, diarrhea, back and leg pain. Chlorpromazine, 25 mg. four times daily, has seemed to decrease severity of these attacks. Repeated determinations of urinary excretion of 5-hydroxyindoleacetic acid, serotonin, and 5-hydroxytryptophan while the patient was receiving no medication, as well as histamine content in two 24-hr. urine specimens have been normal.†

*William M. McIsaac, M.B., B.S., Ph.D., of the Division of Research, performed the biochemical studies.

†Neville Crawford, M.D., of the Division of Research, performed the determinations.

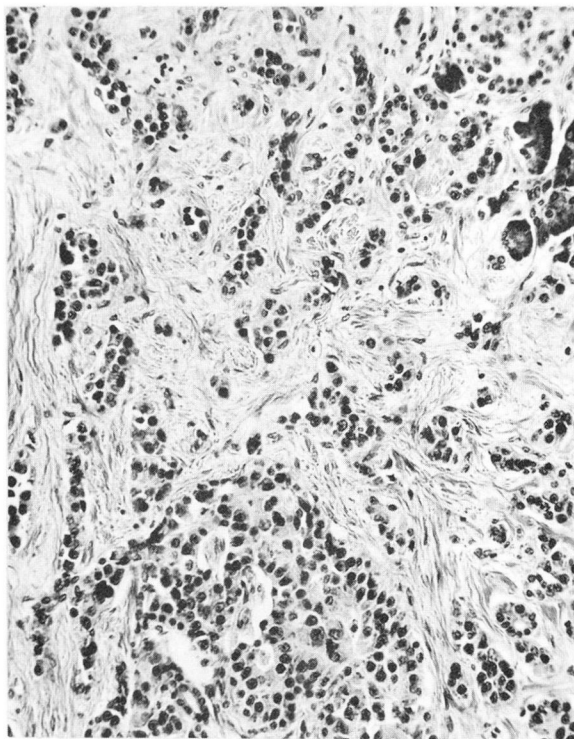


Fig. 1. Invasive, sclerosing neoplasm in pancreas interpreted as being a portion of an islet-cell carcinoma. Hematoxylin and eosin stain; magnification X 220.

Discussion

In 1955, Zollinger and Ellison² described a severe form of peptic ulcer disease associated with a non-beta islet-cell carcinoma of the pancreas. This syndrome is characterized by the secretion of a large volume of gastric acid, and severe peptic ulcer disease resistant to the usual medical and surgical therapy. Total gastrectomy is generally required for relief of the ulcer disease. Diarrhea secondary to the large volume of gastric acid and its effects on small-bowel motility and inactivation of the pancreatic enzymes is now also recognized as a part of this syndrome.³⁻⁷ The relationship of the gastric hypersecretion to the tumor has been clarified by the work of Gregory and his associates,⁸ who extracted a gastrin-like substance from the tumor in a patient with this syndrome.

A second syndrome of a severe diarrhea without gastric hypersecretion has also been described.^{9,10} The diarrhea may occur in the absence of gastric hypersecretion and is thought to be due to overproduction of succus entericus.^{9,10} The reason for the diarrhea in these cases has not been determined, but the diarrhea has been corrected by the removal of the tumor. One such patient has previously been

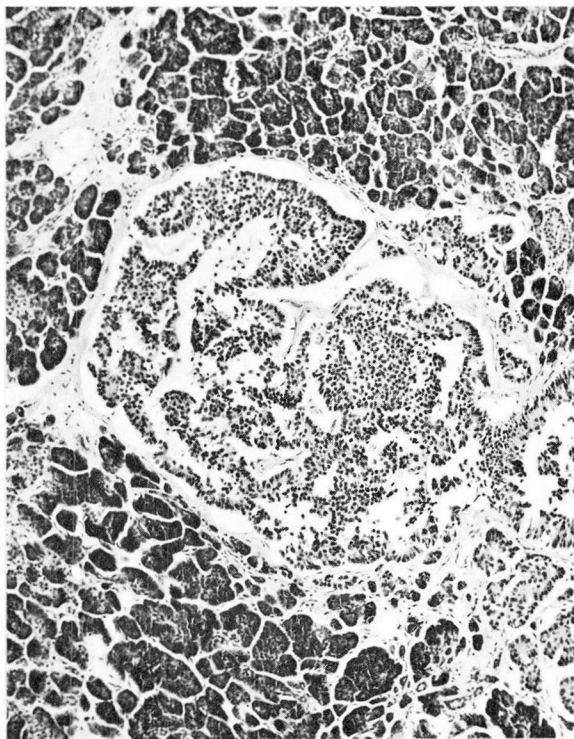


Fig. 2. One of several circumscribed foci of uniform cells unassociated with sclerosis, mimicking a giant pancreatic islet and interpreted as a small adenoma. Hematoxylin and eosin stain; magnification X 80.

reported also to have flushing attacks.¹ Thus it is apparent that tumors having the histologic features of a non-beta islet-cell tumor may have the ability to produce more than one physiologically active substance.

The case described in our report includes features of the Zollinger-Ellison syndrome with severe peptic ulcer disease associated with a non-beta islet-cell carcinoma of the pancreas. The patient is unusual, however, as recurrent attacks of generalized flushing, hyperperistalsis, diarrhea, back and leg pain have been prominent features of his symptoms. The reason for these attacks has not been found. The repeated studies for evidence of excessive serotonin production have been consistently negative. Two 24-hr. urine collections have given normal values for histamine excretion.

The treatment has been complicated by the presence both of severe peptic ulcer disease and of recurrent episodes of flushing and hyperperistalsis. A total gastrectomy is required for cure of the peptic ulcer disease associated with metastatic non-beta islet-cell carcinoma. When the diarrhea is secondary to excessive production of gastric acid a total gastrectomy also relieves the diarrhea. In those cases of

diarrhea either with or without gastric hypersecretion where the complete tumor can be removed the diarrhea can be relieved. In view of his atypical symptoms, and since no anastomotic ulcer could be found at the reexploratory operation, a total gastrectomy was not performed. Chlorpromazine in large doses has seemed to decrease the flushing attacks and diarrhea.

Summary

A case is reported of a non-beta islet-cell carcinoma of the pancreas associated with a severe peptic ulcer diathesis. The patient is unusual in that episodic attacks of flushing, diarrhea, and low back and leg pain have been prominent features of the disease. The reason for these attacks is not known but it would appear that the tumor is capable of producing more than one physiologically active substance.

References

1. Murray, J. S.; Paton, R. R., and Pope, C. E., II: Pancreatic tumor associated with flushing and diarrhea. *New England J. Med.* **264**: 436-439, 1961.
2. Zollinger, R. M., and Ellison, E. H.: Primary peptic ulcerations of jejunum associated with islet-cell tumors of pancreas. *Ann. Surg.* **142**: 709-723; discussion, 724-728, 1955.
3. Zollinger, R. M., and Craig, T. V.: Endocrine tumors and peptic ulcers. *Am. J. Med.* **29**: 761-768, 1960.
4. Verner, J. V., and Morrison, A. B.: Islet-cell tumor and syndrome of refractory watery diarrhea and hypokalemia. *Am. J. Med.* **25**: 374-380, 1958.
5. Rawson, A. B.; England, M. T.; Gillam, G. G.; French, J. M., and Stammers, F. A. R.: Zollinger-Ellison syndrome with diarrhoea and malabsorption. Observations on patient before and after pancreatic islet-cell tumour removal without resort to gastric surgery. *Lancet* **2**: 131-134, 1960.
6. Chears, W. C., Jr.; Thompson, J. E.; Hutcheson, J. B., and Patterson, C. O.: Pancreatic islet tumor with severe diarrhea. *Am. J. Med.* **29**: 529-533, 1960.
7. Maynard, E. P., III, and Point, W. W.: Steatorrhea associated with ulcerogenic tumor of pancreas. *Am. J. Med.* **25**: 456-459, 1958.
8. Gregory, R. A.; Tracy, H. J.; French, J. M., and Sircus, W.: Extraction of gastrin-like substance from pancreatic tumour in case of Zollinger-Ellison syndrome. *Lancet* **1**: 1045-1048, 1960.
9. Telling, M., and Smiddy, F. G.: Islet tumours of pancreas with intractable diarrhoea. *Gut* **2**: 12-17, 1961.
10. Espiner, E. A., and Beaven, D. W.: Non-specific islet-cell tumour of pancreas with diarrhea. *Quart. J. Med.* **31**: 447-471, 1962.