

# SUBCUTANEOUS FAT NECROSIS WITH CALCIFICATIONS AND HYPERCALCEMIA IN AN INFANT

## Report of a Case

JAMES K. McALEER, M.D.,\* and ROBERT D. MERCER, M.D.

*Department of Pediatrics*

**M**ANY investigators have reported cases of subcutaneous fat necrosis, some with accompanying calcifications radiologically or histologically proved; few of the patients have also had elevated serum calcium levels. The purpose of this paper is to report the case of an infant with the three abnormalities, and to review the previously published cases of a similar nature.

## Report of a Case†

A 30-day-old white female was first admitted to the Cleveland Clinic Hospital in July, 1963, because of irritability on handling, inability to gain weight, and lumps under the skin. The infant was said to be the product of a normal pregnancy in a 38-year-old gravida 11, para 9 mother weighing 220 pounds. The labor was four hours in duration. The delivery was described as difficult, and resuscitation of the infant was necessary. The referring physician related that petechial hemorrhages were apparent on the head, and "hardened, reddened areas existed on the skin especially around the shoulder."

A roentgenogram of the chest the first day of life was said to have shown an enlarged heart. A course of digitalis was administered for five days, and another roentgenogram was made; it was said to demonstrate a normal heart size. The infant was discharged from the hospital on the ninth postpartum day. While at home, she occasionally vomited, reported as occasionally projectile in character. The mother stated there was no history of excessive vitamin D or calcium intake by herself or by her infant. The increasing prominence of the skin lesions, failure to gain weight, and irritability prompted referral to this hospital.

*Examination and studies.* At our first examination in July, 1963, the infant was 21 inches long, and weighed 9 pounds (10 ounces less than her birth weight). The pulse rate was 152 and the temperature was 102.4 F. She was rather complacent unless handled or moved. The sucking reflex was normal. Slightly violaceous, moderately erythematous, elevated, firm, nodular subcutaneous lesions were present on the posterior and deltoid regions of both shoulders and the left preauricular area. Flat subcutaneous nodular indurations were present over the upper posterior portion of the chest (*Fig. 1*). Similar split-pea-sized lesions were present on the lateral portions of the thighs. All mentioned areas were apparently quite tender. The lungs were clear, no heart murmurs were heard, and no gross cardiomegaly was apparent. The liver was felt two fingerbreadths below the right costal margin. The neurologic examination revealed no abnormalities.

The initial blood studies showed a hemoglobin content of 16.6 gm. per 100 ml., with a hematocrit reading of 51 percent. The white blood cell count was 14,500 per cubic millimeter, with a normal differential count for an infant one month old. The blood urea content was 57 mg. per 100 ml.; a fasting blood sugar determination was 59 mg. per 100 ml.; a serologic test for syphilis (V.D.R.L.) was negative; and the protein electrophoretic pattern was normal. *Escherichia coli* (80,000 per ml.) was cultured in a specimen of the urine.

Two days after admission to the hospital the serum calcium was 14.8 mg. per 100 ml. (maximum normal in our laboratory is 11 mg. per 100 ml.); the serum phosphorus was 3.8 mg. per 100 ml. (*Fig. 2*). The alkaline phosphatase was 1.3 Bodansky units. On the seventh hospital day, the serum calcium was 16.6 mg. per 100 ml.; on the tenth day, 18.6 mg., and the serum phosphorus, 3.9 mg. per 100 ml. At that time administration of prednisone, 20 mg. per day, was

\*Intern in the Department of Pediatrics.

†The patient was referred to us by Dr. Donald B. Cuthbertson of Sandusky, Ohio.

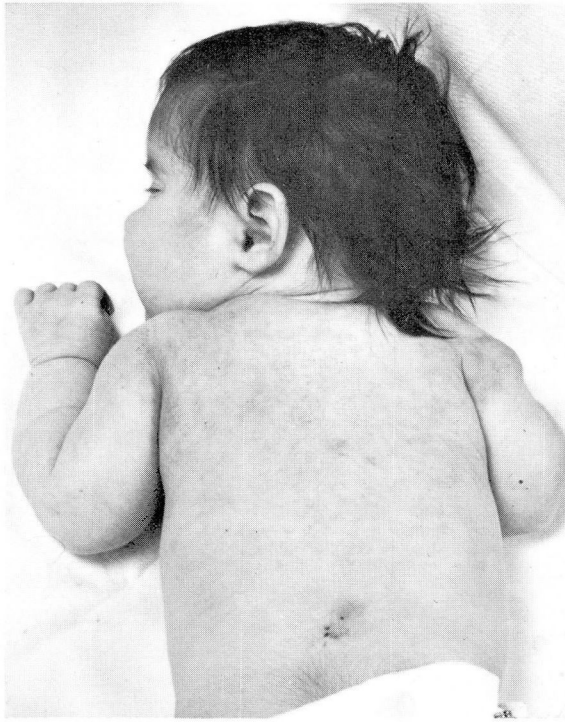

Fig. 1. Photograph taken on the second hospital day, demonstrating the elevated, firm, nodular, subcutaneous lesions on the back.

started. The serum calcium level decreased to 13.1 mg. per 100 ml. on the fourteenth hospital day, and to 11.2 mg. three days later. Only at that time did the urine specimen register a negative Sulkowich test; previously, repeated tests on urine specimens taken just before feeding were 3 or 4+. The mother's serum calcium content was 9.6 mg. per 100 ml., and serum phosphorus, 2.2 mg. per 100 ml.

The roentgenogram of the chest, taken on the day of admission to the hospital, showed clear lung fields and a normal heart configuration. There was evidence of multiple pleomorphic calcifications in the subcutaneous tissues. Other roentgenograms showed the skeleton to be normal. The roentgenogram of the kidney, ureter, and bladder, and a urogram demonstrated no urinary calcific densities, but the left renal silhouette was not visualized. The electrocardiogram exhibited the presence of probable right ventricular hypertrophy. Under local anesthesia, a biopsy specimen was taken from a representative area on the back, and a pathologic diagnosis was reported as "adiponecrosis neonatorum with focal calcifications" (Fig. 3). One significant feature histopathologically is the fact this was not the usual type of fat necrosis. There were no prominent masses of lipophages; necrotic fat cells contained fine acicular slits reminiscent of fatty acid deposition such as seen in necrosis due to pancreatic enzymes.

On the twelfth hospital day, a grade 2 to 3 continuous, systolic murmur developed which previously had not been present. No trill was palpated. The murmur persisted for five days, but by the sixth day only a brief, distant systolic murmur could be heard; the continuous aspect had disappeared.

The patient was given a low-calcium diet consisting of sodium sulfate in a concentration of 4.5 per liter added to whole milk. The sodium sulfate was made up in 0.72-gm. packages, one package per six-ounce feeding. The administration of prednisone was maintained at 5 mg., four times daily, for eight days, at which time it was gradually reduced to 2.5 mg., two times daily. The infant gained 350 gm. while in the hospital. The serum calcium content was 10.3 mg. per

# SUBCUTANEOUS FAT NECROSIS IN INFANT

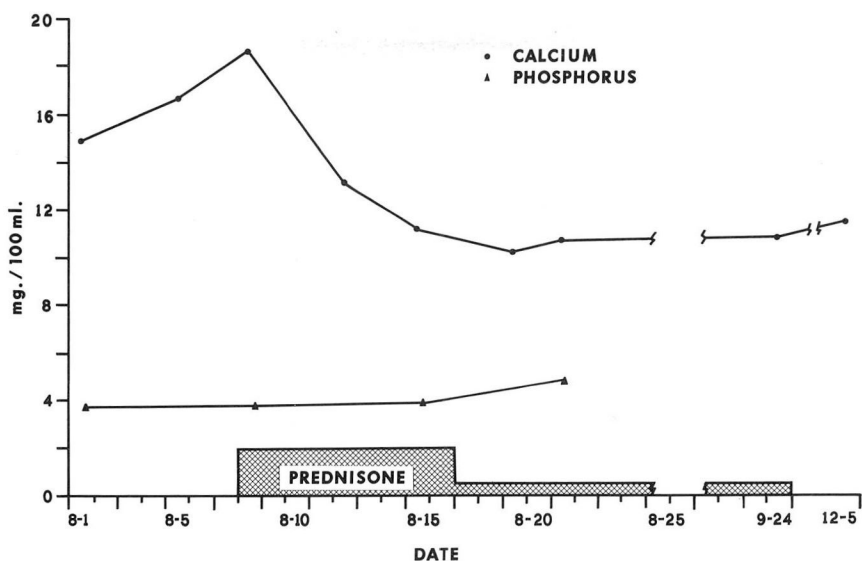


Fig. 2. Graph demonstrating the relationship between the serum calcium and serum phosphorus levels and the prednisone therapy.

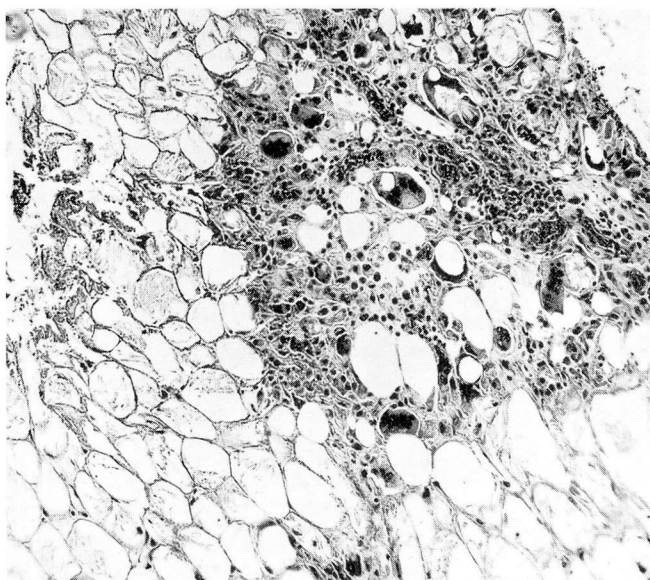


Fig. 3. Photomicrograph of a section of a biopsy specimen from the back demonstrating fat necrosis and abundant giant cells. Hematoxylin-eosin-methylene blue stains; magnification X100.

100 ml. on the twentieth hospital day, and 10.7 mg. on the twenty-second day, at which time the patient was discharged from the hospital. The mother was given instructions in regard to the sodium sulfate and the low-calcium diet. The standard vitamin preparations were not to be used in order to avoid giving vitamin D.

The patient has been followed up for 10 months. She has become a happy, alert infant developing along normal physical and mental lines. The calcium levels remain within normal limits, even after discontinuation of administration of prednisone for six and one-half months.

When the infant was five months old, the calcific densities although still roentgenographically evident, were notably diminished. The patient's diet at present (11 months of age) is normal except for the avoidance of excessive milk intake and vitamin D.

### Discussion

Harrison and McNee<sup>1</sup> in 1926 described the syndrome of subcutaneous fat necrosis with calcifications and hypercalcemia. One of their patients had a serum calcium level of only 9.3 mg. per 100 ml., but the patient died at four months of age. The other patient, with a serum calcium level of 15 mg. per 100 ml., went blind and was mentally retarded at one year of age. Clay<sup>2</sup> in 1956 described a case of hypercalcemia and subcutaneous calcium in an infant who also contracted osteopetrosis of the lower extremities. In April, 1957, Martin and Steven<sup>3</sup> reported the case of a newborn whose serum calcium content was 12 mg. per 100 ml. at the age of seven weeks, and 13.9 mg. per 100 ml. at seven months. Calcifications were still present, according to roentgenograms, when the patient was 15 months old. In September, 1962, three cases were reported, from the Cincinnati Children's Hospital, of subcutaneous calcifications associated with serum calcium levels.<sup>4</sup> In one patient, levels increased to 13.5 mg. per 100 ml., and were accompanied by nephrocalcinosis; in two other patients serum calcium levels were 18.0 mg. and 16.5 mg. per 100 ml.

In most of the reported cases the usual course was that of idiopathic hypercalcemia.<sup>5</sup> Failure to gain weight, irritability, fever, and vomiting were the most frequent symptoms, typically noted in infants from three to eight weeks of age. Usually there were complications of pregnancy and/or delivery, and some suggestion of trauma was apparent in the newborn. Two of the patients<sup>4</sup> were delivered by cesarian section, but in one the pregnancy involved a transverse lie, 43-week gestation, and a 4,300-gm. infant, while the other was complicated by preeclampsia, a 36-hour labor with impending uterine rupture, and a 4,400 gm. infant.

Our patient is the only one who had a transient heart murmur; a patent ductus arteriosus was at first suspected. The reasons for the enlarged liver and probable electrocardiographic changes remain obscure. The infant did not appear to be in cardiac failure. The biopsy site was still draining necrotic liquified fat 20 days after the operative procedure. Biopsies should be performed only when necessary, and then all possible precautions should be taken to keep the site uncontaminated. In one infant, a large crater-like ulceration formed after infection developed at the operative site.<sup>4</sup>

The pathogenesis of this syndrome remains obscure. Trauma with compression of tissues against underlying bones probably results in ischemia followed by fat necrosis. The exact relationship between the calcium deposits in the subcutaneous

tissue and the elevated concentration of serum calcium is not known. Biochemical examination of fresh tissue biopsy specimens for the presence of proteolytic enzymes or other etiologic agents should be considered as a future diagnostic tool. Elevated levels of serum calcium can result in renal calcinosis, mental retardation, or even cardiac arrest in systole, although the latter complication has not been reported. Obviously, the prompt inauguration of treatment is of paramount importance.

### Summary

A case is reported of subcutaneous fat necrosis with calcifications and associated hypercalcemia in an infant; the six cases from the literature are also briefly discussed. In the newly reported case, the serum calcium content increased to 18.6 mg. per ml. The serum calcium levels decreased to within the normal range after administration of prednisone and limitation of dietary vitamin D and calcium. No complications are apparent after 11 months.

### References

1. Harrison, G. A., and McNee, J. W.: Sclerema neonatorum, with special reference to chemistry of subcutaneous tissues; with histological report. *Arch. Dis. Child.* **1**: 63-84, 1926.
2. Clay, P. R.: Idiopathic hypercalcaemia with subcutaneous calcium deposits following pseudosclerema. *Proc. Roy. Soc. Med.* **49**: 598-599, 1956.
3. Martin, M. M., and Steven, E. M.: Subcutaneous fat necrosis of newborn with calcifications of tissues. *Arch. Dis. Child.* **32**: 146-148, 1957.
4. Michael, A. F., Jr.; Hong, R., and West, C. D.: Hypercalcemia in infancy associated with subcutaneous fat necrosis and calcification. *Am. J. Dis. Child.* **104**: 235-244, 1962.
5. Lightwood, R.: Idiopathic hypercalcaemia in infants with failure to thrive. (Proceedings of Twenty-Third General Meeting, British Paediatric Association.) *Arch. Dis. Child.* **27**: 302-303, 1952.