

OPEN SURGERY UPON THE MITRAL VALVE: PREVENTION OF AIR EMBOLUS

DONALD B. EFFLER, M.D., LAURENCE K. GROVES, M.D.,

and

KRISHAN GULATI, M.D.*

Department of Thoracic and Cardiovascular Surgery

THE open approach to the mitral valve which employs extracorporeal circulation has been utilized at the Cleveland Clinic Hospital since 1956. Initially this approach was used only in the treatment of mitral insufficiency,¹ later for selected cases of mitral stenosis and, recently,² for direct replacement with the Starr-Edwards† mitral valve prosthesis.^{3,4}

Although the mitral valve has been accessible by the direct open approach for the last seven years, we have not abandoned the closed operations for pure mitral stenosis. Extracorporeal circulation that employs high-flow perfusion imposes significant time and economic factors both on the patient and on the institution. At this writing we restrict the open operations upon the mitral valve to those patients who present: (1) predominant mitral insufficiency, (2) severely calcified valves, (3) restenosis after previous surgery, and (4) evidence that mural thrombus may be present.

Our early and more recent experiences with open operations upon the mitral valve including prosthetic replacement have been reported.¹⁻⁵ The purpose of this communication is twofold: (1) to commend the right-sided approach to the mitral valve, and (2) to describe a simple method that has eliminated the hazard of systemic air embolus. We are convinced that these two factors contribute appreciably toward the improving results and the increasing safety of open operations upon the diseased mitral valve.

Experience

Since 1956, 218 open operations have been performed in the Cleveland Clinic Hospital for mitral valve disease; in each, extracorporeal circulation was utilized. Originally the open procedures were restricted to patients suspected of having dominant mitral insufficiency; later the open approach was used to facilitate commissurotomy in patients who presented restenosed or heavily calcified valves. Since September 1961, 103 patients have been operated upon for replacement of the diseased mitral valve with a Starr-Edwards prosthesis.⁶ Analyses of the early results and the technics employed have been reported.^{4,5}

*Fellow in the Department of Thoracic and Cardiovascular Surgery.

†Manufactured by Edwards Laboratories, Inc., Santa Ana, California.

Right Anterior Approach to the Mitral Valve

Early operations upon the mitral valve, championed by Bailey and associates,⁷ Davila and associates,⁸ Harken and associates,⁹ and others, utilized a posterolateral left thoracotomy approach. The left atrium was entered through its atrial appendage for digital or instrumental valvulotomy. When extracorporeal circulation permitted open operations upon the mitral valve many, perhaps a majority of, cardiac surgeons continued with the left posterolateral thoracotomy. Undoubtedly this approach has its distinct advantages.

Since 1956 we have advocated the right anterolateral thoracotomy approach to the mitral valve (*Fig. 1*). Initially the valve was exposed through the right atrium via an incision in the fossa ovalis.¹ The right atrial avenue is not always satisfactory,

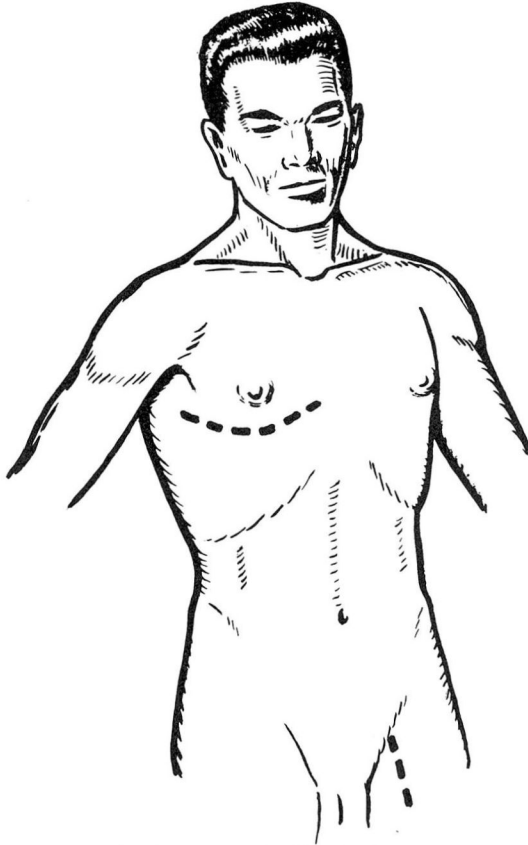


Fig. 1. Schematic reproduction of incisions required for the right anterior thoracotomy approach to the mitral valve. The thorax is entered by a limited anterolateral incision made directly through the fourth interspace. The patient is in a supine position with the right side slightly elevated. Arterial cannulation is made through the conventional incision over the left common femoral artery.

as a small interatrial septum limits the exposure. We prefer to dissect the interatrial groove as described by Sondergaard¹⁰ and to enter the left atrium directly (*Fig. 2*).

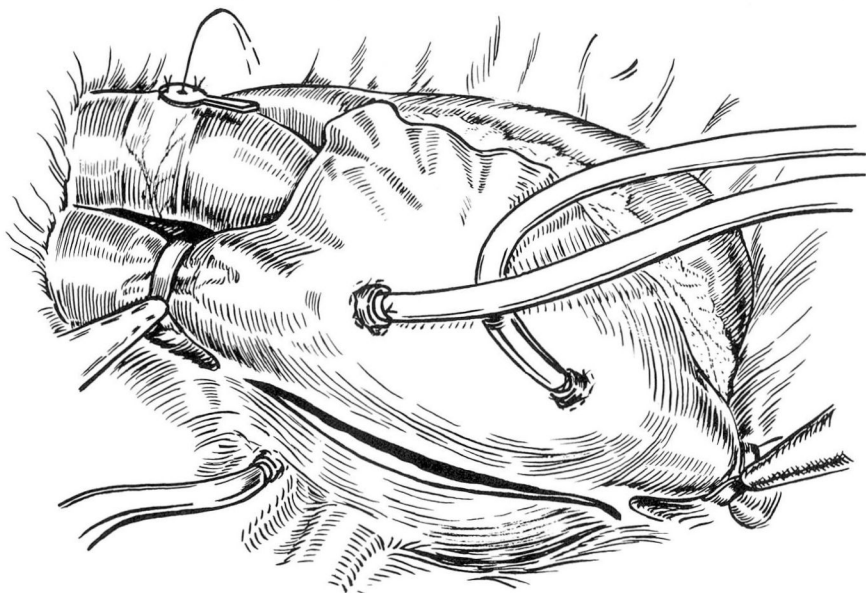


Fig. 2. This drawing depicts the right-sided approach to the mitral valve and the relationship of the aortic vent to the remainder of the surgical field. The incision follows the contour of the interatrial groove, which dips posteriorly in a downward arc as the dissection nears the inferior vena cava. This initial dissection literally separates the posterior aspects of the right and left atrial chambers. The two vena cava cannulas are seen emerging from the right atrium. The left atrial cannula depicted in the lower left portion of the illustration enters via the right superior pulmonary vein.

The advantages to this approach warrant its continued use. In brief, these advantages are: (1) the right anterior thoracotomy requires less operating time and is better tolerated by the sick patient; (2) this exposure facilitates cannulation of the venae cavae and the left atrium; (3) the right approach permits direct access to the mitral valve, the tricuspid valve, and the aortic valve—exposure of the aortic valve does require extension of the incision by sternal transection. There are other reasons to favor the right-sided approach but the above constitute the major advantages. As it happens in all forms of specialty surgery, repeated use of an operative procedure that yields good results convinces the surgical team that theirs is the method of choice.

For the right thoracotomy approach the patient is in a supine position with 30-degree elevation of the right thorax; a submammary skin incision is made and carried through the fourth interspace. The internal mammary bundle is divided but the sternum is not transected unless aortic valve surgery is contemplated. Closure of the thoracotomy incision is accomplished with pericostal chromic catgut,

and it is common practice to drain the right pleural space with two Foley bag catheters attached to waterseal suction drainage. Further details of technic are here limited to the illustrations and their accompanying legends.

Prevention of Air Embolus

Operations upon the mitral valve, particularly those intended for prosthetic valve replacement, require a relatively dry field. This means that both left atrium and left ventricle must be periodically emptied and inadvertently are given the opportunity to entrap air that may subsequently enter systemic circulation. Failure to remove entrapped air constitutes a serious, oftentimes fatal, threat to the patient. Appreciation of this problem was forcibly brought to us by three episodes of cerebrovascular accident that occurred early in our experience with open mitral valve surgery. Analysis of these cases convinced us that air embolus was the etiologic factor in each instance. It is fortunate that all three patients survived, although in each there was some degree of residual neurologic deficit.

In the last 100 open operations upon the mitral valve, including 80 operations for Starr-Edwards prosthetic valve replacement, air embolism has not been evident. This complication has been avoided by the routine use of a simple adjunct to our right thoracotomy technic for mitral valve surgery. This adjunct has been complemented by carbon dioxide gas bathing of the operative field, a technic that has received widespread use in recent years. In theory, the carbon dioxide gas displaces room air by gravity, and is far more rapidly absorbed than air, when introduced into the arterial circulation. Although we continue to use carbon dioxide gas in the surgical field, random gas samples taken by one of us (L.K.G.) directly from the open left ventricle suggest that reasonable security is not provided by this adjunct.

Decompression of the left heart by vents of different types is standard procedure in most centers of cardiac surgery. Since 1956 we have utilized the left atrial vent² and have found it helpful for removal of residual air. This technic has limited efficacy since, in the supine position, the outflow tract of the left ventricle constitutes the highest point within the heart itself. Air trapped at this point cannot be removed by left atrial decompression alone. Therefore an additional safeguard will be required if the hazard of air embolus is to be avoided.

When the patient is in supine position the ascending aorta invariably rises above the left ventricular outflow tract. It is this area, immediately distal to the right coronary ostium, that constitutes the "high point" of air collection. This observation has lead us to vent the ascending aorta rather than the left ventricle as is common practice among many surgeons. Venting was accomplished initially by a cutdown hypodermic needle, but this proved to be clumsy and unreliable. A special needle vent was later designed by one of us (L.K.G.) for this purpose, and its use has eliminated the hazard of air embolus.¹¹ The Groves' needle resembles an ordinary thumbtack except that it has a hollow fenestrated stem to allow continuous

escape of gas or blood from its point of aortic insertion (*Fig. 3*). The needle is secured on the anterior surface of the aorta at its highest point by two fine silk sutures and is subsequently removed when the threat of air embolus has been obviated at the completion of the operative procedure.

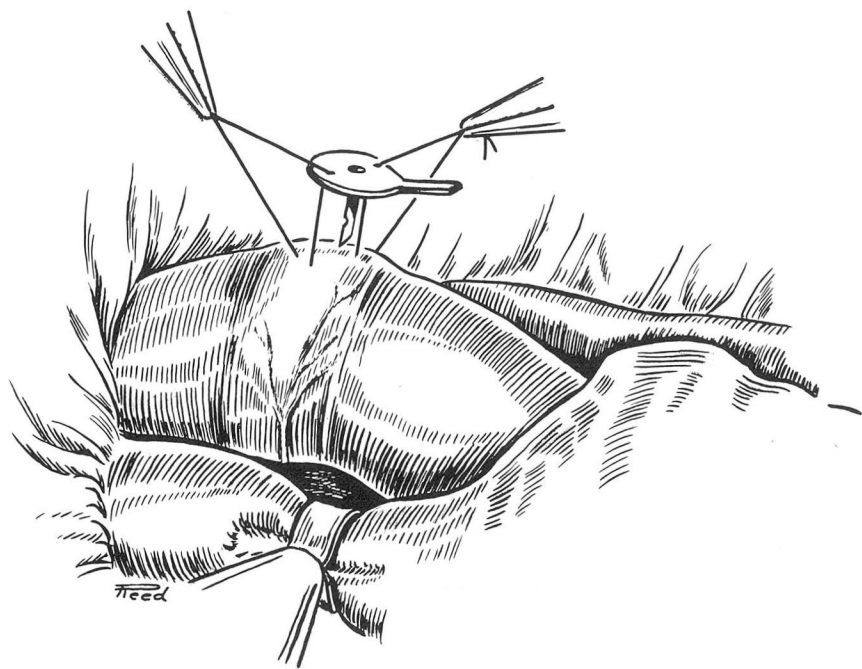


Fig. 3. Insertion of the aortic needle vent is undertaken after institution of extracorporeal circulation. The Groves' needle resembles a thumbtack with a hollow and fenestrated shaft. For additional convenience in handling, an extension has been added to the disk; this extension resembles a miniature panhandle (this needle is commercially available from Becton-Dickinson & Co.). The high point of the aorta is approximately midway between the right coronary artery and the innominate artery. An anatomic landmark helps to identify this point: a transverse fold of epicardium, fat, and blood vessel that is apparently unnamed and otherwise insignificant.*

**In our Department of Thoracic and Cardiovascular Surgery, this epicardial landmark is referred to as "Effler's fold." It seems unlikely that atlases of surgical anatomy will require revision to include this entity.*

The needle vent is inserted in the ascending aorta before the heart is incised. As long as the needle vent is in place, an 18-gauge, miniature blood fountain exists. This blood escapes into the operative field where it is recovered by the sterile aspirator. If high-flow extracorporeal circulation is maintained, a light gauze pack placed directly over the needle will prevent splashing of blood or the visual distraction of the surgeon. Should it be necessary to occlude the aorta intermittently throughout the procedure because of aortic incompetency, this may be done distal to the needle vent and immediately proximal to the innominate artery. Since the

majority of operations on the mitral valve do not utilize cardioplegia, ventricular contraction continues throughout the open procedure. If any gas is ejected by the contracting left ventricle it will escape promptly through the needle vent (*Fig. 4*).

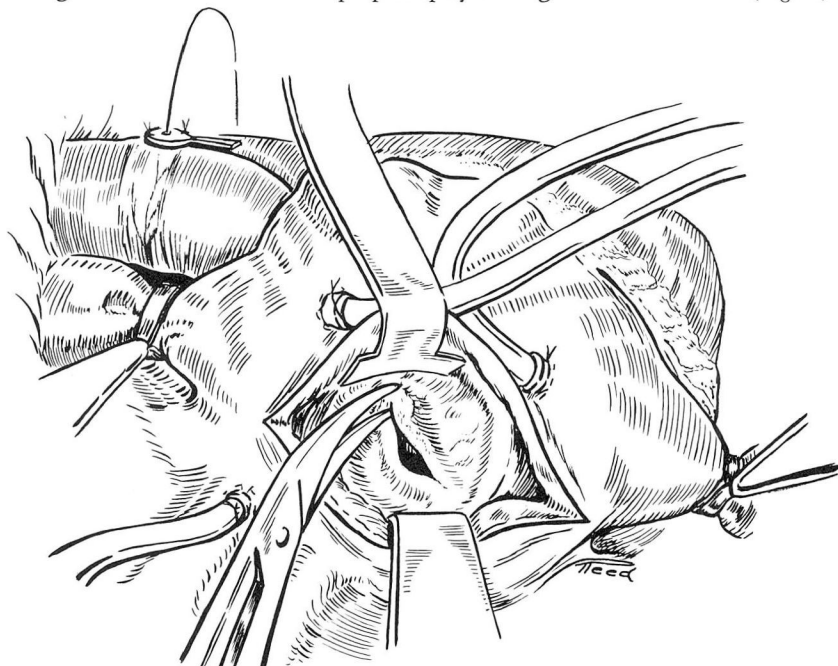


Fig. 4. Inspection of the mitral valve from the right-sided approach is readily provided by the interatrial incision and the use of soft malleable retractors. If the aortic valve is competent, little blood will return from the left ventricle. Should aortic insufficiency exist or be partially created by the retraction of the heart, intermittent occlusion of the aorta distal to the needle vent may be required. If high-flow extracorporeal circulation is employed, significant return from the pulmonary veins can be anticipated. This is handled easily by a sterile sump-type of sucker. The relatively small amount of blood that escapes from the needle vent will also be recovered from the dependent part of the surgical field. Open surgery upon the mitral valve for commissurotomy, valvulotomy, or valvuloplasty requires frequent manipulations of the leaflets. If the mitral valve is kept in a fixed open position, forward thrust by the left ventricle is not possible; however, maintenance of an open mitral valve interferes with the surgeon's visual evaluation of reconstructed anatomy and mitral valve function. Therefore anticipation that some air or gas will be trapped in the left ventricle makes adequate venting of the ventricular outflow mandatory.

Some of the gas will enter the right coronary artery, as this too approximates the aortic high point. Under ordinary circumstances this is not an event of major concern as the intracoronary air will be propelled by the flow of normal coronary perfusion until it is expelled into the coronary sinus (*Fig. 5*).

Summary

Utilization of the right-sided approach for open operations upon the mitral valve offers distinct advantages. We believe that the anterior right thoracotomy is

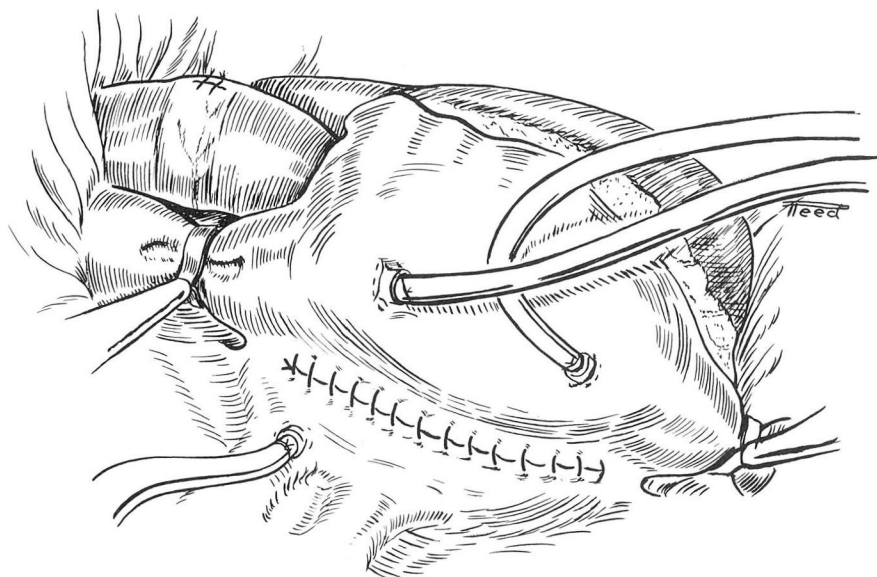


Fig. 5. Closure of the interatrial incision after open surgery upon the mitral valve is easily accomplished. At this time the left atrial cannula is used to advantage to remove any air that may have been trapped in the left atrium or pulmonary veins. The aortic needle vent is not removed until the left ventricle is given ample opportunity to eject any air or gas that may have been trapped within the left ventricle itself.

better tolerated by the sick patient; moreover it facilitates the surgical procedure by better exposure and by reduction of the operating time. The right-sided approach permits inspection and operation upon the tricuspid and the aortic valves as well.

The hazard of air embolus is virtually eliminated by the use of left atrial decompression and an aortic needle vent. This latter adjunct has eliminated the hazard of air embolus in the last 100 consecutive operations upon the mitral valve, including 80 prosthetic valve replacements.

References

1. Effler, D. B.; Groves, L. K.; Martinez, W. V., and Kolff, W. J.: Open-heart surgery for mitral insufficiency. *J. Thoracic Surg.* 36: 665-676; discussion, 690, 1958.
2. Effler, D. B., and Groves, L. K.: Open-heart surgery for acquired valvular heart disease: present technique and trends. *Arch. Surg.* 84: 155-169, 1962.
3. Effler, D. B.: Defects of mitral valve; current concepts of surgical treatment. *Cleveland Clin. Quart.* 29: 167-176, 1962.
4. Effler, D. B., and Groves, L. K.: Mitral valve replacement: clinical experience with ball-valve prosthesis. *Dis. Chest.* 43: 529-538, 1963.
5. Effler, D. B.; Groves, L. K., and Favaloro, R.: Aortic and mitral valve replacement. *Arch Surg.* 88: 145-153; discussion, 153-154, 1964.
6. Starr, A., and Edwards, M. L.: Mitral replacement: clinical experience with ball-valve prosthesis. *Ann. Surg.* 154: 726-740, 1961.

7. Bailey, C. P.; Jamison, W. L.; Bakst, A. E.; Bolton, H. E.; Nichols, H. T., and Gemeinhardt, W.: Surgical correction of mitral insufficiency by use of pericardial grafts. *J. Thoracic Surg.* **28**: 551-603; discussion, 624, 1954.
8. Davila, J. C.; Glover, R. P.; Trout, R. G.; Mansure, F. S.; Wood, N. E.; Janton, O. H., and Iaia, B. D.: Circumferential suture of mitral ring: method for surgical correction of mitral insufficiency. *J. Thoracic Surg.* **30**: 531-560; discussion, 560-563, 1955.
9. Harken, D. E.; Black, H.; Ellis, L. B., and Dexter, L.: Surgical correction of mitral insufficiency. *J. Thoracic Surg.* **28**: 604-624; discussion, 624-627, 1954.
10. Sondergaard, T.: Panel Discussion on Interatrial Septal Defects, p. 358-362, *in* Lam, C. R., editor: *Cardiovascular Surgery*. Philadelphia: W. B. Saunders Co., 1955, 543 p.
11. Groves, L. K., and Effler, D. B.: Needle-vent safeguard against systemic air embolus in open-heart surgery. *J. Thoracic & Cardiovas. Surg.*: In press.