

## NASAL SEPTAL RECONSTRUCTION

FRED R. TINGWALD, M.D.

*Department of Otolaryngology*

SEPTAL deformity is one of the most common findings on rhinoscopic examination. Often the deformity is minor, causes no disability, and therefore requires no therapy. Equally as often, however, the deformity produces symptoms or cosmetic defects which warrant treatment.

### Etiologic Factors

The etiologic factors that usually are enumerated are heredity, development, and trauma. I have encountered several families in which a parent and at least one child have almost identical deformities, and an hereditary origin is assumed. Most of the angular bony deformities with sharp ridges and spurs are believed to be developmental and to result from disproportionate rates of growth of the bones of the face and of the skull. The majority of the deformities involving the cartilaginous septum, especially the caudal dislocations, probably are traumatic in origin.

### Symptoms and Complications

Obstructive septal deflections produce definite symptoms that can be simulated by several other disease conditions, mainly the various types of vasomotor rhinitis and adenoidal hypertrophy. The prime symptom of the deflected septum is nasal obstruction, ranging from a feeling of fullness or stuffiness to almost complete unilateral or bilateral blockage. Associated with this symptom are excessive nasal and postnasal secretions, mouth breathing with attendant dryness and irritation of the mouth and pharynx, and the voice alteration termed *rhinolalia clausa*.

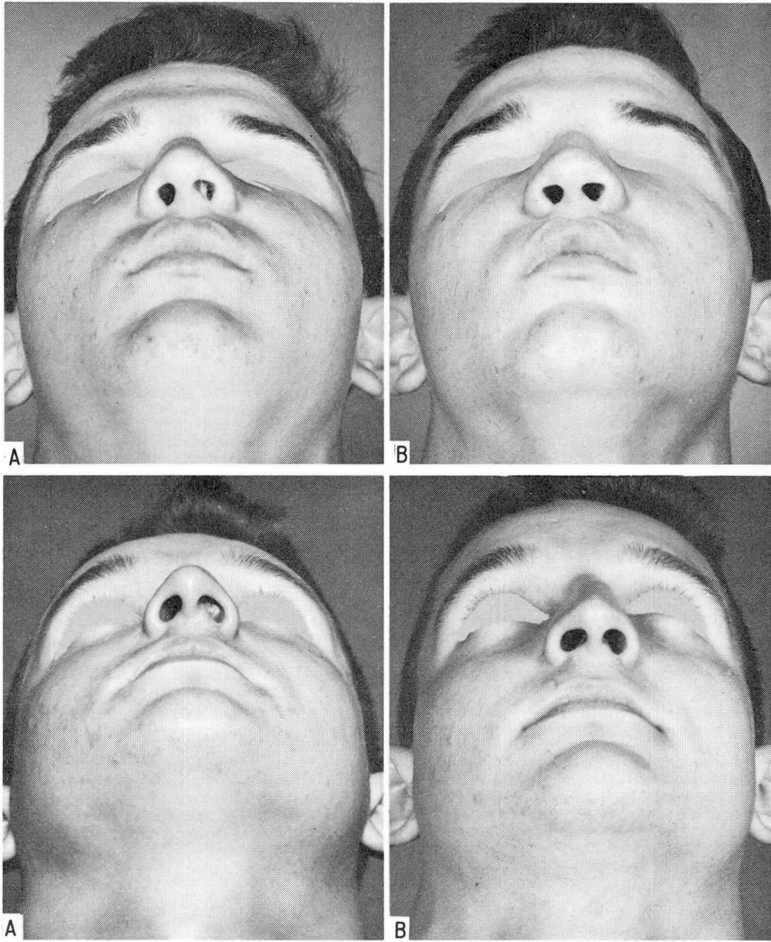
Complications of the obstruction include septal crusting and erosion with occasional epistaxis caused by localized drying of the mucosa, obstruction to normal sinus drainage with secondary sinusitis, and occasionally obstruction of the eustachian tube with a conductive type of hearing loss. Compensatory hypertrophy of the turbinates on the side opposite the deflection may lead to further symptoms of obstruction.

While it is not uncommon to find severe septal deformity in a cosmetically acceptable external nose (*Fig. 1A, 2A*), a twisted or displaced external nose is always associated with septal deformity usually of significant degree.

### Reparative Procedures

The ideal time for treating the traumatic septal defect is within a few days of its onset, because the fractured and displaced structures can almost always be mani-

*From a paper presented at the meeting of the American Otorhinologic Society for Plastic Surgery, New Orleans, Louisiana, March 25-29, 1963.*



**Fig. 1 and 2.** Septal dislocations with obstructions but without associated external deformity corrected by septal reconstruction.

pulated into their normal positions by relatively simple means, thereby avoiding later extensive nasal surgery. Also, immediate repositioning and splinting will almost always give cosmetic and functional results superior to those of later reconstructive procedures.

The important procedure usually overlooked in a fresh nasal injury is a careful rhinoscopic examination for evidence of septal fracture or dislocation. This is especially important in young children who are likely to have a dislocation of the septal cartilage rather than an actual fracture of the bony parts. Immediately after dislocation, a septal cartilage is easily replaced in its normal position and can be so

maintained by packing for a few days until healing has begun. However, to correct an old deformity, a complete septal reconstruction is usually necessary.

In the case of a twisted or displaced external nose (*Fig. 3, 4*), to assure a satisfactory functional and cosmetic result, both the septum and the external nose

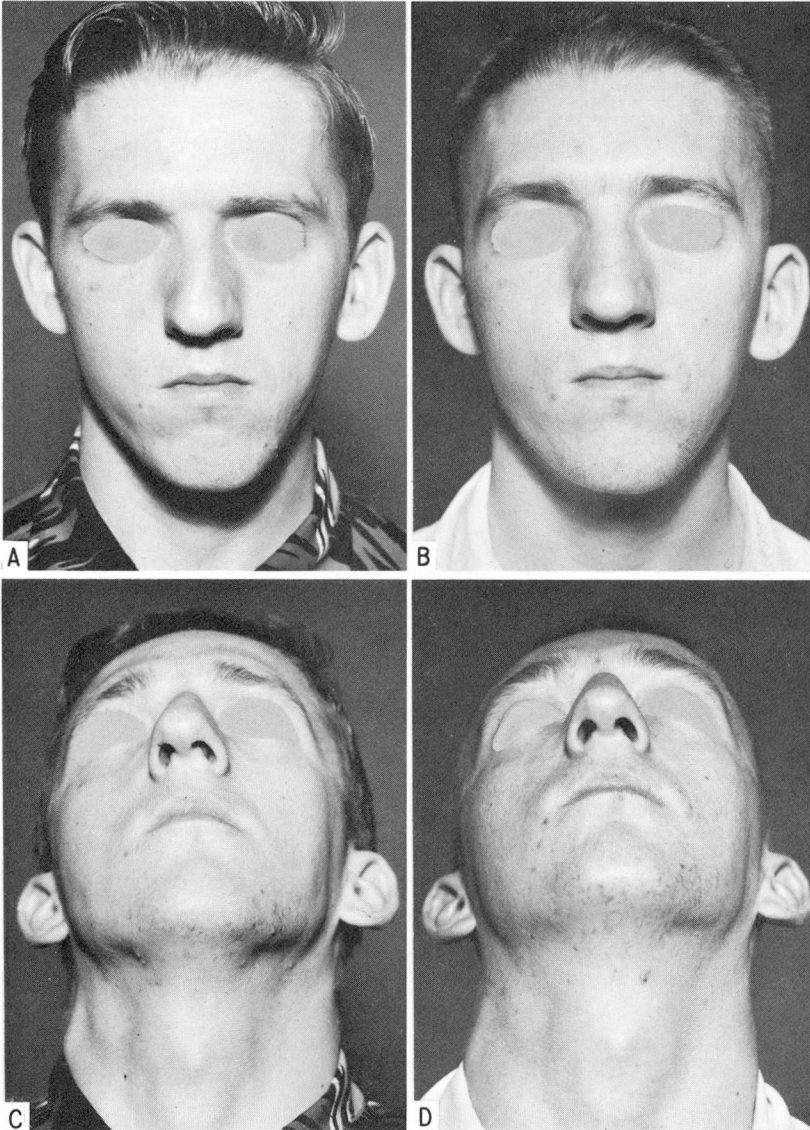


Fig. 3. A, C, Septal dislocation with associated external deformity; B, D, corrected by septal reconstruction.



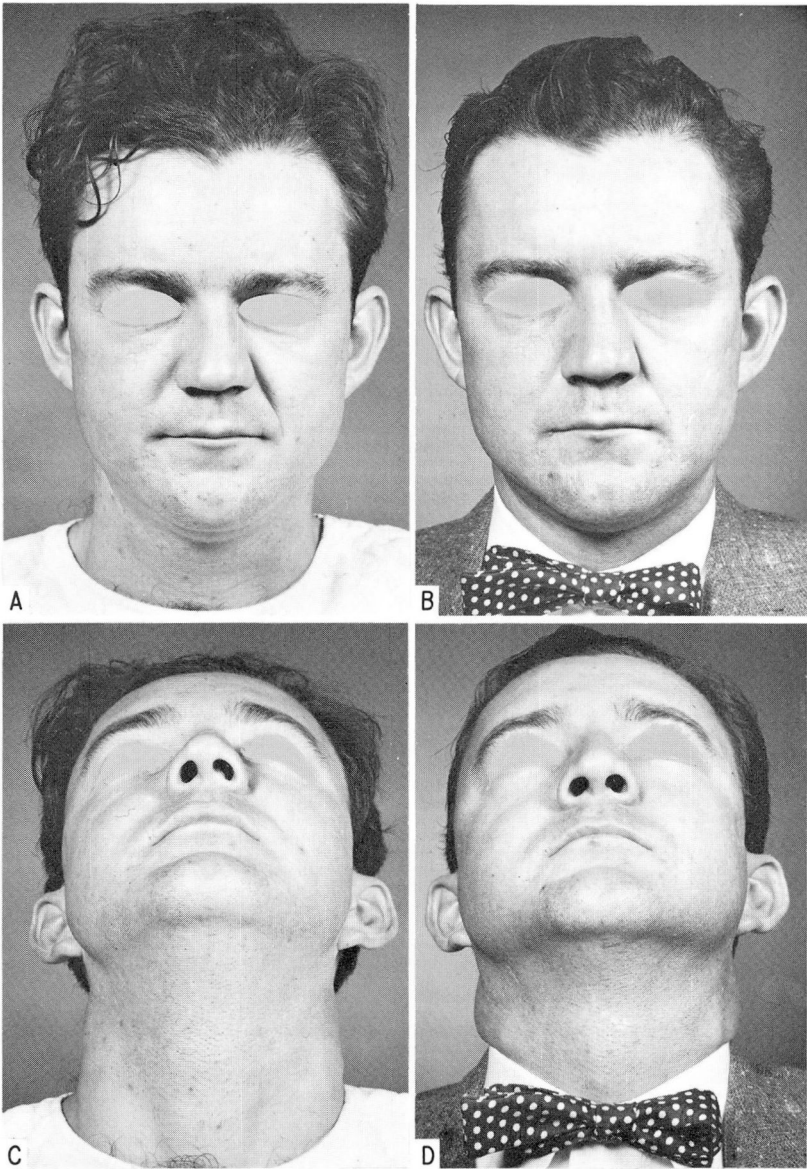
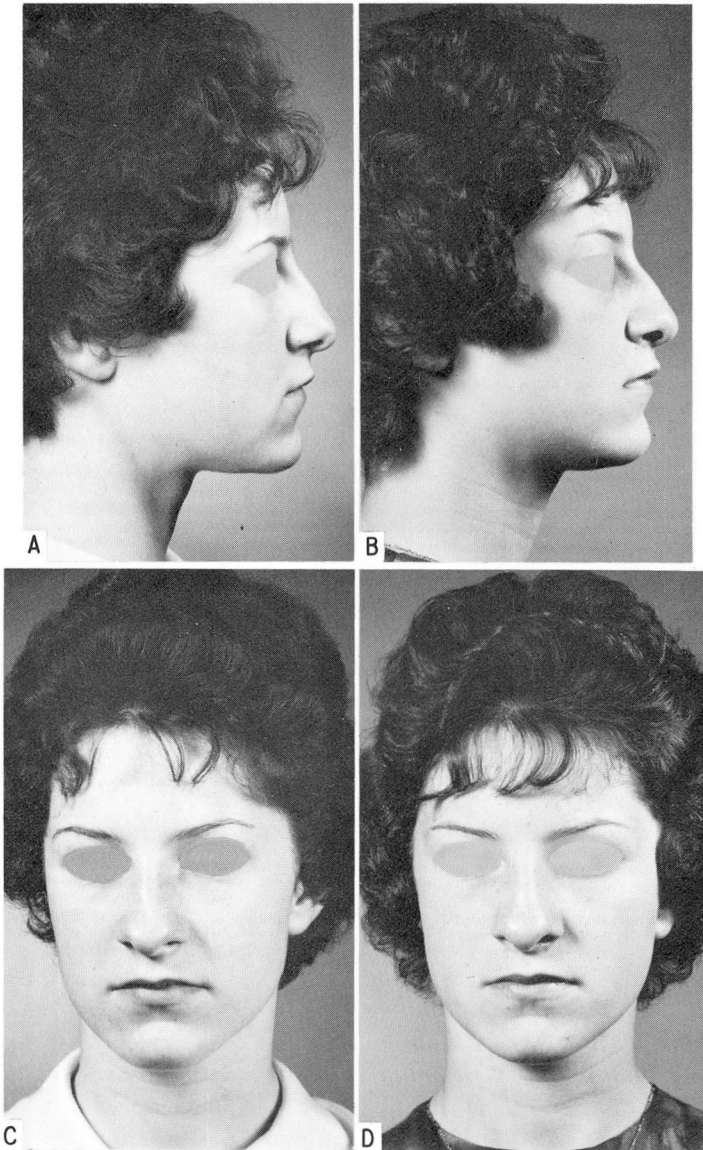


Fig. 4. A, C, Septal dislocation with associated external deformity; B, D, corrected by septal reconstruction.

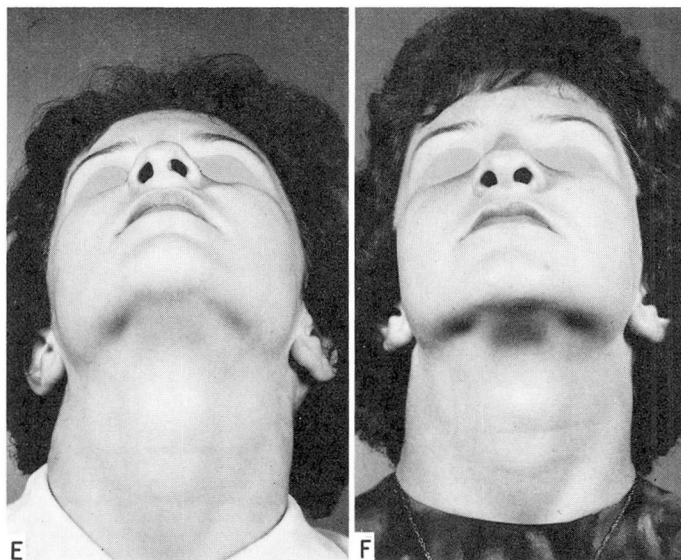must be repaired. At times a twisted nasal tip can be corrected by septal reconstruction without associated rhinoplasty. At other times the septal reconstruction and a

rhinoplasty must be performed as either a combined or a staged procedure, depending in part on the surgeon's preference and in part on the type and the degree of deformity (*Fig. 5-7*).



**Fig. 5.** A, C, E, Septal dislocation and external deformity in a child aged 13 years (who will require rhinoplasty after reaching maturity); B, D, F, after septal reconstruction.





(Fig. 5)

Surgical attack on the nasal septum was a rare procedure before 1885 when Koller described the anesthetic properties of cocaine.<sup>1</sup> In the next twenty years, numerous procedures were advocated for the correction of obstructive septal deflections. The most popular of these included sawing off the deflected portion, removing of spurs with a spokeshave or draw knife, and multiple full-thickness incisions of the septum with medial displacement and interlocking of multiple flaps.

In the early 1900's, Killian, Freer, Hajek, Ballenger, and others popularized the concept of submucous resection of the obstructive portions of the septum with maintenance of intact septal mucosal flaps.<sup>2</sup> The most important instrument conceived at that time was the swivel knife, which allowed the cartilaginous portion of the septum to be removed in one piece for possible reuse.

The standard submucous resection required a strip of cartilage to be left at the nasal dorsum and at the caudal portion of the septum to prevent sinking in of the soft tissues and resultant saddle deformity or flattened nasal tip. Occasionally, a patient who had undergone extensive standard submucous resection continued to have an alternate nasal obstruction due to a flaccid septum. This complication can, in large part, be avoided by routine reinsertion of an available straight septal segment or segments to provide stiffening. However, the problem remained of how to handle the dislocation of the caudal portion of the septum. Simple resection of the dislocated portion frequently resulted in nasal tip flattening that was often more distressing than the dislocation.

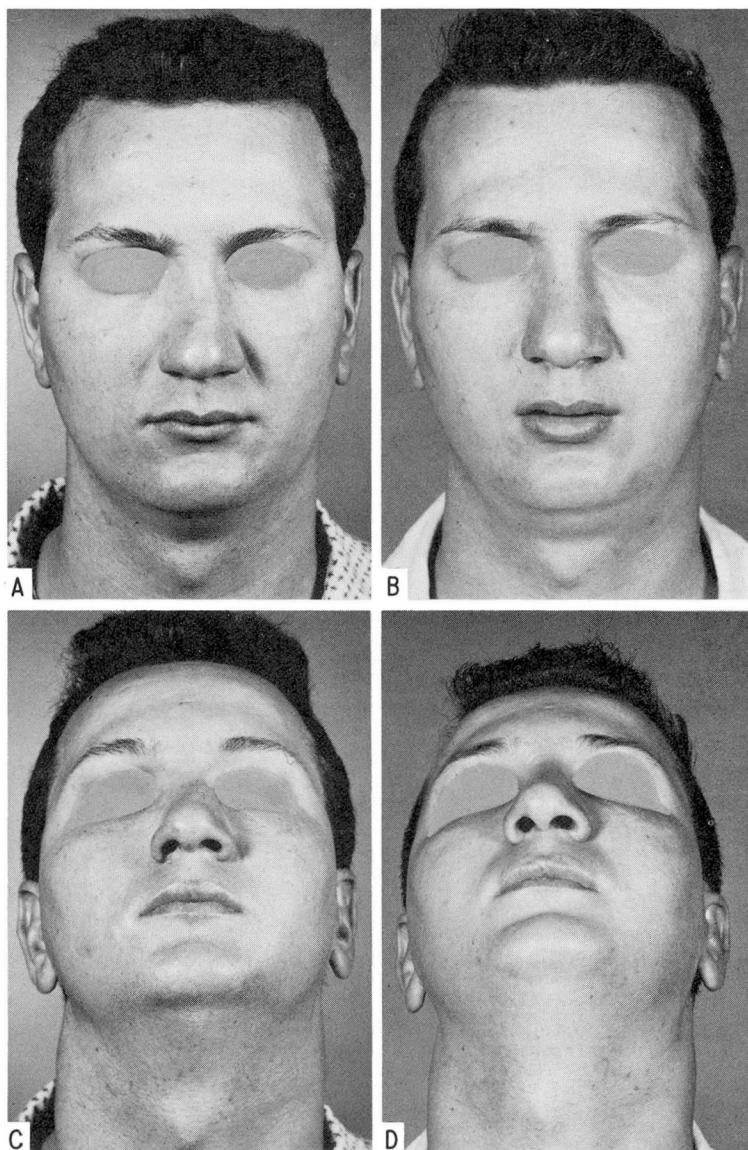


Fig. 6. A, C, Septal and external deformity; B, D, corrected by septal reconstruction supplemented by osteotomies and midline repositioning of the nasal bones.

In 1929 Metzenbaum<sup>3</sup> described a technic of repositioning the dislocated portion of the septum, which was satisfactory in a fair proportion of cases and is still in limited use today. The basic principle was unilateral hemitransfixion on the

side of the dislocation, with contralateral perichondral elevation. The cartilage was then incised at the angle of deflection and at the floor of the nose. Additional crosshatching was frequently necessary. The cartilage was left attached along its

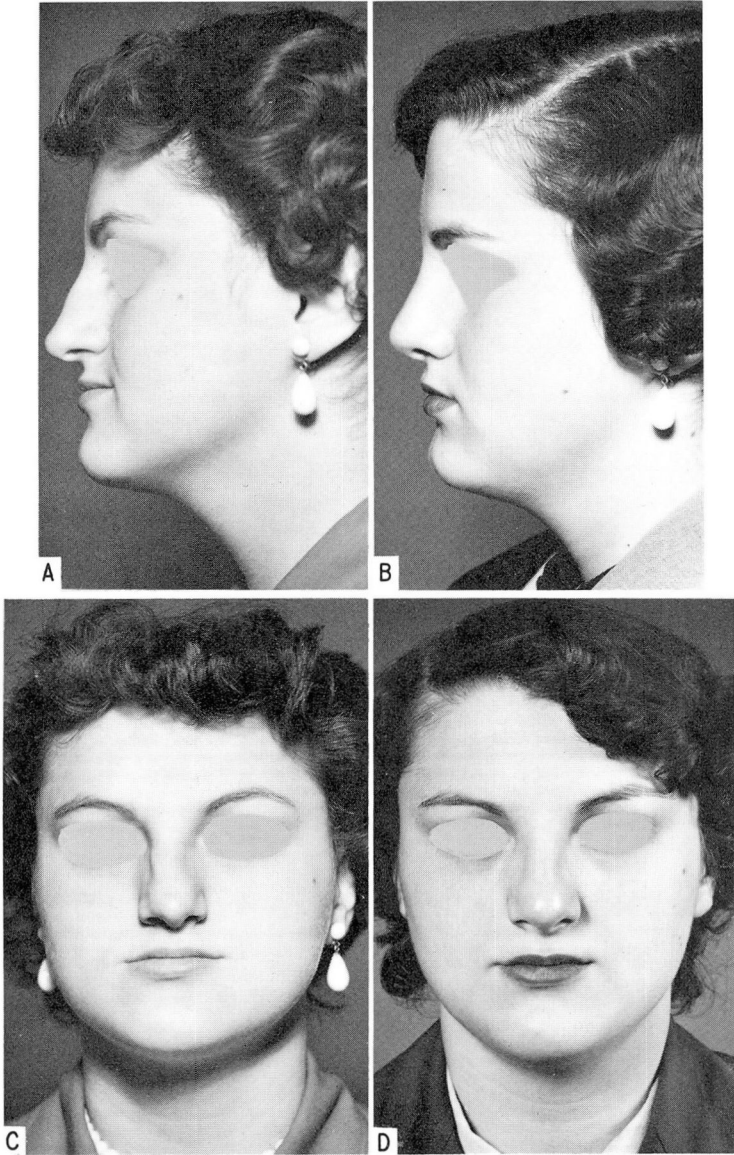


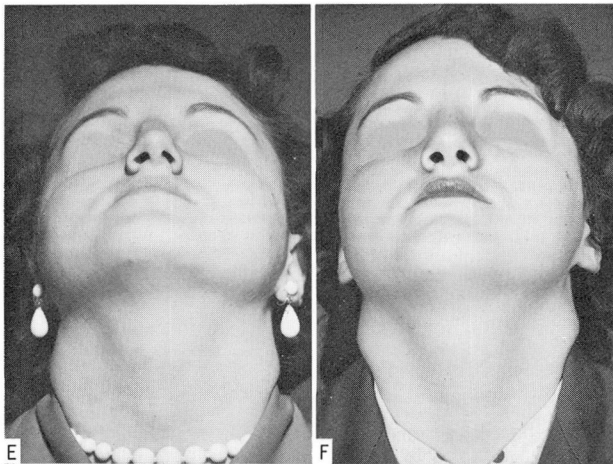
Fig. 7. A, C, E, Septal deformity, old nasal fracture, humped nose and long nose; B, D, F, septal reconstruction and complete rhinoplasty.



ventral border and to the unelevated perichondrium on the side of the dislocation. Medial displacement was then accomplished with fixation by sutures and packing. Unfortunately, partial or complete recurrence of the deformity during the process of healing was rather frequent.

Dr. Thomas Galloway was given credit by Fomon and associates,<sup>4</sup> and by Lierle and Huffman<sup>5</sup> for the next attack on this problem. The "Galloway procedure" consists of hemitransfixion, bilateral elevation, removal of the quadrangular cartilage in essentially one large piece with the swivel knife, removal of all bony deflections, retrograde dissection of a columellar bed, reinsertion of the removed cartilage into the septal pocket, drawing of the cartilage into the columellar bed by traction sutures, fixation of the cartilage, and closure of the incision by through-and-through mattress sutures. The main objections to the procedure were the artificial stiffness of the nasal tip produced by elimination of the membranous septum, the recurrent deflection produced by a short septal mucosal flap or scarring, and increased columellar thickness from the cartilage implant between the medial crura.

The "Fomon operation"<sup>4</sup> was next conceived to obviate the difficulties with the "Galloway procedure." A preserved cartilage graft was used in the columella in an attempt to conserve tip mobility and to prevent columellar retraction. A complete transfixion was employed in an attempt to equalize scar tissue formation. Multiple cartilaginous fragments were used in the septal pocket to break up the lines of scar contraction. At that time it was the contention of Fomon and associates<sup>4</sup> that the septum was not necessary for support, provided that septal cicatricial contraction could be prevented. Again, columellar thickening was produced by the batten, and occasionally a saddle deformity due to lack of adequate support resulted.



(Fig. 7)

In 1956, Goldman<sup>6</sup> described a technic essentially as follows: A low unilateral columellar incision with insertion of a mattress suture at the columellar base to prevent retraction, complete transfixion with bilateral complete elevation, division of the caudal septum into two ventrally attached flaps, medial bony displacement after basilar bony division with minimal resection, medial nasal spine displacement with minimal resection, reattachment of perichondrium by mattress sutures, and finally, reattachment of septum to columella. This technic is especially useful when a rhinoplasty with nasal shortening is desired in conjunction with the septal reconstruction, and when the caudal deformity is not a compound deformity but rather a simple displacement. In the severe cartilaginous deformity, sectioning into two components is often not sufficient to eliminate the deformity. Also, as noted by Farrior,<sup>7</sup> cartilage is lymph-nourished, and pedicle flaps without their attached perichondrium have, from a survival standpoint, little, if any, advantage over free cartilage grafts.

#### A Modified "Galloway Procedure"

The procedure I have used with satisfactory results during the last 13 years is a modification of the "Galloway procedure," and the total experience exceeds 200 cases. A complete transfixion is done at the level of the caudal border of the dislocation. Bilateral septal flaps are then elevated and the quadrangular cartilage is removed in one piece with the swivel knife, and is saved. All residual deflections are removed as in the standard Killian operation. The removed cartilage is then trimmed to obtain a straight portion as large as possible, the minimum dimensions being from the region of the nasal spine to the dorsum, and from the line of incision to the nasal bone. This cartilage graft is inserted into the septal pocket and then is brought down to but not into the columella (as no columellar pocket is made) by traction sutures. The cartilage is anchored in place and the incisions are closed by two mattress sutures, after which the traction sutures are removed. A final inspection is then made. Frequently a short septal flap, usually on the side of the original dislocation, is found. This flap is then severed from the floor of the nose by the use of Steven's tenotomy scissors, allowing the septum to assume a midline position. (In the first of these operations the exposed bone on the floor of the nose adjacent to the septum, produced by the release of the short septal flap, was covered with a mucosal graft removed from a turbinate. In recent years the mucosal graft has been eliminated, as it has proved to be unnecessary.) The nasal fossae are then equally packed to hold the flaps against the cartilage graft. Removal of packing is completed by the fourth day; sutures are removed on the fifth day; and the patient then is discharged from the hospital.

This technic allows for normal tip mobility without the stiffness or columellar thickening produced by the prior procedures. Recurrence of the deformity, produced by the usually present unilateral short septal flap, is avoided. The necessary cartilage support is provided. By careful dissection and cartilage removal, I

have not found it necessary to employ preserved cartilage in the last eight years, although two or more pieces of cartilage have been spliced together with fine catgut on a few occasions to secure an adequate graft. The procedure has been used with equal success in adults and in children, as young as the age of five years. I have seen no failure of normal nasal growth in these children. On the other hand, failure of normal nasal development with high-arched palate and crowded teeth frequently results from nasal obstruction during the period of active growth.

### Summary

A brief history of the development of nasal septal surgery has been presented, including what I consider to be the major milestones of this development. A modification and simplification of the "Galloway procedure" has been described, which has proved to be satisfactory in the author's experience with more than 200 patients in the last eight years. Representative results achieved are demonstrated.

### References

1. Sollmann, T. H.: A Manual of Pharmacology and Its Applications to Therapeutics and Toxicology, 7th ed. Philadelphia: W. B. Saunders, 1948, 1132 p.; p. 263.
2. Ballenger, W. L.: Diseases of the Nose, Throat and Ear; Medical and Surgical, 3d ed. Philadelphia: Lea & Febiger, 1911, 983 p.; p. 82-102.
3. Metzenbaum, M.: Replacement of lower end of dislocated septal cartilage versus submucous resection of dislocated end of septal cartilage. *Arch. Otolaryng.* **9**: 282-296, 1929.
4. Fomon, S.; Syracuse, V. R.; Bolotow, N., and Pullen, M.: Plastic repair of deflected nasal septum. *Arch. Otolaryng.* **44**: 141-156, 1946.
5. Lierle, D. M., and Huffman, W. C.: Reconstruction of nasal septum. *Laryngoscope* **59**: 858-872, 1949.
6. Goldman, I. B.: New technic in surgery of deviated nasal septum. *A.M.A. Arch Otolaryng.* **64**: 183-189, 1956.
7. Farrior, R. T.: Corrective surgery of nasal framework with emphasis upon septal surgery. *J. Florida M.A.* **45**: 276-289, 1958.