

# LYMPHANGIOGRAPHY IN THE EVALUATION AND TREATMENT OF TESTICULAR TUMORS

## Report of Two Representative Cases

JAMES R. GEYER, M.D.,\* and EUGENE F. POUTASSE, M.D.

*Department of Urology*

**L**YMPHANGIOGRAPHY has only recently become of great value in diagnosing and in treating certain diseases. It has not been in widespread use partly because the procedure is slow and tedious, the lymph vessels being small and containing only a small amount of colorless fluid. In 1955, Kinmonth, Taylor, and Harper<sup>1</sup> reported a method whereby a lymph vessel can be identified after the subcutaneous injection of a vital blue dye, so that when radiopaque material is injected directly it will outline the vascular course, the branches, and the regional lymph nodes. Their method has become a useful means of studying regional edema and primary and secondary neoplasms of lymphatics and lymph nodes by the recognition of an abnormal pattern of lymph node anatomy. Several applications of this procedure to urologic problems have been reported.<sup>2,3</sup> The purpose of our paper is to show how lymphangiography has been used in the evaluation and treatment of patients with metastatic testicular tumors.

### Technic

The technic for lymphangiography, devised by Kinmonth, Taylor, and Harper,<sup>1</sup> was modified slightly by Wallace and associates,<sup>2,3</sup> and is as follows. First, the surface of the foot to be injected is suitably cleansed, after which, 0.5 ml. of a 1 to 1 mixture of 0.5 per cent Evans Blue Dye† and 1 per cent procaine hydrochloride is injected intradermally in the web between the first and second digits of the foot. (Other satisfactory vital dyes are Alphasurine 2 G‡ and Direct Sky Blue§.) About 30 minutes later an incision is made on the dorsum of the foot. Lymphatic vessels containing blue dye may be seen just beneath the skin, and the largest one is isolated by blunt dissection (*Fig. 1*). It is helpful to compress the foot above the incision while massaging upward from the site of injection between the toes. This distends the lymphatic so it may be cannulated with a number 25 (or smaller) hypodermic needle, which is held in place with catgut ligatures. Then the needle is connected to a small syringe (a 1-ml. tuberculin syringe works well) with polyethylene tubing,

\*Formerly Fellow in the Department of Urology; present address: Oklahoma City Clinic, Oklahoma City 3, Oklahoma.

†Warner-Chilcott Laboratories.

‡Allied Chemical Co.

§Wyeth Laboratories.

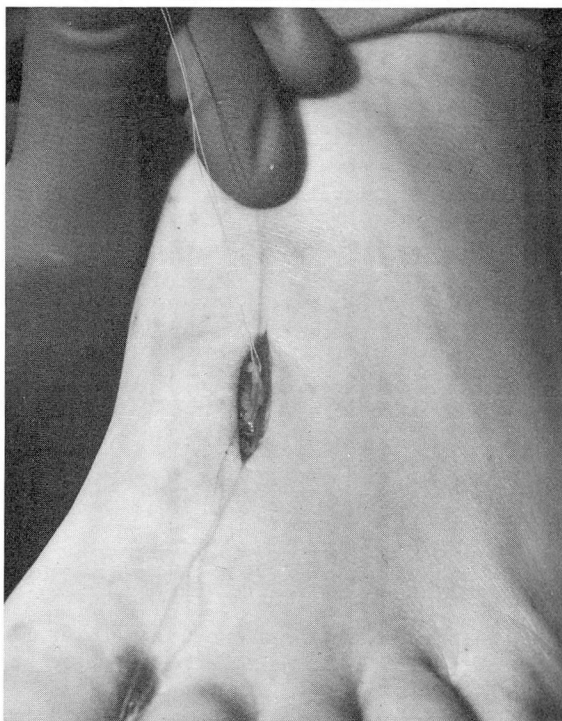


Fig. 1. A lymphangiogram was made after intradermal injection of a vital blue dye in the web of the left foot between the first and second digits; a lymphatic was visualized and is isolated through a small incision on the dorsum of the foot.

and from 10 to 15 ml. of Ethiodol\* is injected slowly over a period of from 30 to 60 minutes with only a little pressure, otherwise the lymphatic will rupture and the contrast material will extravasate. When a tuberculin syringe is used, repeated 1-ml. injections can be given using a reservoir and a three-way valve. When bilateral lymphangiograms are made, the total dose of Ethiodol should not exceed 25 ml. Although the Ethiodol may be injected manually, it is possible to use a constant-rate infusion apparatus.

Upon completion of the procedure the lymphatic is ligated with an absorbable suture, and the wound is closed with fine interrupted sutures. Standard kidney-ureter-bladder (KUB) roentgenograms taken immediately usually show evidence of the contrast material as far up as the iliac nodes, unless an obstruction is present. Roentgenograms from 4 to 24 hours later show evidence of more of the contrast material in the iliac nodes and in the para-aortic nodes.

#### Report of Two Representative Cases

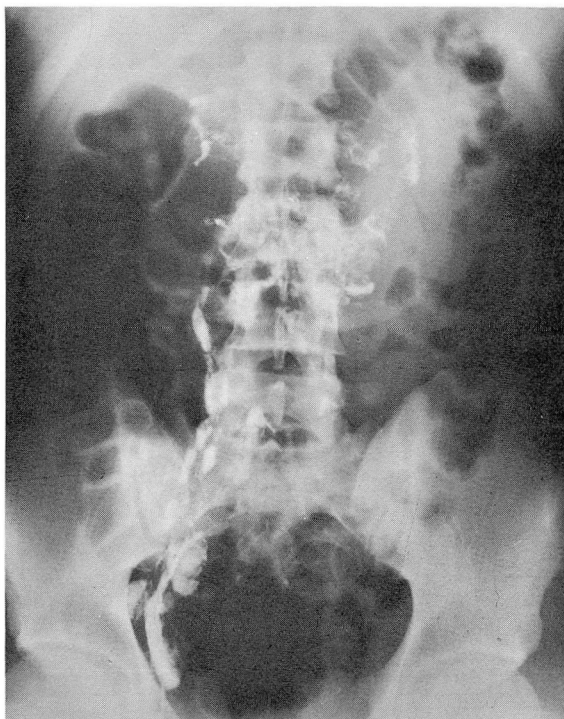
**Case 1.** A 20-year-old man, a college student, was referred to us through the courtesy of Dr.

\*E. Fougere & Co., Inc.

## LYMPHANGIOGRAPHY IN EVALUATION OF TESTICULAR TUMORS

George Moore, of Newcastle, Pennsylvania, on April 2, 1962, for further treatment of a teratocarcinoma of the testis. Right orchidectomy was done on March 19, 1962. The chest roentgenogram, intravenous urogram, and frog test for chorionic gonadotropins were reported to be normal or negative. There was no previous history of a serious illness or of other surgical treatment. Findings on the physical examination were normal, except for the absence of the right testis. No supraclavicular or abdominal masses were palpable.

The excretory urogram revealed evidence of slight lateral deviation of the right ureter just below the renal pelvis; this observation was of questionable significance. A lymphangiogram was obtained on April 3, 1962, and demonstrated extensive bilateral metastasis to para-aortic lymph nodes in the renal area (*Fig. 2*). Quantitative chorionic gonadotropins were later reported to be between 5,000 and 20,000 international units per liter.



**Fig. 2.** Case 1. Lymphangiogram showing irregular paravertebral distribution of small amounts of radiopaque material indicating replacement of lymph nodes by tumor—evidence of bilateral metastasis to para-aortic lymph nodes from teratocarcinoma of the right testicle.

On April 5, 1962, bilateral para-aortic lymphadenectomy was undertaken. All lymph nodes were removed between the twelfth thoracic and fourth lumbar vertebrae, lateral to the vena cava and the aorta, between these vessels, behind the vena cava and laterally along the renal pedicles. The mass of lymph nodes weighed 200 gm. In order to gauge the completeness of the lymph node dissection, a roentgenogram was made before the abdomen was closed (*Fig. 3 and 4*), which showed that there was no opaque material left in the para-aortic or the renal regions. The pathologic diagnosis of the excised lymph nodes was teratocarcinoma with microfoci of choriocarcinoma.



During the postoperative period the patient was given Methotrexate,\* 5 mg., and Chlorambucil,† 10 mg., orally each day for seven days, and a daily intravenous 0.5-mg. injection of Actinomycin D,‡ for five days except on the first two days of treatment with Methotrexate and Chlorambucil. Finally, cobalt 60 teletherapy§ was begun on April 17, 1962, with the object of treating first the inguinal, iliac, and para-aortic nodes with from 4500 to 5000 r in four or five weeks, then later, irradiation of the mediastinal and the supraclavicular nodes.

A left supraclavicular metastatic node developed before this area was irradiated; it was excised by Dr. Eldon R. Dykes, of the Department of Plastic Surgery, and showed teratocarcinoma. Five months later, a chest roentgenogram demonstrated no metastasis; a frog test was negative; no mass was palpable; and blood counts were normal. The patient received a course of triple-drug chemotherapy, which should be repeated at periodic intervals in the years to come.

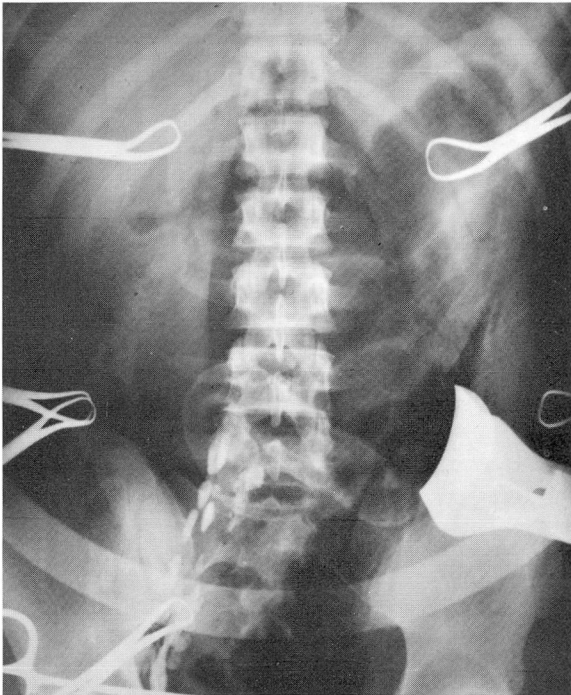

Fig. 3. Case 1. An operative roentgenogram that shows the completeness of lymph node dissection.

*Comment.* Lymphangiography demonstrated bilateral para-aortic lymph node metastasis that was not apparent on physical examination or on excretory urograms, except for slight lateral deviation of the right ureter. The need for prompt and extensive therapy was thus demonstrated: choriocarcinoma of the testicle has an extremely poor prognosis, almost all patients succumbing to it within two years of the time of diagnosis. The presence of radiopaque material in the

\*Lederle Laboratories.

†Leukeran, Burroughs Wellcome & Co.

‡New name (Lyo) Meractinomycin-D, supplied through the courtesy of Elmer Alpert, M.D., Merck Sharp & Dohme, West Point, Pennsylvania.

§The radioactive material was obtained on authorization of the United States Atomic Energy Commission, Washington, D.C.

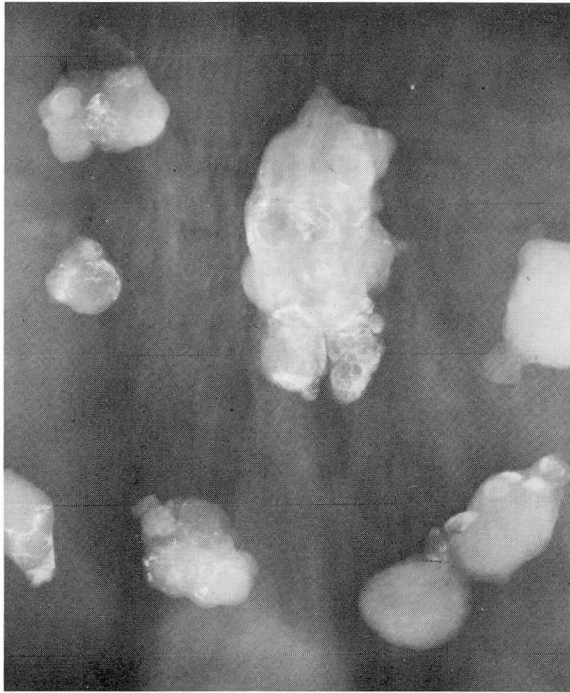


Fig. 4. Case 1. Roentgenogram of excised nodes showing that they contain only small amounts of contrast material because they were almost totally replaced by tumor.

lymph nodes was an aid in gauging the completeness of the lymph node dissection, judging from the absence of radiopaque material on an operative roentgenogram. Chemotherapy was administered for its possible beneficial effect in potentiating the cobalt 60 irradiation of this malignant type of tumor.

Case 2. A 50-year-old farmer was examined on August 23, 1961, because of abdominal pain in the left upper and left lower quadrants, and left lumbar backache for approximately five months. During that time he had lost 10 pounds in weight.

In the left upper quadrant of the abdomen was a hard, fixed, nontender mass, 3 in. by 3 in., which transmitted the aortic pulse. Except for an atrophic left testicle that had been small and unchanged for many years according to the patient, the remainder of the physical findings were normal. The blood counts, blood sugar and blood urea concentrations, and urinalysis were normal. A plain roentgenogram of the abdomen revealed no evidence of abnormality, but upper gastrointestinal roentgenograms demonstrated an extrinsic pressure defect on the lesser curvature of the stomach. Chest and colon roentgenograms were normal.

On August 31, 1961, an exploratory laparotomy was performed by Dr. Richard C. Britton\* of the Department of General Surgery. A large retroperitoneal tumor was found which surrounded the upper portion of the left ureter and kidney in such a way it was considered irre-

\*Formerly Member of the Staff, present address: Department of Surgery, College of Physicians and Surgeons, Columbia University, New York, New York.

movable, particularly since the status of the right kidney was not known. The diagnosis on frozen section of the biopsy specimens was embryonal carcinoma, and the mass was marked with silver clips in anticipation of cobalt 60 therapy. A postoperative intravenous urogram showed evidence of a normal right kidney, but no excretion of contrast medium by the left kidney. No primary site of the tumor could be found on examination, even though attention was now focused on the testicles. A tumor dose of 4000 r of cobalt 60 was given to the previously outlined left retroperitoneal area.

When the patient was examined on April 4, 1962, he reported a recent recurrence of abdominal pain in the left upper and left lower quadrants, night sweats, and pain in the left testis. He had gained 6 pounds in weight. A small, hard mass was felt in the left lower quadrant of the abdomen. The atrophic left testis now contained a small hard nodule. A frog test for chorionic gonadotropins was negative. The chest roentgenogram showed no evidence of metastasis. The intravenous urogram showed evidence of a normal right kidney and delayed function and dilatation of the pelvis and calyces of the left kidney; by outline this kidney appeared smaller than on previous roentgenograms.

Lymphangiography was performed on April 9, 1962. Radiopaque material did not pass up to the left para-aortic nodes, apparently because of the fibrosis secondary to cobalt 60 teletherapy. (Fig. 5). Less than the usual number of lymph nodes was visualized in the left iliac region. There was evidence of opaque material in the palpable mass.

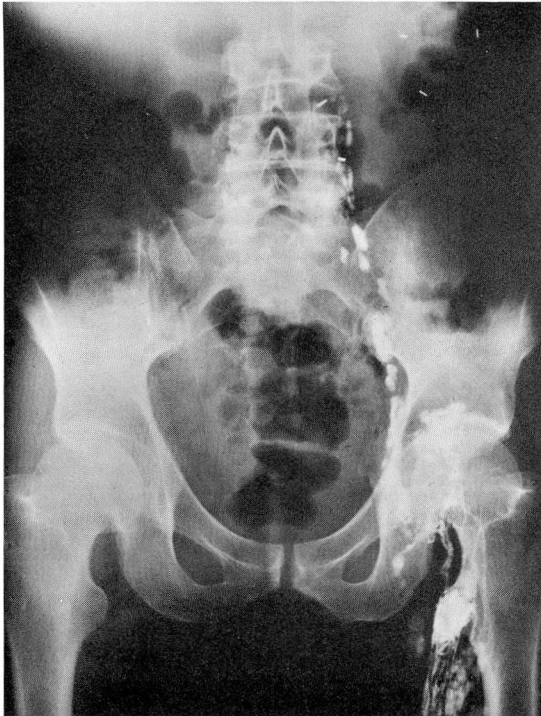


Fig. 5. Case 2. Lymphangiogram showing that the contrast material failed to pass into nodes that became necrotic and fibrosed after irradiation with cobalt 60 teletherapy. The silver clips had been placed on the mass when a biopsy specimen was taken before cobalt 60 teletherapy.



Left orchiectomy and exploratory laparotomy were undertaken on April 11, 1962. The abdominal mass, which had been palpable in the left lower quadrant preoperatively, consisted of an enlarged superficial left iliac lymph node. Evidently there was a lymphatic obstruction between the superficial and deep iliac nodes. The retroperitoneal mass found at the previous operation has been almost completely obliterated by the cobalt 60 therapy. The left kidney, the upper portion of its ureter, and the shrunken para-aortic lymph nodes were encased in fibrotic tissue. On microscopic examination, the lymph nodes contained necrotic material without evidence of viable neoplasm. Biopsy of the left kidney revealed tubular atrophy. The left testis and spermatic cord were removed; the left iliac nodes were completely excised; and left ureterolysis was accomplished. The pathologic diagnosis of the testis and the iliac nodes was embryonal carcinoma.

Postoperatively the patient was given a course of Methotrexate, Chlorambucil, and Actinomycin D, and was started on a course of cobalt 60 teletherapy to the left inguinal, iliac, and para-aortic nodes in the abdomen and mediastinum, omitting the previously treated area. Unfortunately, the patient died abruptly three months later of an intestinal perforation that resulted presumably from irradiative ulceration of the intestine.

*Comment.* Although the lymphangiogram did not outline a neoplastic mass in the inguinal region, the roentgenographic findings could be correlated with the operative findings, and greatly aided in the planning of the postoperative therapy. The original para-aortic metastasis had been obliterated by the previous course of cobalt 60 teletherapy, and Ethiodol would not pass into those necrotic and fibrosed nodes. The left iliac nodes, which had not been irradiated before, contained metastatic lesions.

Extensive retroperitoneal metastasis may occur from a testicular tumor so tiny that it cannot be detected by careful examination of the testis. Sometimes the original tumor may undergo necrosis, so that the primary or original lesion consists only of a fibrous scar in which viable neoplasm is minute or absent.<sup>4</sup>

## Discussion

In contrast to veins, which become larger cephalad, lymphatics maintain the same caliber in their course up the limb. However, lymph trunks bifurcate and multiply as they pass upward. In the lower extremities they parallel the greater and lesser saphenous veins. When contrast material is injected into a foot, the inguinal, iliac, and para-aortic nodes are outlined. The lymphatics, in some patients, begin to cross over to the opposite side even as low as the upper part of the sacrum, to form the cisterna chyli, but the level of crossover varies considerably. The thoracic duct is sometimes visualized, but the visceral nodes, such as the mesenteric and mediastinal nodes, are not seen. The lymphatic pattern is best seen on early films, while that of the nodes is best seen on later films.

Embryologically the testis descends from the retroperitoneal area near the kidney through the inguinal canal into the scrotum. It takes its principal vascular supply as well as lymphatics from its site of origin, so that lymphatic metastasis from a testicular tumor is apt to be present first in the para-aortic nodes near the renal pedicle. There, tumor spreads easily to the opposite side via crossover lymphatics, and may enter the thoracic duct and appear in the supraclavicular nodes

soon afterward. These regions that are primarily considered for lymph node dissection are shown on a plain roentgenogram of the kidney, ureter, and bladder, during lymphangiography.

Ethiodol outlines only the normally functioning lymphoid tissue. A normal iliac, inguinal, or para-aortic node is globular or renal shaped, is 1.5 cm. in its maximum diameter, and shows a homogeneous reticular pattern of opaque material. If the lymph nodes are invaded by metastatic carcinoma, they are increased in size and have filling defects, giving them an appearance described by the terms "moth-eaten" or "mouse bite" in case of partial replacement by tumor, and "ghostlike" when only the periphery of the node is filled with contrast material. According to roentgenograms, the oily opaque material remains in normal nodes for four weeks, and in nodes with metastasis for from four to six months.

The complications of lymphangiography, according to Wallace and associates,<sup>2</sup> are lymphangitis, wound infection, granulomatous foreign-body reaction to lipid material in nodes removed at surgery, and iodine sensitivity. Fine pulmonary embolization of oily contrast material has been reported to occur rarely soon after the injection has been completed; therefore, a chest roentgenogram should be made. Some of the patients have experienced fever and chills after the procedure. Because there is a definite risk of infection, antibiotics are routinely administered.

The urologic applications of lymphangiography were reported by Schaffer and associates.<sup>3</sup> They performed lymphangiography in 37 patients who had tumors of the testis, prostate, bladder, penis, or kidney, or other urologic diseases. They have found lymphangiography valuable for detecting metastatic malignancy without palpable nodes, in deciding on the appropriate surgical procedure, in evaluating the completeness of lymph node dissection at the time of operation, and in planning radiotherapy.

### Summary

The technic and use of lymphangiography in patients with testicular tumors is illustrated by two case reports in which this procedure was an aid in planning treatment. In one patient, clinically unsuspected metastasis from a testicular teratocarcinoma to the para-aortic lymph nodes was detected. In the second patient, lymphangiography correctly indicated obliteration of retroperitoneal embryonal carcinoma metastasis by cobalt 60 teletherapy.

### References

1. Kinmonth, J. B.; Taylor, G. W., and Harper, R. K.: Lymphangiography; technique for its clinical use in lower limb. *Brit. M. J.* 1: 940-942, 1955.
2. Wallace, S.; Jackson, L.; Schaffer, B.; Gould, J.; Greening, R. R.; Weiss, A., and Kramer, S.: Lymphangiograms: their diagnostic and therapeutic potential. *Radiology* 76: 179-199, 1961.



## LYMPHANGIOGRAPHY IN EVALUATION OF TESTICULAR TUMORS

3. Schaffer, B.; Gould, R. J.; Wallace, S.; Jackson, L.; Ivker, M.; Leberman, P. R., and Fetter, T. R.: Urologic applications of lymphangiography. *J. Urol.* **87**: 91-96, 1962.
4. Azzopardi, J. G.; Mostofi, F. K., and Theiss, E. A.: Lesions of testes observed in certain patients with widespread choriocarcinoma and related tumors; significance and genesis of hematoxylin-staining bodies in human testis. *Am. J. Path.* **38**: 207-225, 1961.