

THROMBOSIS OF THE PORTAL VEIN WITH RECANALIZATION IN HEPATIC CIRRHOSIS

CHARLES H. BROWN, M.D.,

Department of Gastroenterology

RICHARD C. BRITTON, M.D.,*

Department of General Surgery

FRED F. WHITCOMB, JR., M.D.,† and RASIM TURKSEL, M.D.‡

Department of Gastroenterology

ACUTE thrombosis of the portal vein has been reported as a complication occurring in from 10 to 20 per cent of patients with cirrhosis of the liver.¹⁻⁹ Symptoms and findings vary in relation to the type of onset of thrombosis and to the stage of hepatic disease. Although the complication is relatively rare, the true incidence is difficult to determine because diagnosis usually is not made with certainty before the death of the patient.

The dual purpose of this paper is to report the case of a patient with hepatic cirrhosis in whom an acute portal vein thrombosis developed, proved by means of splenoportography both before and after recanalization, and to describe the nature of the symptoms that initially led us to suspect this diagnosis.

Report of a Case

A 39-year-old man was admitted to the hospital in November, 1959, because of anorexia, bloating, and intermittent cramping in the region of the umbilicus, of one year's duration. The abdominal pain had increased during the month before admission, having been so severe as to have awakened the patient at night several times. Three weeks before admission, jaundice without itching, tremulousness, and abdominal distention developed, and the urine became dark. The patient reported having consumed five or six highballs daily during the past 10 years, but there was no previous history of jaundice, hepatic disease, or ingestion of chlorpromazine hydrochloride. Except for nervousness and intermittent episodes of hyperventilation, he had been in good health until the onset of his present illness.

On physical examination the patient had a cushingoid appearance, was jaundiced, and tremulous. He was mildly febrile, had a regular pulse rate of 100, and normal blood pressure. Spider nevi, palmar erythema, and mild gynecomastia were present. The edge of the liver was palpated 9 cm. below the right costal margin, and was regular, firm, and slightly tender. The spleen could not be palpated initially, probably because of the presence of pronounced ascites. Superficial abdominal veins were distended, and minimal ankle edema was present. The testes were normal in size.

*Formerly Member of the Staff; present address: Department of Surgery, College of Physicians and Surgeons, Columbia University, New York, New York.

†Formerly Member of the Assistant Staff; present address: Labey Clinic, Boston, Massachusetts.

‡Formerly Special Fellow in the Department of Gastroenterology; present address: The Royal Edward Laurentian Hospital, Box 400, Ste.-Agathe-Des-Monts, Quebec, Canada.

On admission to the hospital, the blood hemoglobin value was 12.9 gm. per cubic milliliter, with a cell volume of 39 ml. per 100 ml. The white blood cell count was 20,000 per cubic millimeter, with 88 per cent polymorphonuclear cells. The urine contained bile but otherwise was normal. Results of liver function tests are reported in *Table 1*. The blood urea concentration was 20 mg. per 100 ml., and the fasting blood sugar concentration was 84 mg. per 100 ml. The

Table 1.—*Results of liver function tests*

Test	Date of test				
	1959		1960		1961
	Nov. 25	Dec. 31	March 15	May 17	March 2
Bilirubin, mg. / 100 ml.					
Direct	1.4	0.1	0.3	0.1	0
Indirect	1.2	0.5	0.5	0.7	0.3
Serum alkaline phosphatase, Bodansky units	7.3	4.2	4.2	3.0	0.3
Ammonia—N, μ g. / 100 ml.	57.0	—	—	—	—
Urine urobilinogen, Ehrlich units	0.5	—	—	—	—
Serum albumin, gm. / 100 ml.	2.95	3.93	4.56	4.60	5.91
Serum globulin, gm. / 100 ml.	2.80	2.69	2.30	2.10	1.99
Serum gamma-globulin, gm. / 100 ml.	1.25	1.38	1.00	0.97	0.80
Serum cholesterol, mg. / 100 ml.	165.0	—	—	—	—
Prothrombin time, seconds	17	20	17	14	15
Prothrombin time control, seconds	13	14	13	13	13
Sulfobromophthalein sodium retention after 45 minutes, %	—	33	10	7	13
Thymol turbidity, units	1.9	3.0	3.0	2.0	3.0
Cephalin-flocculation	2+	1+	1+	Neg.	Neg.
SGO transaminase, units	170	20	17	25	20

lupus erythematosus clotting test, serologic tests for syphilis, febrile agglutinations, bleeding and clotting times, serum electrolyte values, chest roentgenograms, electrocardiogram, and bone marrow examination were either negative or within normal limits. A roentgenogram showed evidence of varices in the distal third of the esophagus. A biopsy specimen of the liver was diagnostic of Laennec's cirrhosis (*Fig. 1*).

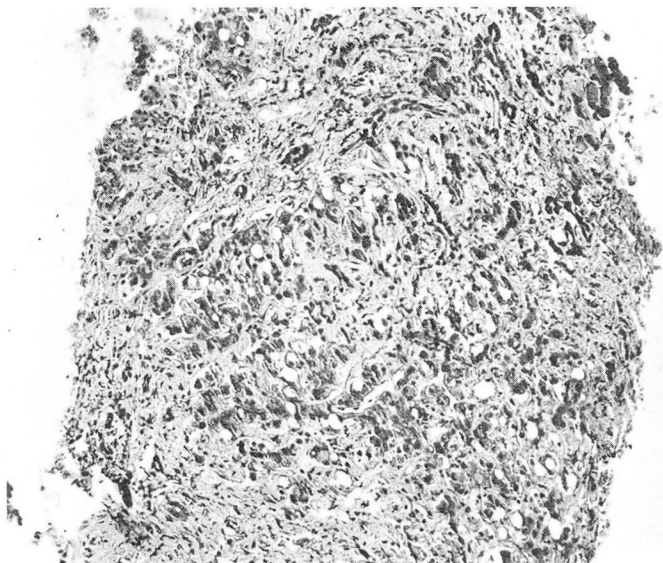


Fig. 1. Photomicrograph of a specimen of needle biopsy of the liver, showing gross distortion of the liver, increased connective tissue, and some vacuolization and fatty changes in the hepatic cells. Magnification X 125.

Treatment consisted of a high-protein, low-sodium (500 mg. daily) diet with protein supplements, vitamins, and diuretics. A single paracentesis produced 2 liters of clear and sterile ascitic fluid. Despite this treatment, the patient continued to be febrile, with spiking temperatures to 101 F., and the white blood cell count consistently was more than 15,000 per cubic millimeter. Because of the atypical course of the disease, a splenoportogram was obtained on December 23, 1959; it demonstrated normal splenic and inferior mesenteric veins; there was no evidence of contrast medium in the portal system or in the liver (*Fig. 2*). It was concluded from this study that the bizarre course of the disease was probably caused by a thrombosis of the extrahepatic portal vein.

Medical treatment was continued. The fever, jaundice, and ascites subsided slowly, and the white blood cell count approached normal limits. On December 31, 1959, after 39 days in the hospital, the patient was discharged. At that time, results of liver function tests showed improvement (*Table 1*). Treatment was continued on an outpatient basis, and by the summer of 1960 the patient had regained his appetite, had only mild ascites, and was working eight hours daily. The liver had decreased in size and the edge now descended only 3 or 4 cm. below the right costal margin. The edge of the spleen could now be palpated 2 cm. below the left costal margin. On July 28, 1960, the patient was readmitted to the hospital for a second splenoportogram, which showed evidence of some recanalization of the portal vein thrombosis. Contrast medium was now visualized in the portal vein and throughout the hepatic parenchyma (*Fig. 3*).

Progress continued to be excellent. A third splenoportogram (*Fig. 4*) obtained on March 2,

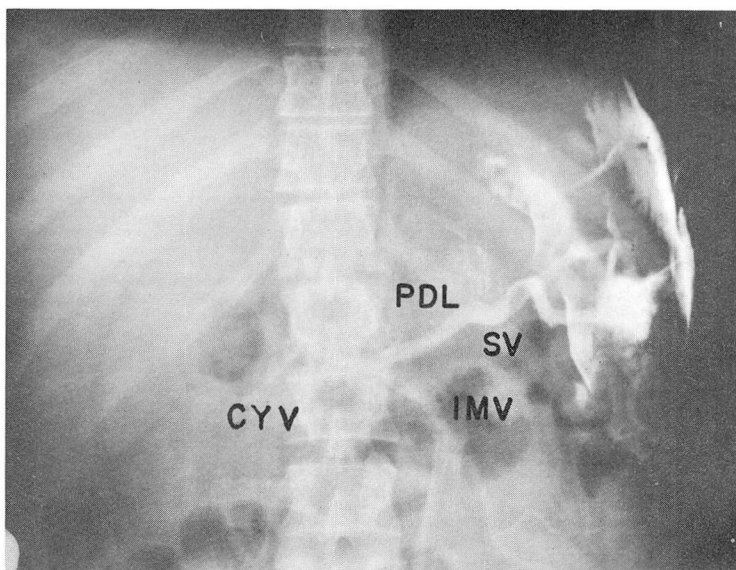


Fig. 2. Film taken four seconds after injection of 30 ml. of 50 per cent Hypaque sodium, showing nonvisualization of the portal vein, but with preferential filling of the inferior mesenteric vein (IMV) and secondary filling of small vasa brevia, the cystic veins (CYV), and anastomoses between the pancreaticoduodenal veins (PDL) and the lumbar veins. There is extravasation of the contrast material subdiaphragmatically. (SV, splenic vein).

1961, shows evidence of complete recanalization of the portal vein with the virtual absence of collateral veins. The ascites had disappeared, the liver was only slightly palpable, and the spleen was not enlarged. Laboratory studies showed further improvement in liver function, and a roentgenogram of the esophagus revealed no evidence of varices.

Discussion

Clinical symptoms and findings associated with portal vein thrombosis depend upon the rapidity and extent of the occlusive process. Rapidly propagating thrombosis involving the main portal trunk and its major tributaries, particularly the superior mesenteric vein, may follow trauma, splenectomy, acute hepatitis, pylephlebitis, congestive heart failure, polycythemia vera, or extrinsic compression of the portal vein by mass or cyst. The clinical picture of acute portal thrombosis results from acute venous splanchnic congestion usually causing generalized abdominal pain, nausea and vomiting, bloody diarrhea, ascites, and ileus. Mesenteric thrombosis leading to shock and death occurs when the development of collateral venous drainage is not sufficiently rapid to provide adequate drainage of the splanchnic bed.⁷

Acute portal thrombosis in the presence of established portal-systemic collateral drainage, as may occur with cirrhosis,^{8,9} may produce no symptoms. Clinically unsuspected portal vein thrombosis is found at autopsy in from 10 to 20 per cent

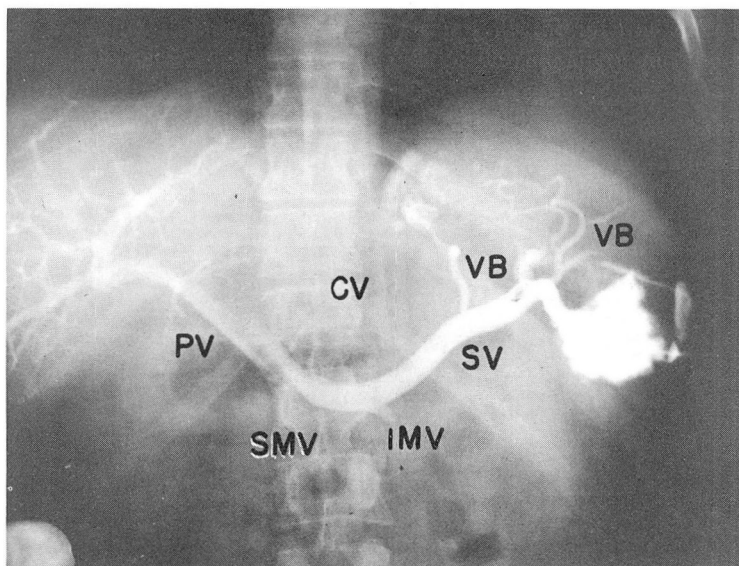


Fig. 3. Film taken four months after that shown in *Figure 2*, with identical technic. Six seconds after injection there was filling of the right main portal trunk (PV), an anomalous double coronary vein (CV), and a large vasa brevia (VB). There is absence of filling of the left portal trunk. The filling defect at the origin of the main portal trunk resulted from the inflow of blood containing no contrast medium from the superior mesenteric vein (SMV).

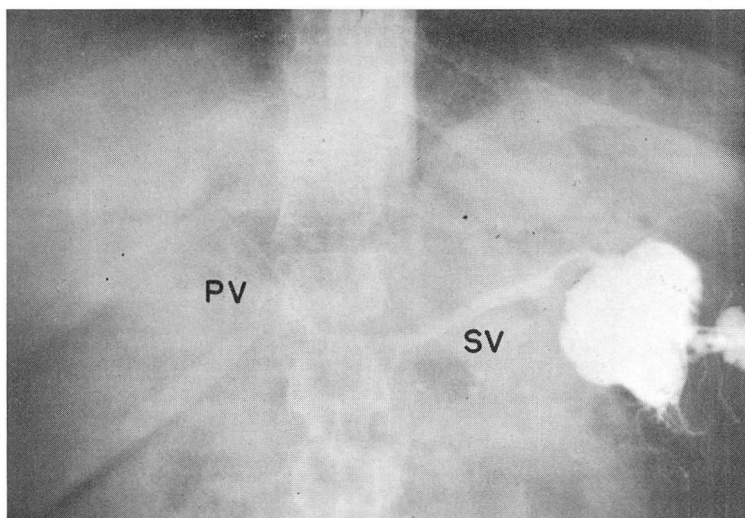


Fig. 4. Film taken one year after that shown in *Figure 2*. Six seconds after injection there was appearance of contrast medium at the porta hepatis with filling of the main portal trunk and both right and left intrahepatic portal radicals. The previously noted collateral channels had disappeared.

of chronic cirrhotics. A slowly propagating thrombotic process may occur in association with neonatal septic omphalitis with extension along the ductus venosus to involve the portal trunk. A common finding in such patients is recanalization of intrahepatic branches of the portal vein with extensive collateral development in the hepatoduodenal ligament, termed "cavernous transformation."¹⁰⁻¹²

In the case presented in this report, the onset of generalized abdominal pain, diarrhea, ascites, fever, and leukocytosis apparently followed rather sudden, non-septic thrombosis of the portal vein. The rapid development of collateral channels prevented the usual chain of disastrous effects, although splenomegaly, esophageal varices, and other evidence of acute portal hypertension were apparent. The immediate collateral routes available in this patient were the inferior mesenteric vein anastomosing with superior and middle hemorrhoidal plexuses of the internal iliac system, the cystic veins anastomosing with pancreaticoduodenal veins draining into the lumbar system, and the vasa brevia draining into the hemi-azygos system. Of interest is a further adaptation: in the splenoportogram taken four months later there is evidence of enlargement of the coronary and vasa brevia systems with no longer any filling of the inferior mesenteric venous system.

Since the introduction of percutaneous splenoportography by Abeatici and Campi¹³ in 1951, the diagnosis of portal vein thrombosis may be made with safety and fair accuracy,^{14,15} but the diagnosis has certain pitfalls. Unlike other angiographic studies in which injection pressure modifies the filling pattern by forcing retrograde flow, contrast material injected into the splenic pulp, streams from it along the pathways of least resistance. The sine qua non in angiographic diagnosis of portal vein occlusion is the demonstration of collateral veins on the splanchnic side of the suspected occlusion. The splenoportogram taken initially in our patient (*Fig. 2*), outlined the splenic vein as far as its junction with the superior mesenteric vein, at which point filling of cystic and pancreaticoduodenal collateral vessels was apparent in addition to filling of the inferior mesenteric vein and the vasa brevia. The short thick stature of the patient rendered contrast densities less sharp than usual, and clarity has suffered further with reproduction of the films. A better example is demonstrated by a splenoportogram in another patient with chronic portal vein occlusion confirmed at operation (*Fig. 5*).

A lack of filling of the portal vein during percutaneous splenoportography does not necessarily indicate portal vein thrombosis, but may occur in the presence of a large patent side-to-side portacaval shunt, severe intrahepatic resistance to flow, or a large collateral vessel that carries the greatest part of splanchnic flow. In these circumstances there is usually no evidence of collateral veins about the porta hepatis, even with serial film technic.

The prognosis of patients who have survived acute portal vein thrombosis depends primarily upon the underlying disease, and secondarily upon the risk of bleeding from esophageal varices if portal vein occlusion and portal hypertension

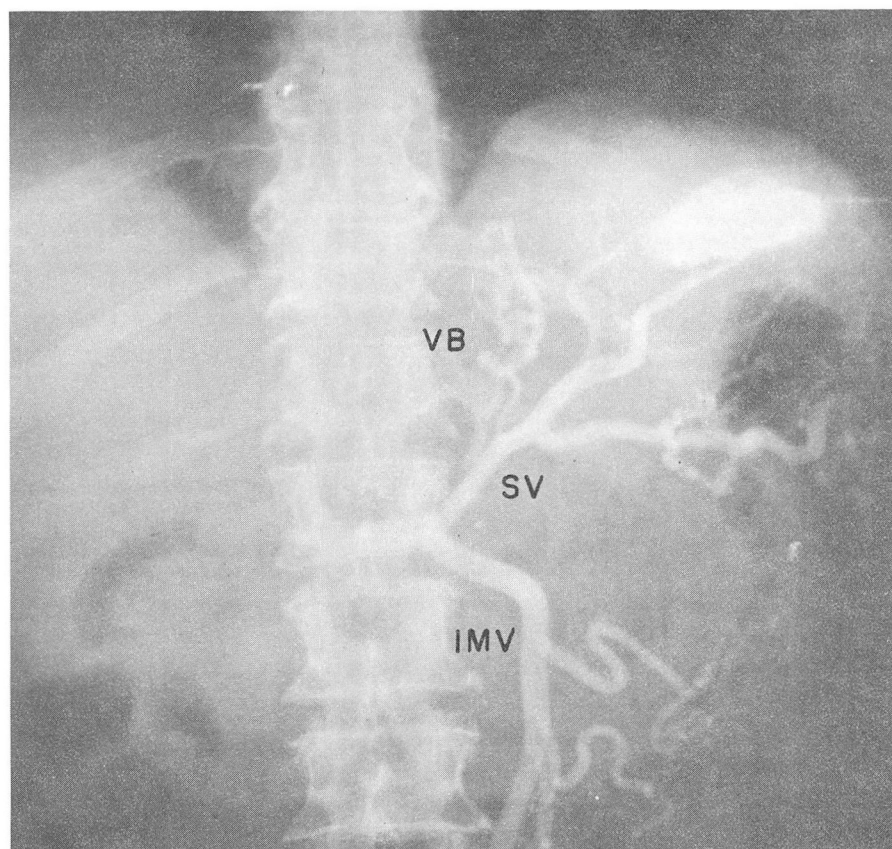


Fig. 5. Percutaneous splenoportogram of a patient with portal vein thrombosis proved at operation. Note the inferior mesenteric vein larger than the splenic vein, as well as filling of small vasa brevia (VB). In this patient the superior mesenteric vein was patent and emptied into the short segment of splenic vein, thence down the inferior mesenteric vein.

persist. Recanalization of the portal thrombosis, as occurred in our patient, is unusual. We have observed splenoportographic evidence of portal vein recanalization in only three of 97 patients studied.

Summary

This report presents the case of a patient with alcoholic cirrhosis in whom acute portal vein thrombosis developed with subsequent recanalization. The complication of acute portal vein thrombosis was suspected on the basis of rapid onset of abdominal pain, splenomegaly, ascites, fever, and leukocytosis. Serial splenoportography demonstrated a lack of filling of the portal vein, which seemed consistent with thrombosis. There was subsequent recanalization of the portal vein.

References

1. Hunt, A. H., and Whittard, B. R.: Thrombosis of portal vein in cirrhosis hepatis. *Lancet* 1: 281-284, 1954.
2. Liebowitz, H. R.: Symptomatology of portal vein thrombosis and of extrahepatic portal hypertension generally, chap. 18, p. 488-514, *in* Bleeding Esophageal Varices; Portal Hypertension. Springfield, Illinois: Charles C Thomas, 1959, 986 p.
3. Linton, R. R.: Portacaval shunts in treatment of portal hypertension, with special reference to patients previously operated upon. *New England J. Med.* 238: 723-727, 1948.
4. Schiff, L., editor: Diseases of the Liver. Philadelphia: J. B. Lippincott Co., 1956, 738 p.
5. Shumacker, H. B., Jr., and King, H.: Splenic studies; portal hypertension in children associated with gastroesophageal hemorrhage. *A.M.A. Arch. Surg.* 65: 499-510, 1952.
6. Walker, R. M.: Portacaval anastomosis. *Lancet* 1: 57-59, 1957.
7. Simonds, J. P.: Chronic occlusion of portal vein. *Arch. Surg.* 33: 397-424, 1936.
8. Kelsey, M. P.; Robertson, H. E., and Giffin, H. Z.: Role of chronic thrombosis of portal vein and its tributaries in syndrome of splenic anemia. *Surg. Gynec. & Obst.* 85: 289-293, 1947.
9. Webster, L. T.: Portal thrombosis. *Bull. Johns Hopkins Hosp.* 32: 16, 1921.
10. Gibson, J. B., and Richards, R. L.: Cavernous transformation of portal vein. *J. Path. & Bact.* 70: 81-96, 1955.
11. Parker, R. A., and Seal, R.M.E.: Cavernous transformation of portal vein. *J. Path. & Bact.* 70: 97-103, 1955.
12. Baggenstoss, A. H., and Wollaeger, E. E.: Portal hypertension due to chronic occlusion of extrahepatic portion of portal vein; its relation to ascites. *Am. J. Med.* 21: 16-25, 1956.
13. Abeatici, S., and Campi, L.: La visualizzazione radiologica della porta per via splenica (nota preventiva). (Radiological visualization of portal system by splenic route.) *Minerva Med.* 42: 593-594, 1951.
14. Zeid, S. S.; Felson, B., and Schiff, L.: Percutaneous splenoportal venography, with additional comments on transhepatic venography. *Ann. Int. Med.* 52: 782-805, 1960.
15. Bergstrand, I.: Splenoportography, sec. 12, chap. 50, p. 655-695, *in* Abrams, H. L. editor: Angiography, vol. 2. Boston: Little, Brown and Co., 1961, 807 p.