

PERCUTANEOUS RETROGRADE CAROTID ARTERIOGRAPHY: A NEW TECHNIC

JOHN S. COLLIS, M.D.,* and W. JAMES GARDNER, M.D.

Department of Neurological Surgery

ROENTGENOGRAPHIC demonstration of arteries in the neck, the chest, and the upper extremities is possible with a new technic (*Fig. 1*) that is safe, simple, and is easily performed.

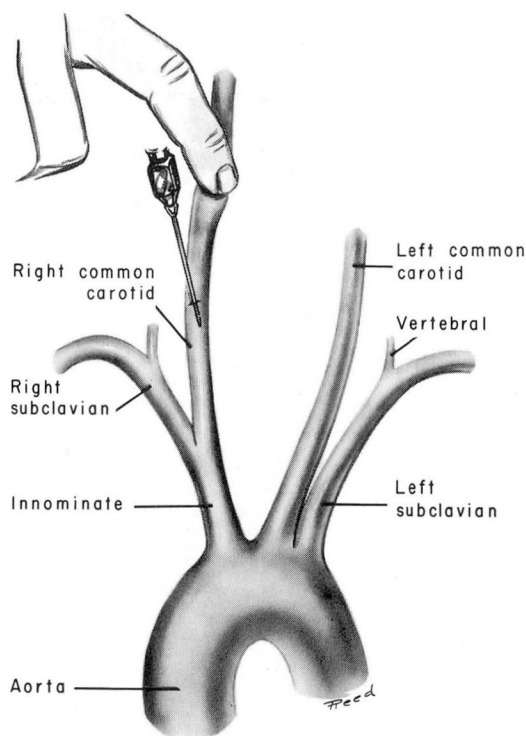


Fig. 1. Sketch showing the technic of retrograde injection of the common carotid arteries. In this case the right carotid artery is prepared for injection.

Initially we employed retrograde injections of the carotid arteries to visualize the origin of the carotid artery. We discovered that injection of the right carotid artery permitted visualization of the innominate, subclavian, vertebral, and brachial arteries, while injection of the left carotid artery permitted visualization not only of the carotid take-off, but also of the descending aorta and, occasionally, the left subclavian artery. The courses of these vessels could be conveniently studied.

*Fellow in the Department of Neurological Surgery.

Retrograde injections were used in a series of 16 patients as an aid in diagnosing atherosclerotic lesions. No unfavorable side-effects were produced.

Technic

Endotracheal anesthesia was used in 14 patients, and local anesthesia with 1 per cent procaine hydrochloride, was used in 2 patients.

In the anesthetized patient, a No. 18 gauge needle is inserted percutaneously in the common carotid artery. Any technic for carotid artery puncture may be used for retrograde studies, but the needle should be inserted into the carotid artery pointing downward (*Fig. 2*).

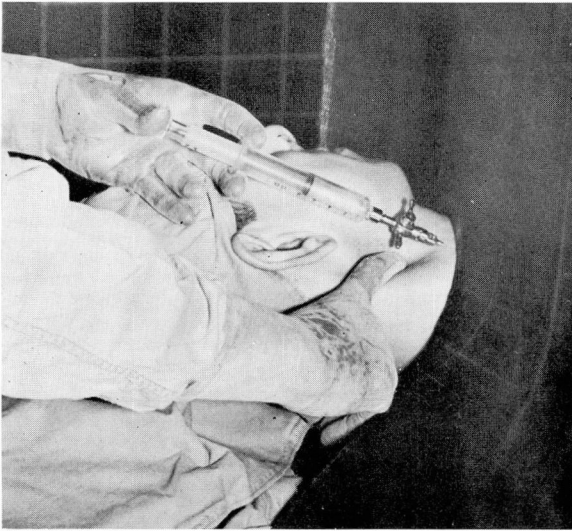

Fig. 2. Photograph showing retrograde injection of the right carotid artery.

The patient's chin should be slightly rotated to the side opposite injection, to give the operator accessibility to the distal common carotid artery for compression. Manual compression is applied to the artery above the needle puncture. Obstructing the cephalad flow permits more contrast medium to be sent toward the origin of the carotid artery.

For injections of the right carotid artery, a blood-pressure cuff should be placed on the right arm and should be inflated above the patient's systolic pressure. This will obstruct the brachial flow and will permit concentration of the contrast medium in the innominate and right vertebral arteries. For injections of the left carotid artery, occlusion of the left brachial artery is useless because of the direct aortic origin of the left common carotid artery.

For demonstration of either the right or left side the contrast medium is injected rapidly, and while the last milliliter is being injected a roentgenogram is made

(Fig. 3A and B). A rubber-lead shield is used to protect the operator's hands from radiation.

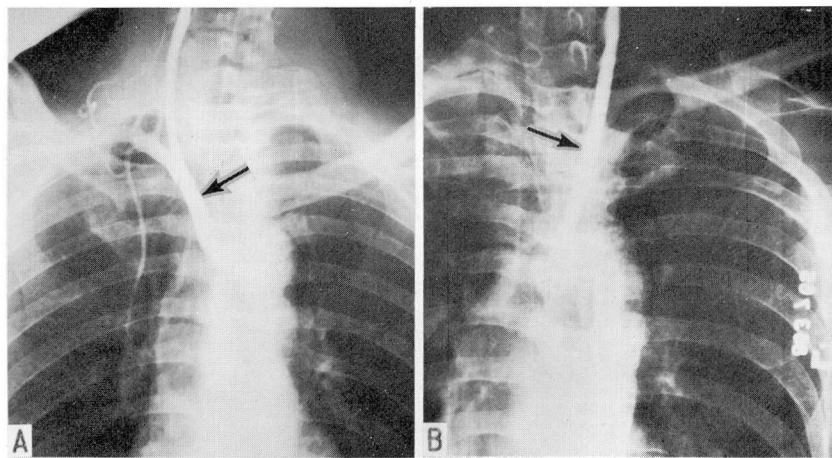


Fig. 3. A, Right retrograde carotid arteriogram showing common carotid, vertebral, subclavian arteries, and branches; the innominate artery is indicated by the arrow. B, Left retrograde carotid arteriogram showing the left common carotid artery (indicated by the arrow) and the descending aorta.

From 10 to 20 ml. of 50 per cent Hypaque* is adequate. Serial films may be started during mid-injection, but probably add little or no information to the single anteroposterior exposure centered over the sternal notch.

Arterial compression may not be necessary. Retrograde injections without compression were carried out in 3 of the 16 patients, because of thrombosis of the opposite internal carotid artery. Carotid take-offs were adequately demonstrated in two of those three patients.

Discussion

Formerly, retrograde injection of the right carotid artery was employed to visualize structures in the posterior fossa, via indirect filling of the right vertebral artery. This procedure was described by Moniz, Pinto, and Alves¹ and later modified by Elvidge.² No roentgenographic demonstration was given of the pathway of the contrast medium during the retrograde injection.

Retrograde injection of the left side apparently has not been previously described. Such an injection would rarely demonstrate the left vertebral artery, because the left carotid and left subclavian arteries arise separately from the aorta. The early investigators were interested not in atherosclerotic lesions, but in visualization of the posterior fossa, so did not pursue retrograde injections of the left carotid artery.

The great vessels of the neck may be outlined by direct aortic puncture,³ or by retrograde arterial catheterization.⁴ These are more formidable procedures than

*Hypaque sodium 50%, Winthrop Laboratories.

percutaneous retrograde carotid arteriography.

Direct injection of the subclavian artery is not hazardous if the needle is directed medially, away from the apex of the lung.⁵ The subclavian artery is less accessible than the carotid artery, and the injection of the left subclavian artery probably will not demonstrate the left carotid artery. If complete arterial visualization in the neck is desired, both a right and a left retrograde carotid and a left subclavian arteriogram are performed.

In performing a retrograde injection, it is technically more advantageous to direct the needle caudad than to direct it cephalad, as the carotid artery is more accessible for compression, and a more thorough and rapid injection of contrast medium is possible. As previously stated, a retrograde flow of contrast medium may be obtained without compression if the needle is directed downward.

Conclusion

Percutaneous retrograde carotid arteriography is a safe, useful, and simple adjunct to arterial investigation, and permits demonstration of the vessels proximal to injection.

References

1. Moniz, E.; Pinto, A., and Alves, A.: Artériographie du cervelet et des autres organes de la fosse postérieure. *Bull. Acad. méd.* 109: 758-760, 1933.
2. Elvidge, A. R.: The Cerebral Vessels Studied by Angiography, p. 125, Chap. V., in *The Circulation of the Brain and Spinal Cord; a Symposium on Blood Supply*, Association for Research in Nervous and Mental Disease, Vol. 18. Baltimore: Williams & Wilkins Company, 1938, 790 pp.
3. Wickbom, I.: Thoracic aortography after direct puncture of aorta from jugulum. *Acta radiol.* 38: 343-349, 1952.
4. Radner, S.: Subclavian angiography by arterial catheterization. Visualization of metastatic tumor in upper thoracic aperture. *Acta radiol.* 32: 359-364, 1949.
5. Baker, H. L., Jr.: New approach to percutaneous subclavian angiography. *Proc. Staff Meet. Mayo Clin.* 35: 169-174, 1960.