

MANAGEMENT OF THE DONOR SITE

ROBIN ANDERSON, M.D., ELDON R. DYKES, M.D.,*

and

MARY M. MARTIN, M.D.†

Department of Plastic Surgery

EVERY surgeon who cuts a skin graft must face the problem of how to manage the donor site. However, since it is traditional among surgeons to assume that the area of primary treatment, be it on the surface of the body or within the chest or abdomen, is the important consideration in a surgical procedure; the incidental surface lesion, be it the suture line or the donor site of a skin graft, has been relegated to a position of insignificance. This is particularly true of the donor site, which, so far as the patient is concerned, may be the most painful, disabling, and cosmetically deforming portion of the surgical procedure. It behooves us, therefore, if we are to deal with skin grafts, to make every effort to manage the donor site in such a way as to minimize both the discomfort to the patient and the residual scar.

Mechanism of Donor Site Regeneration

In taking a thin split-skin graft, it is often assumed that enough surface epithelium is left in islets on the dermis to provide foci of regeneration which enlarge and ultimately fuse. Since it is practically impossible to cut a graft of such thinness, in actual practice this method of repair probably does not take place. It can be seen microscopically that all of the epithelial elements within the dermis having direct connection with the raw donor site act as such epithelial islets. The hair follicles are most prominent in this process, with sebaceous glands and sweat glands being of less importance. This regenerative process usually has started by the second day following the taking of a graft, and is complete by the fifth or sixth day. Keratinization and proliferation of the new epithelial layer proceed rapidly to produce a normal-appearing microscopic skin picture by the tenth day (Figs. 1-4). These observations as to time, pertain specifically to the clean, uninfected donor site from which a thin split-skin graft has been taken.

Converse and Robb-Smith¹ noted that the quality of donor-site repair is directly proportional to the rapidity of its healing, which in turn depends primarily on the thickness of the graft; e.g., after thin split-skin graft removal, the healing period is 6 to 10 days; after thick split-skin graft removal the healing period may approach two months.

Until recently, the almost universal method of handling the donor site has

* Fellow in the Department of Plastic Surgery.

† Formerly Special Fellow in the Department of Plastic Surgery; present address: 3035 Clifton Avenue, Cincinnati 20, Ohio.

been to use a firm, occlusive dressing over some kind of gauze. This dressing is designed to produce complete immobilization of the raw donor site and the immediately overlying gauze to reduce oozing and loss of serum by its pressure, and by excluding the outside world to maintain a reasonable degree of sterility and thus to avoid infection. Furthermore, it has been assumed that this method offers the best chance for rapid healing. In actual practice the results from the use of this type of occlusive dressing have left much to be desired. First, many of the available donor sites used most frequently, such as the posterior thigh, the buttocks, the abdominal wall, and the back are difficult to immobilize, even by the unusually ingenious operator. Inadequate immobilization that allows slipping of the gauze layer over the raw donor site, virtually assures breakdown of the normal healing process. Secondly, whereas the use of pressure for from 24 to 36 hours on the new donor site may be useful in reducing fluid loss, there is no evidence that it has any significant value thereafter. Thirdly, while a closed dressing may be of value in controlling bacterial contamination in the first few hours after the taking of a skin graft, it is doubtful that this is of much importance in terms of ultimate healing.

Although every plastic surgeon has his own particular method of managing the donor site, there has been little discussion of this problem in the surgical literature. In general, the concept of the "occlusive dressing" has been accepted.² The differences in technic have been related largely to the types of ointment and gauze that are placed next to the raw surface. Dry, fine-mesh cotton and nylon gauzes have been used without any ointment, and in recent years some surgeons have advocated the use of a perforated sheet of Cellophane-like material known as "Teflon" to prevent adherence of the dressing to the donor site. A plastic spray to provide a firm, but thin dressing has been tried in an attempt to improve the occlusive dressing. This has been generally unsatisfactory. Of the materials mentioned, the most widely and successfully used has been fine-mesh gauze, lightly coated with Vaseline, covered by a resilient pressure dressing.

In recent years a number of surgeons have managed donor sites by the exposure method, such as that used in the treatment of burns. Although this method has been fairly satisfactory, it has had the same deficiencies that characterize its use for burns. These are specifically the problem of drainage and oozing in the first 24 to 72 hours, and the tendency of the thick coagulum to crack, with subsequent superficial infection. Except for these deficiencies, the serum coagulum, once it has formed, provides an almost perfect dressing material; it is strongly attached to the raw surface, it has moderate flexibility, it is not tender, it is surprisingly tough, and it has little bulk.

Artz, Bronwell, and Sako³ in 1955 reported a modification of the open technic, adding a layer of gauze to the coagulum, thus making use of the coagulum to protect the donor site, and at the same time minimizing the difficulties inherent in the use

of complete exposure of the wound. We have been using this type of donor-site dressing since 1952. The following data present our experience over a seven-year period.

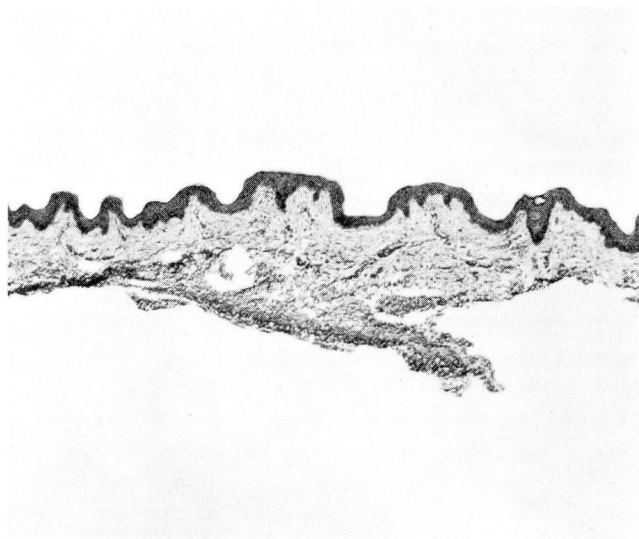


Fig. 1. Cross section of typical medium-thickness split-skin graft; magnification x 40.

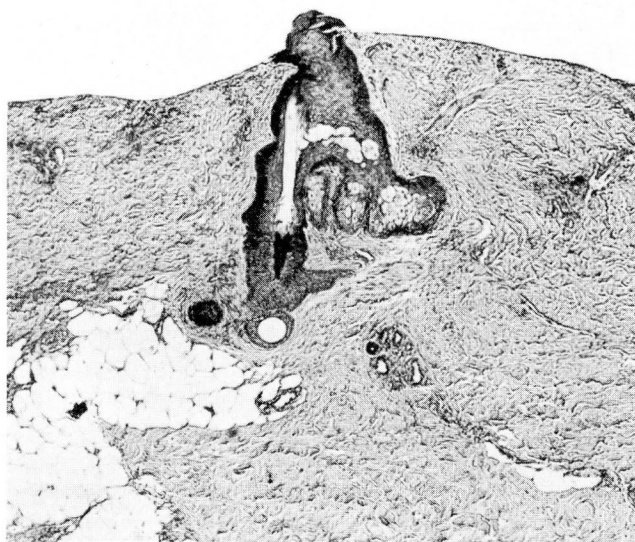


Fig. 2. Section of donor site three days after removal of graft, showing early proliferation of hair follicle epithelium; magnification x 40.

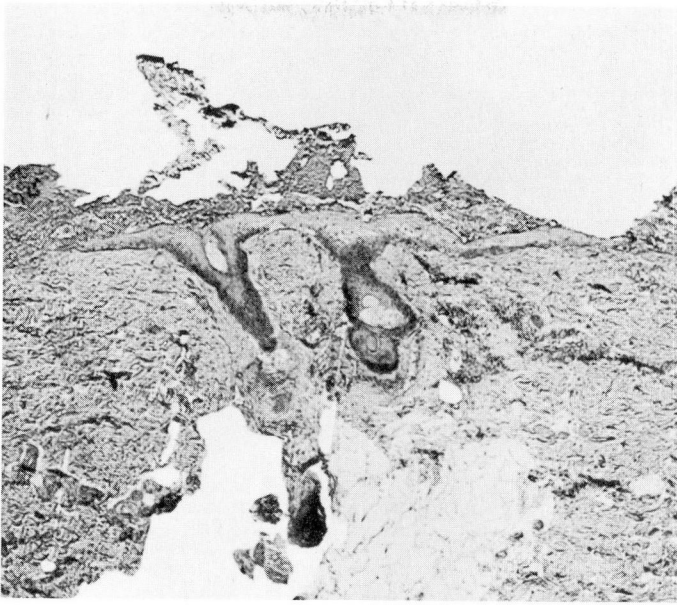


Fig. 3. Section of donor site five days after removal of graft; the proliferating epithelium has started to cover the raw connective-tissue surface; magnification x 40.

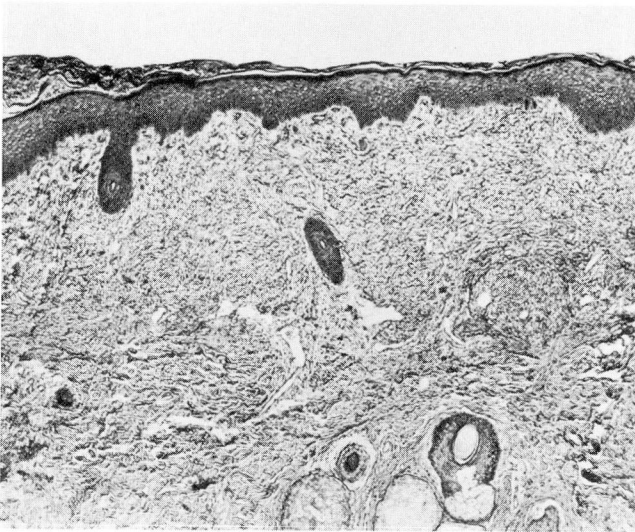


Fig. 4. Section of donor site six days after removal of graft; epithelial resurfacing is complete; magnification x 40.

Technic

Immediately after the cutting of the skin graft, a single layer of almost dry fine-mesh Vaseline gauze is applied to the donor site. An occlusive dressing of the usual type is applied with moderate pressure, to control initial oozing and to protect the donor site in the immediately postoperative period. In from 12 to 24 hours, the occlusive portion is removed, leaving only the single layer of greased gauze attached to the raw surface. This is accomplished without difficulty, but with some discomfort to the patient. The donor site is kept exposed to air, and within another 24-hour period has developed a thin, pliable coagulum, of which the fine-mesh gauze has become an integral part. The gauze provides a structural framework for the clotting process, and prevents subsequent cracking of the coagulum. During this second 24-hour period there may be minimal oozing from the gauze surface, which can be gently removed with a gauze sponge, without injury to the underlying raw area. The coagulum rapidly becomes firm, and by the end of the third day is immune to the usual trauma of bed activity and early ambulation (*Figs. 5 and 6*).

The edges of the coagulum, which gradually loosen as healing takes place, are kept trimmed. The coagulum is allowed to separate spontaneously, without manual assistance; this eliminates the tearing of newly formed epithelium, which occurs so frequently when the usual gauze dressing is removed. This process may

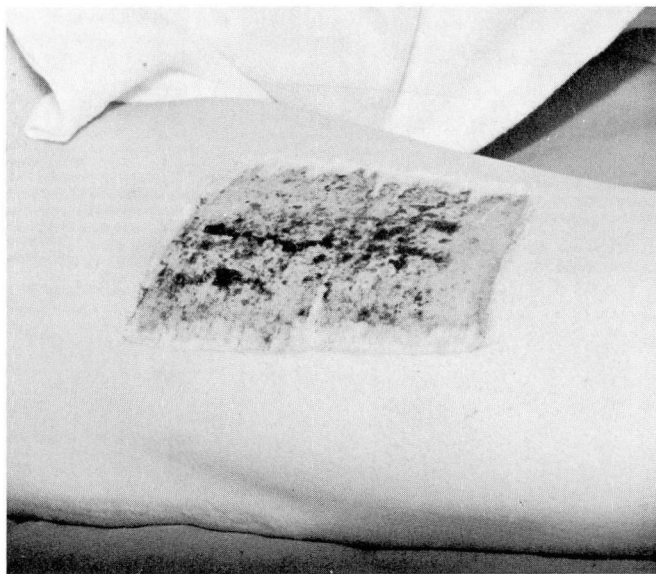


Fig. 5. Usual thigh donor site with gauze-serum coagulum intact two days after removal of outside dressing.

be completed within a week, or may require several weeks for its completion, depending on the thickness of the original graft.

Results

It is of no statistical value to report the exact number of complications experienced by the authors when using the standard occlusive dressing prior to their using the above-described method. Such a figure carries little significance without accurate analysis of such variables as thickness of graft, location of the donor site, extent of immobilization of the area, and probably most important, the continually changing resident personnel entrusted with the dressing and management of the donor site. Furthermore, it is difficult to decide just what constitutes a reportable donor-site complication. However, in an effort to provide a reasonable base line for evaluation, it can be stated that of 100 donor sites managed with the usual occlusive dressing, more than 30 per cent became wet and superficially infected to such a degree that more than "Band-Aid" care was required.

In the past seven years, approximately 1,400 donor sites have been managed by this gauze-coagulum method. There has been no instance in which the entire donor site has become wet, even in the uncooperative patient, and the over-all incidence of complications requiring treatment is less than 5 per cent. This figure is most significant when we consider that at least one third of the donor sites were high on the posterior aspect of the thigh, on the buttock, or on the back.

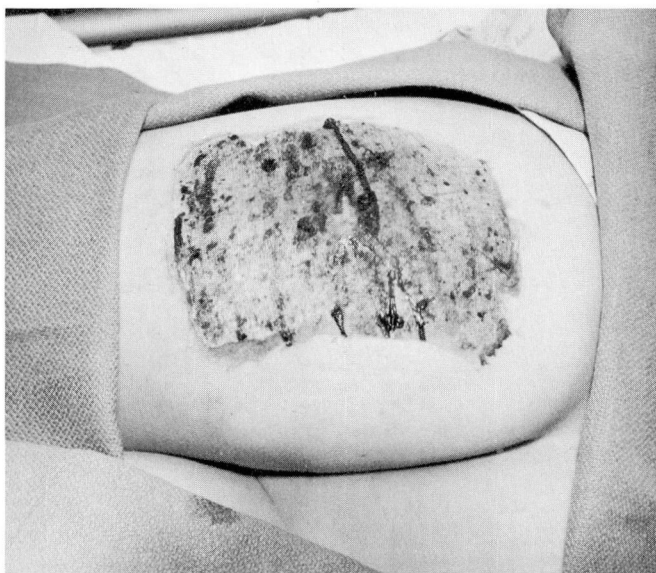

Fig. 6. Buttock donor site easily managed by modified exposure method.

In general, healing of the donor site has not been slowed by the elimination of the pressure dressing. Pain to the patient has been reduced significantly, particularly that secondary to surface infection. Consequently, the surgeon's problems have been comparably lessened.

Summary

A method of donor-site dressing has been discussed. This utilizes an occlusive dressing over fine-mesh Vaseline gauze for the first 12 to 24 hours. At that time the occlusive portion is removed and the fine-mesh gauze alone is left in place to become an integral part of the covering coagulum. The results using this method have been superior to those obtained with the standard occlusive dressing.

References

1. Converse, J. M., and Robb-Smith, A. H. T.: Healing of surface cutaneous wounds; its analogy with healing of superficial burns. *Ann. Surg.* 120: 873-885, 1944.
2. Brown, J. B., and McDowell, F.: *Skin Grafting of Burns: Primary Care, Treatment, Repair.* Philadelphia: J. B. Lippincott Co., 1943, 204 pp.
3. Artz, C. P.; Bronwell, A. W., and Sako, Y.: Exposure treatment of donor sites. *Ann. Surg.* 142: 248-251, 1955.