

# MILKMAN'S SYNDROME

## A Brief Review of the Literature and Report of a Case

DELBERT G. SMITH, M.D.,\*

and

THOMAS F. MEANEY, M.D.†

Department of Radiology

**M**ILKMAN'S syndrome is a form of osteomalacia characterized radiologically by radiolucent zones or bands of decalcification traversing otherwise normal-appearing bone, usually at right angles to the long axis of the bone. These ribbon-like bands have been called "pseudofractures," "Looser's lines," "Umbauzonen," "Umbaufrakturen," "multiple spontaneous idiopathic symmetrical fractures," "osteoporosis melolytica," "insufficiency fractures," and "spontaneous fractures."

### History

Mention of this phenomenon dates back to 1881, when Parker<sup>1</sup> reported the postmortem presence of spontaneous bilateral fractures in several ribs of a 12-month-old child with rachitic deformities. Feiss,<sup>2</sup> in 1905, described the condition of a four-year-old rachitic child with bilateral multiple spontaneous fracture-like zones, but with no displacement of fragments or other evidence of true fractures. In 1911, Hagemann and Eringhaus were reported by Fromme<sup>3</sup> to have found peculiar spontaneous fractures in a patient in the late stage of rickets.

In 1920, Looser<sup>4</sup> described radiolucent zones observed in his study of cases of starvation in Central Europe after World War I. He originally described the lesions as "transverse or oblique fissures or band-like . . . radiolucencies which divide the bone into two pieces but are not roentgenologically or clinically actual fractures." In 1930 and in 1934, Milkman<sup>5,6</sup> described this syndrome as a separate disease entity. He related his work to that of Looser, but since Milkman's first reports, this condition has become associated with his name and, to date, reports of more than 60 cases of Milkman's syndrome have been published.

### Etiopathogenesis

The true nature of Milkman's syndrome has been the subject of controversy. Milkman himself considered the cause unknown. Camp and McCullough<sup>7</sup> reported finding bony lesions similar to those in Milkman's syndrome in a number of conditions including Paget's disease, congenital syphilis, Von Recklinghausen's

---

\*Fellow in the Department of Radiology.

†Formerly Member of the Staff of the Department of Radiology; present address: 10515 Carnegie Avenue, Cleveland, Ohio.

disease, and march fractures. However, those lesions do not fit the true definition of Looser's lines; that is, they do not occur in otherwise normal-appearing bone, and their distribution is not symmetric. Albright, Burnett, Parson, Reifenstein, and Roos<sup>8</sup> in 1946 argued that true multiple symmetric pseudofractures occurred only in osteomalacia, and this thesis has generally become the accepted opinion today. In all of the proved cases of Milkman's syndrome studied by Albright and his associates the chemical determinations of the serum were consistent with those obtained in cases of osteomalacia, that is, there were normal or low serum calcium, normal or low serum phosphorus, and high serum alkaline phosphatase values. The typical values in Milkman's syndrome are normal for serum calcium, low for serum phosphorus, and high for serum alkaline phosphatase.

The etiologic classification of osteomalacia published by Albright and his associates<sup>8</sup> is reproduced in *Table 1*. They recorded cases of Milkman's syndrome

**Table 1.—Etiologies of osteomalacia met in the United States\***

---

---

**Classification:**

- A) Vitamin D lack;
    - a) "Simple" vitamin D lack
    - b) Resistance to vitamin D
    - c) Steatorrhea
  - B) Renal Acidosis;
    - a) Tubular insufficiency-without-glomerular-insufficiency
    - b) Fanconi Syndrome
  - C) Idiopathic Hypercalcuria
  - D) Hyperparathyroidism with Osteitis Fibrosa Generalisata during transitional stage following removal of parathyroid tumor.
- 
- 

*\*Reproduced through the courtesy of Medicine.<sup>8</sup>*

due to each of the etiologic factors mentioned, with the exception of simple vitamin D deficiency, and concluded that: "... it may be stated that ribbon-like zones of decalcification which occur in otherwise normal-appearing bone, which last months or years without regressing, and which exhibit a marked tendency to be symmetrical, occur only in osteomalacia or rickets." Subsequently, Winston and Pendergrass<sup>9</sup> reported a case that may well have been due to simple lack of vitamin D. The course of the disease in their patient was characterized by remissions and exacerbations; the remissions were directly correlated with the administration of vitamin D and calcium.

Many theories have been advanced as to the exact mechanism of production of the pseudofractures. Among these are: the presence of infection and sympathetic

bone disease; affection of the periosteum and the marrow; hormonal influence; and disease of the central nervous system. None of these conditions satisfactorily explains the symmetric distribution of the pseudofractures. Looser<sup>4</sup> explained the lesions on the basis of excessive strain, both muscular and postural, on an already weakened skeletal structure. Milkman<sup>6</sup> suggested the possibility of a control mechanism in the nervous system, which regulates small localized trophic changes. This control could be directed by the blood supply, and would explain the increased vascularity in the involved areas. Le May and Blunt<sup>10</sup> could not account for pseudofractures at bony regions not directly associated with strain, and advanced the concept of repeated and long-sustained trauma from the pressure of adjacent arteries at certain bony sites. In four proved cases of Milkman's syndrome they were able to correlate the locations of pseudofractures with vascular dissection at three (unrelated) necropsies. In many instances, arteries lay in close proximity to bone at points where pseudofractures were roentgenographically demonstrated in their four patients. From this study they postulated that long-standing pressure and pulsation of arteries caused small erosive defects in the osteomalacic bone, resulting in the formation of uncalcified osteoid. In further support of this theory are the findings of Steinbach, Kolb, and Gilfillan,<sup>11</sup> who made arteriographic studies of patients with Milkman's syndrome. Their studies showed the presence of arteries immediately adjacent to the sites of pseudofractures.

Cohen<sup>12</sup> demonstrated two cases of pseudofractures in ribs of patients who had extraperiosteal Ivalon packs when undergoing collapse therapy of the lung for pulmonary tuberculosis. He reasoned that the lesions could have been caused by trophic changes due to the removal of the periosteum and the nerve supply or the blood supply.

### Radiologic Features

The radiologic features of Milkman's syndrome are pathognomonic, and consist of pseudofractures or Looser's lines that range from 1 mm. to 1 cm. or more in width. They are multiple, usually symmetrically distributed, and may occur both in tubular and in flat bones. There is some disagreement as to the bony sites most commonly involved, but lesions have been reported as occurring in almost all bones of the body. Some of the more common sites are the ribs, the coracoid process and the border of the scapula, the pelvis (particularly the ischial and pubic rami), the femur, the tibia, the fibula, the radius, the ulna, the clavicle, and the metatarsal and metacarpal bones. More rarely involved are the humerus, the phalanges, the carpal and tarsal bones, and the ilium. The pseudofractures often appear at identically corresponding sites and in equal numbers in involved paired bones. The lesions are first identified on roentgenograms as small punctate radiolucent areas that may appear to be placed centrally in the region of the spongiosa or laterally in the cortex, depending on the projection of the radiograph. As they progress, the lesions gradually encircle the entire cortex, usually at right angles to the long axis of the bone, and it appears as though the bones

were actually erased at those sites. Rarely there may be oblique or Z-shaped fissures.

The margins of the radiolucent bands are well defined, mildly sclerotic, and slightly jagged and uneven (*Figs. 1 and 2*). There is no discontinuity or distortion in the line of the bone, and no evidence of the formation of callus. These are features that distinguish the lines from true fractures. However, these areas may proceed to fracture with displacement of fragments if they are subjected to sufficient stress.

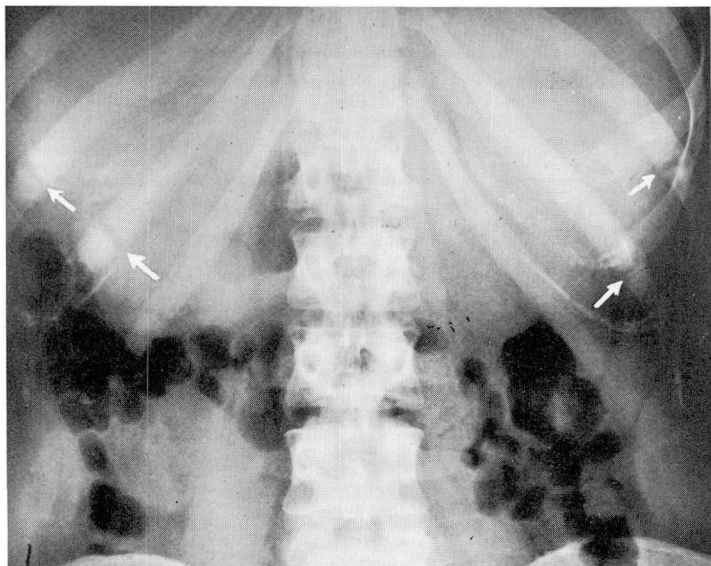


Fig. 1. Roentgenogram showing bilateral Looser's lines (arrows) in the tenth and eleventh ribs. There is no evidence of displacement of fragments.

Clinically, point tenderness often occurs over the bony lesions, and this evidence usually precedes the actual changes visible on roentgenograms. As a part of this syndrome, Milkman<sup>5, 6</sup> described a symptom-complex consisting of lumbosacral pain, point tenderness at various sites, difficulty in raising the leg, waddling gait, and generalized weakness.

### Case Report

A 26-year-old, married, white woman was first examined on July 18, 1958. She had been well until two years before, when, during her fifth month of pregnancy, she first noted aching pain in the feet and the knees. Subsequently the pain increased and involved also the lumbar region, the hands, and the rib cage. This pain has persisted to

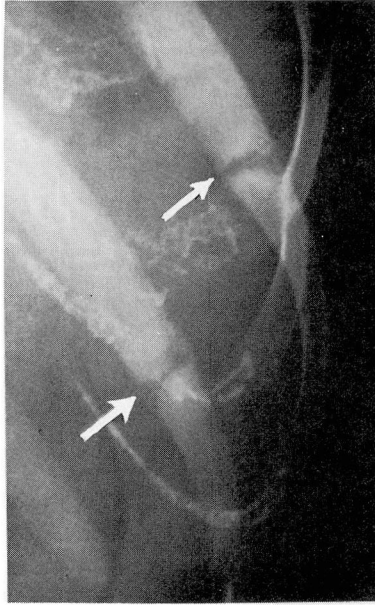


Fig. 2. Roentgenogram of the tenth and eleventh ribs, showing Looser's lines in detail (arrows). Note the jagged and slightly sclerotic margins of the pseudofractures. There is no evidence of formation of callus.

the time of writing this report. She stated that there had been no redness or swelling of the joints.

At the physical examination, pressure on the ribs elicited pain, and there was point tenderness over the left fourth and fifth ribs in the midaxillary line. Pressure on the sternum caused discomfort. Dorsiflexion of the feet caused pain, and the patient walked with a peculiar gait, throwing out the legs. No other abnormalities were found.

Extensive laboratory tests were made. The Wassermann test and the tests for blood sugar, blood urea, serum carbon dioxide content, and the serum values for chloride, potassium, sodium, cholesterol, and creatinine, all were within normal limits. The hemoglobin was 12.0 gm. per 100 ml., and the white-cell count was 5,000 cells per cubic millimeter. The total serum protein value was 6.7 gm., with albumin 2.9 gm., and globulin 3.8 gm. per 100 ml. Urinalyses were negative for the presence of sugar and albumin, and the specific gravity ranged from 1.007 to 1.020. A urinary culture was sterile; the test for Bence Jones protein was negative. Serum calcium values in two tests were respectively, 9.9 mg., and 10.0 mg. per 100 ml. (normal: 9 mg. to 11 mg. per 100 ml.). Serum phosphorus values in three tests were respectively, 2.0 mg., 1.5 mg., and 1.8 mg. per 100 ml. (normal: 2 mg. to 3.5 mg. per 100 ml.). Serum alkaline phosphatase values in two tests were respectively, 5.5, and 4.6 Bodansky units (normal: 2 to 4 Bodansky units). With the patient following the Aub controlled-calcium diet, deter-



minations of urinary calcium and phosphorus excretions were made on three 24-hour specimens. The values were:

Volume of urine in 24 hr., ml.	Excreted	Amount, mg.
1,695	Calcium	40.6
2,730	Calcium	49.1
2,032	Phosphorus	598

While the patient was following the Aub diet, reabsorption values of phosphate were respectively, 67.2 per cent and 75.57 per cent.

The results of radiographic examinations of the gallbladder, the upper gastrointestinal tract, the colon, and the genitourinary system were normal. On roentgenograms the skull appeared to be normal and the lamina dura to be intact. Radiologic examination of the skeletal system revealed pseudofractures in the right fifth, sixth, and seventh ribs, and bilaterally in the tenth and eleventh ribs, and also bilaterally at the junctions of the ischial and the pubic bodies (*Figs. 1-3*). The diagnosis was osteomalacia secondary to renal tubular defect in reabsorption of phosphorus.

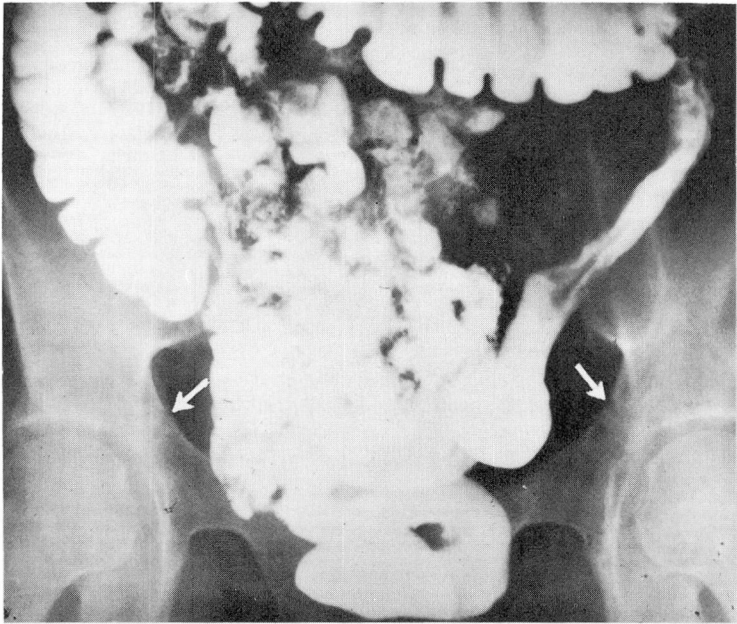


Fig. 3. Roentgenogram showing evidence of bilateral pseudofractures (arrows) at the junctions of the pubic and ischial bodies. The pseudofractures appear as small radiolucent notches in the cortex.

## Summary

Milkman's syndrome is a form of osteomalacia. The radiolucent zones (pseudofractures) seen on roentgenograms are pathognomonic of this syndrome. The etiologic factors concerned in the development of these pseudofractures are not completely understood. A case history of Milkman's syndrome is presented.

## References

1. Parker, R. W.: Ricketty deformity of thorax, with spontaneous fracture of several of ribs. *Tr. Path. Soc. (London)* 33: 257-258, 1881-1882.
2. Feiss, H. O.: Spontaneous fractures with rickets; report of case. *Am. J. Orthop. Surg.* 3: 271-278, 1905-1906.
3. Fromme, A.: Häufung von Spontanfrakturen durch endemisch auftretende Spätrachitis. *Zentralbl. Chir. (Leipzig)* 46: 487-489, 1919.
4. Looser, E.: Über pathologische Formen von Infraktionen und Callusbildungen bei Rachitis und Osteomalakie und anderen Knochenerkrankungen. *Zentralbl. Chir.* 48: 1470-1474, 1920.
5. Milkman, L. A.: Pseudofractures (hunger osteopathy, late rickets, osteomalacia); report of case. *Am. J. Roentgenol.* 24: 29-37, 1930.
6. Milkman, L. A.: Multiple spontaneous idiopathic symmetrical fractures. *Am. J. Roentgenol.* 32: 622-634, 1934.
7. Camp, J. D., and McCullough, J. A. L.: Pseudofractures in diseases affecting skeletal system. *Radiology* 36: 651-663, 1941.
8. Albright, F.; Burnett, C. H.; Parson, W.; Reifenstein, E. C., Jr., and Roos, A.: Osteomalacia and late rickets; various etiologies met in United States with emphasis on that resulting from specific form of renal acidosis, therapeutic indications for each etiological sub-group, and relationship between osteomalacia and Milkman's syndrome. *Medicine* 25: 399-479 (402, 423), 1946.
9. Winston, N. J., and Pendergrass, E. P.: Milkman's disease (osteomalacia); report of case which shows that Milkman's disease may be "simple" vitamin D deficiency in adults. *Am. J. Roentgenol.* 71: 484-489, 1954.
10. Le May, M., and Blunt, J. W., Jr.: Factor determining location of pseudofractures in osteomalacia. *J. Clin. Invest.* 28: 521-525, 1949.
11. Steinbach, H. L.; Kolb, F. O., and Gilfillan, R.: Mechanism of production of pseudofractures in osteomalacia (Milkman's syndrome). *Radiology* 62: 388-395, 1954.
12. Cohen, S. L.: Milkman's pseudofractures of ribs following extraperiosteal ivalon pack. *Radiology* 65: 587-589, 1955.