

THERAPY FOR CARCINOMA OF THE UTERINE CERVIX; PART II: SURGERY

JAMES S. KRIEGER, M.D., and PAUL R. ZEIT, M.D.

Department of Obstetrics and Gynecology

THE surgical treatment of cervical carcinoma has been subject to a tremendous burst of enthusiasm in the past ten years. Published surgical results might give one the false impression that the use of irradiation has been largely discarded; in Part I we and our associates¹ discussed the importance of irradiative therapy. New surgical procedures have been made possible and old ones have been made safer by improved anesthetics, antibiotics, surgical technics, and an imaginative attitude on the part of surgeons. Some operations are so new that they have not yet been thoroughly evaluated, while other currently accepted operations are being misapplied or poorly executed. Because of these factors it is difficult to delineate precisely the indications and contraindications for the use of surgery.

This report concerns only invasive carcinoma of the uterine cervix. Carcinoma in situ is purposely excluded because we believe that that lesion represents an entirely different condition in many cases. We agree wholeheartedly with the suggestion of Blaikley, Kottmeier, Martius, and Meigs² that carcinoma in situ be omitted from the clinical classification of carcinoma of the cervix. Although it does represent a major cellular abnormality, in many cases it is not a clear-cut entity. In most instances carcinoma in situ is amenable to local treatment if certain precautions in diagnosis and follow-up are observed. Our experience with an approach to the diagnosis and treatment of carcinoma in situ has been recently reported.³

The surgical treatment of invasive cervical carcinoma requires facilities and abilities for highly specialized technics. When operative intervention is contemplated, the surgeon should be prepared to carry out the most extensive procedure necessary to cope with the disease, and should in no way compromise the patient's future well-being by lack of technical ability or ancillary facilities. The most complete laboratory and technical facilities must be available. Successful radical surgery demands not only the co-operative efforts of an anesthesiologist, a pathologist, and a gynecologist, but also the assistance of any surgical or medical specialist whose particular talents might conceivably be needed in the care of the patient. This care includes the preoperative, operative, and postoperative phases. These operations demand the utmost in team co-operation and should not be undertaken when any of the above facilities are substandard or are lacking.

Operations for Cure

Operative procedures that are undertaken with cure in mind, consist of the radical hysterectomy (as opposed to the Wertheim hysterectomy), and the three

exenteration procedures (anterior, posterior, and total). *Simple total hysterectomy is contraindicated in the treatment of invasive cervical carcinoma (either alone or in combination with irradiation).*

In no case, should a radical hysterectomy be undertaken unless the surgeon is capable of extending the scope of the operation to any of the exenteration procedures if the extent of disease makes one of them desirable. These are precise, refined, surgical procedures that can be done with relative safety and surprisingly small blood loss when the surgical team is experienced.

Radical hysterectomy with bilateral dissection of deep pelvic lymph nodes is the most precise and oftentimes the most difficult of the above operations to perform, in that selected structures are removed with considerable risk of damage to remaining viscera. Ureterovaginal or vesicovaginal fistulas may result from direct trauma or devascularization, and severe bleeding may occur during the dissection of the lateral pelvic walls. This operation involves a complete removal of the broad-ligament tissues, a complete dissection of the fat and the lymph nodes of the lateral pelvic walls, complete visualization of the pelvic course of the ureters, removal of the upper portion (one fourth to one third) of the vagina with the paravaginal structures, as well as removal of the uterus, the tubes, and the ovaries. This operation should be distinguished from the classic Wertheim operation that involves only an extensive hysterectomy without dissection of lymph nodes.

In theory, radical hysterectomy is not a good operation for cancer of the uterine cervix because the ureters so closely approximate the cervix. This anatomic feature makes it necessary to cut across potentially cancer-bearing tissue in the process of the operation. Furthermore, substitutes for the bladder are not as yet sufficiently satisfactory to justify removing the bladder as a standard procedure thereby overcoming this problem.

Anterior exenteration involves the removal of the bladder in conjunction with a radical hysterectomy and dissection of the lymph nodes. *Posterior exenteration* combines removal of the rectum and the lower sigmoid colon with a radical hysterectomy; whereas, *total exenteration* involves the removal of both the rectum and the bladder together with the uterus, the tubes, and the ovaries. The anterior and the total exenterations have been used most frequently in treating cervical carcinoma, and each involves the use of a substitute bladder. The substitutes that have been devised are illustrated in Figure 1 (A–D); the most widely employed bladder substitute is at present the Bricker's pouch. With the construction of a Bricker's pouch, an external urinary opening still is necessary, and if the rectum is removed there is a separate colostomy. We do not favor the transplantation of ureters to a sigmoid colostomy because the so-called "wet colostomy" is difficult to control and often is extremely distressing to the patient. Chronic pyelonephritis with azotemia is a common complication.

We have recently devised an operative procedure that we hope will overcome the necessity for external ostiums except as temporary measures (Fig. 2). This involves performing a total exenteration from an anterior approach and the preservation of a short rectal stump. A low anterior intestinal anastomosis, with a temporary transverse colostomy, is done. A Bricker's pouch is also constructed.

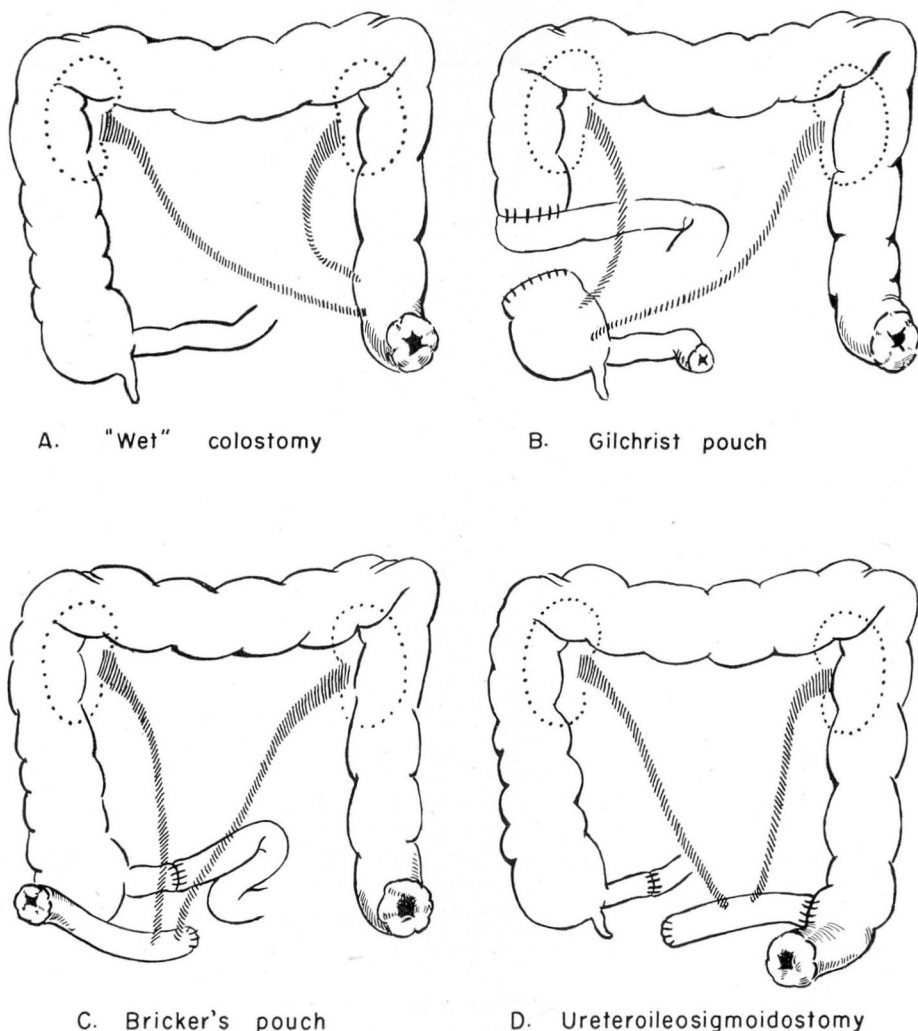


Fig. 1. Bladder substitutes.

When convalescence has proceeded to a suitable extent, the transverse colostomy is closed. At a later date the Bricker's pouch is inserted into the sigmoid colon and the abdominal stoma is closed. A series of primary ureteroileosigmoidostomies for congenital urinary problems has been previously reported in this journal.⁴ The results have been satisfactory to date. One patient who has had a total exenteration is now waiting to have the Bricker's pouch transplanted to the sigmoid colon.

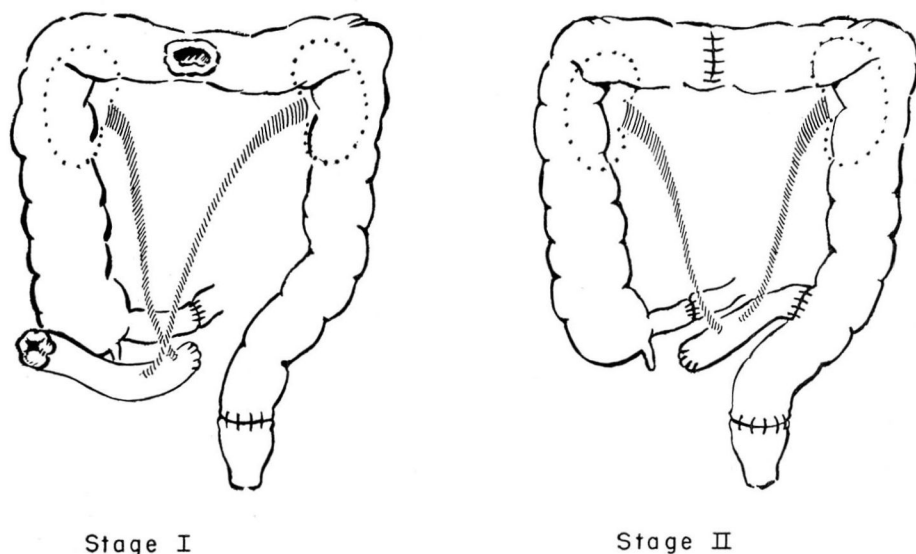


Fig. 2. Ureteroileosigmoidostomy with low anterior rectosigmoid anastomosis.

Operations, Indications, and Contraindications

The precise indications for curative, radical, surgical procedures are not entirely clear, although some contraindications have become apparent. We generally reserve the radical hysterectomy for the early carcinoma that has failed to respond to irradiation. An early case is one that is for the most part confined to the cervix with possibly minimal extension to the vaginal wall or the broad ligament. Where there is disease lateral to the cervix, it occasionally is possible to perform a radical hysterectomy, but more often an anterior or total exenteration is indicated.

For the occasional carefully selected patient the immediate risk of surgery may be preferable to the delayed sequelae of irradiative therapy. These latter complications are definite and may constitute a real threat to the future good health and emotional adjustment of the patient. Vaginal atresia and shrinkage with attendant coital problems is one of the major considerations in addition to irradiative cystitis, proctitis, and damage to the small bowel. With this in mind we occasionally use radical hysterectomy with dissection of the lymph nodes for primary treatment of stage I and early stage II lesions.

Exenteration procedures are employed when radical hysterectomy is infeasible because of extensive disease, also as primary therapy when there is evidence of extension of carcinoma to or through the bladder or the rectum. Rarely exenterations are used for severe, debilitating sequelae of irradiation when there is no evidence of active malignant disease.

The contraindications to the exenteration operations are fairly obvious: serious systemic disease, evidence of extension beyond the confines of the true pelvis, or involvement of the nerves or of the vessels of the pelvis. In order to make these determinations it is often necessary to carry out extensive preoperative evaluation but, more importantly, operability may not be determined until the abdomen is explored. Unfortunately, in rare instances surgical procedures are undertaken and partially completed before it becomes apparent that the lesions are not completely resectable. If preoperative roentgen studies indicate a favorable situation, the patient should have the benefit of exploration despite a seemingly "frozen" pelvis, because a radical operation still may be possible. The condition of the legs may contraindicate operation, swelling may be due to lymphatic obstruction; pain may be due to nerve involvement. These assumptions often can be confirmed by careful rectovaginal examination, but, when this is not possible, pelvic exploration should be carried out.

The exenteration operations are too new to be completely evaluated, for while it is true that a certain percentage of patients can and do survive the operation and carry on an active and happy life, free of disease, there is a larger percentage who die as a result of extrapelvic recurrences and complications of their disease. Reported operative and hospital mortalities are high. The primary problem is that despite care in selection of patients we do not know enough of the individual variations and the host responses to carcinoma to determine intelligently in advance those patients who will benefit from such operations.

The emotional impact of extensive operations has been somewhat over-emphasized. It is true that there may be a definite psychologic reaction to the loss of normal bladder, rectal, and vaginal function, but most women can make a satisfactory adjustment even to a permanent ileostomy and colostomy if they are free from disease and able to carry on an otherwise normal life.

We have been performing exenterations in carefully selected private patients since 1951. They are patients who must finance the lengthy hospitalization and frequent complications incurred in extensive surgery. The care of these patients is time consuming. The operations often are prolonged exercises in surgical technic. Many of these patients have seen savings and economic resources melt away under the impact of long-endured chronic illness and previous extended medical care. For these reasons, we have made every attempt to avoid using these operations for the purpose of palliation.

In the past seven years, we have performed 18 anterior or total pelvic exenterations; we have not employed the posterior exenteration for cervical carcinoma. Of the 18 patients, seven are still living from eight months to six and one-fourth years after the operation; 11 died of their disease in from five months to three and one-half years after the operation. There have been no operative or immediately postoperative deaths in this group. We believe that this is largely a result of the team effort that employs the abilities of the urologist, the colon surgeon, the gynecologist, and all other medical or surgical specialists who are most capable of managing various aspects of operative and postoperative care. Early in the series we used ureterosigmoidostomy for a substitute bladder, but in the past five years we have almost exclusively constructed the Bricker's pouch (Fig. 1C.)

In the same seven years, 20 patients underwent radical hysterectomy, all of whom have survived from 7 months to 5 years and 10 months after operation. Nineteen patients are clinically free of disease; one patient has extensive disease. From 1951 to the present time, 539 patients with various stages of cervical carcinoma have been examined here.

From the above figures it is apparent that our criteria for the selection of patients for more radical operative procedures have been exceedingly rigid. We have not been performing surgery just for surgery's sake. We have adopted a conservative approach to the problems presented and have attempted to avoid radical palliative procedures that only serve to palliate the surgeon's conscience or the patient's family.

Operations for Injuries from Irradiation

A second use of surgery is in the treatment of sequelae of irradiation in the absence of demonstrable residual carcinoma. It is generally true that progressive ureteral obstruction is indicative of advancing carcinoma, but there is a distinct group of patients in whom the obstructive changes are secondary to irradiation. These lesions can be treated in various ways depending on the nature of the problem and the extent of the damage. Neoureterocystotomy (reimplantation of the ureter into the bladder), ureterosigmoidostomy, and construction of the Bricker's pouch each have been used as corrective measures:

Irradiative lesions in the large bowel are most often on the anterior rectal wall opposite the cervix, where the maximal amount of irradiation has been given or where radium has been misapplied. Fistulation or stricture may occur, making a colostomy necessary in either case. On rare occasions only a temporary colostomy is needed in order to allow the stricturing and ulcerating process to subside or to effect a repair of the fistula. Rectal resections with "pull-through" should not be attempted because of extensive postirradiative scarring at this site and the danger of reactivating the carcinoma, also the area usually is so severely devascularized by previous irradiation that primary healing may not occur.

Irradiative injuries to the small bowel may be localized or diffuse. Localized changes occur when a loop of bowel is adherent in the pelvis and is exposed to the full impact of irradiation. When an isolated injury from irradiation occurs it may result in a low-grade or a complete obstruction or, in rare instances, perforation may follow. Diversionary procedures are employed in preference to local resections because there is generally a fairly diffuse microscopic reaction to irradiation involving much of the small bowel. By carrying out a lesser procedure there is less danger of delayed or incomplete healing.

Vesicovaginal fistula occasionally results from faulty placement of radium or too vigorous irradiation. An operative repair of the fistula may be feasible but often there is so much reaction that a diversionary operation is the only recourse. The Bricker's pouch or ureterosigmoidostomy is more easily controlled by the patient than is a cutaneous ureterostomy.

Operations for Palliation

Palliative operations can be divided into four categories according to their specific purposes: (1) relief of pain, (2) correction of urinary fistulas and, occasionally, obstruction; (3) correction of intestinal obstruction or fistulation; (4) control of bleeding.

The type of operation employed for the relief of pain depends on the nature and distribution of the pain. Cordotomy is frequently employed and may be either unilateral or bilateral. After a unilateral cordotomy the opposite side also often must be operated upon to obtain complete relief of pain; intense pain on one side of the body may mask significant pain on the contralateral side. Subarachnoid injections of alcohol may be used to control pain in the sacral area. Each of these operations carries with it a risk of interfering with the mechanism of micturition, a problem easily solved by the use of an indwelling catheter. Prefrontal lobotomy, presacral neurectomy, and caudal anesthesia have been suggested but are not frequently used because the above-mentioned methods of relief of pain have been found to be more effective and predictable. Cobalt-60 teletherapy has decreased the need for operative procedures for relief of pain.

Major urinary operations seldom are indicated for palliation. Obstruction of the urinary tract and resulting uremia is a common cause of death in uncontrolled cervical carcinoma. Death results from coma and its complications, and is pain-free. Any attempts to relieve the uremic coma add to the patient's discomfort and, if successful, result in a more protracted painful terminal illness.

Urinary fistulas present a real problem in nursing care, and because of this are worthy of correction if the patient can reasonably tolerate surgery. The simplest procedure consistent with correction of the problem is generally employed; most often it consists of nephrostomy or cutaneous ureterostomy. On rare occasions, if the rectum is uninvolved and the rectal sphincters are competent, ureterosigmoidostomy may be undertaken.

The major indication for palliative intestinal surgery is the existence of an enterovaginal fistula. It generally is corrected by simple sidetracking operations. Intestinal resections are neither indicated nor necessary. Colostomy seldom is used as a primary palliative procedure once obstruction has occurred. However, occasionally when an exploratory operation is performed and curative surgery is not possible, impending rectal or sigmoid obstruction is recognized. In this situation a transverse or descending colostomy may be done. Seldom is palliative colostomy indicated for a rectovaginal fistula.

Irradiation has been effective in preventing exsanguination, thereby decreasing the need for surgery. However, when surgery must be used for the control of bleeding, the ligation of the internal iliac arteries may be lifesaving. This operation can be carried out either transperitoneally or retroperitoneally.

Surgical Exploration

Abdominal exploration has not been utilized to its optimal extent in the past. The reluctance to employ this diagnostic tool has been understandable in

that not too long ago this procedure involved considerable risk to the patient. However, even with the most up-to-date diagnostic methods, we often are unable to determine without operation the true extent of the patient's disease. All experienced physicians remember an occasional patient for whom the prognosis seemed utterly hopeless, yet at exploration a benign condition or a correctable malignancy was found. Knowing the true extent of malignant disease also permits more realistic planning of palliative therapy. A carcinoma can be so advanced that no curative treatment is possible and yet still be for the most part confined to the pelvis. This, however, is an entirely different situation from that presented by a disease that has spread to the liver or to the periaortic lymph nodes in the upper abdomen. In the case of carcinoma confined to the pelvis, the use of palliative irradiation or surgery may be reasonable because of the patient's considerably longer life expectancy. In the case of carcinoma in the upper abdomen, the patient's only need is sympathetic symptomatic medical care.

Several years ago one of us⁵ suggested the use of the so-called "second-look" operation in managing malignant pelvic lesions. The second-look consisted of re-exploration of the abdomen at an arbitrary time after the completion of the irradiative therapy or after operation performed in the hope of cure. Now we believe that such operations have little to offer since it is impossible by mere inspection to determine the presence of microscopic involvement of lymph nodes. By the time that gross nodal metastasis is evident, survival rates have declined to zero. However, we do believe that because of the inadequacy of present diagnostic methods we should not hesitate to perform an exploratory operation if there is clinical suspicion that carcinoma persists after irradiative therapy. This approach is important in detecting persistent or recurrent disease in the central pelvis before metastasis to the lymph nodes makes curative operations impossible. We can no longer sit back complacently and watch patients after irradiative treatment—we must be vigorous in our attempts to detect the failure of irradiation at an early stage.

Summary

Surgery may be used for curative, diagnostic, or palliative purposes in patients having carcinoma of the uterine cervix. If a curative operation is contemplated, the surgeon should be capable of performing and have the necessary ancillary facilities for the most extensive surgical procedures. A brief review of our experiences with curative surgery is presented. Various palliative procedures have been outlined and a plea has been made for wider use of abdominal exploration where reasonable doubt exists either as to the extent of the patient's disease or to her response to irradiation. We believe that in most instances a well-planned and integrated course of irradiative therapy should be used primarily in the treatment of cervical carcinoma, and that surgery should be reserved for the so-called "irradiative failures."

References

1. Krieger, J. S.; Zeit, P. R.; Sindelar, P. J., and Hays, R. A.: Therapy for carcinoma of uterine cervix; part I: irradiation. *Cleveland Clin. Quart.* **25**: 121-124, 1958.
2. Blaikley, J. B.; Kottmeier, H. L.; Martius, H., and Meigs, J. V.: Classification and clinical staging of carcinoma of uterus; proposal for modification of existing international definitions. *Am. J. Obst. & Gynec.* **75**: 1286-1291, 1958.
3. Krieger, J. S., and McCormack, L. J.: Indications for conservative therapy for intraepithelial carcinoma of uterine cervix. *Am. J. Obst. & Gynec.* **76**: 312-319; discussion, 319-320, Aug. 1958.
4. Turnbull, R. B., Jr., and Higgins, C. C.: Ileal valve pouch for urinary tract diversion; preliminary report of eight cases. *Cleveland Clin. Quart.* **24**: 187-192, Oct. 1957.
5. Krieger, J. S.: Surgical approach to cervical carcinoma. *Cleveland Clin. Quart.* **21**: 27-30, 1954.