

# Cleveland Clinic Quarterly

---

Volume 25

OCTOBER 1958

No. 4

---

## ELECTIVE PLASTIC REPAIR OF CONGENITAL DEFECTS

ROBIN ANDERSON, M.D., and ELDON R. DYKES, M.D.\*

Department of Plastic Surgery

IT is not surprising that the parents of an infant recently born with a congenital anomaly are interested primarily in how soon the defect can be repaired. It would be ideal if all such procedures could be carried out immediately after birth. Of course, if immediate repair is essential to survival, it matters little whether or not the immediately postnatal period is the time of election for operation. Most congenital anomalies, particularly those managed by the plastic surgeon, tolerate postponement until the optimum time for surgical repair. This particular moment varies considerably, not only from patient to patient, but from surgeon to surgeon. For example, one surgeon may elect to repair a cleft lip as soon as possible after delivery, while another defers treatment for six or more weeks. Various factors such as inadequacy of available anesthesia, unsatisfactory operating room facilities, or inadequate nursery care may also influence this decision.

From the practical standpoint, it is possible to set up several criteria that are useful in determining the ideal times for these procedures. First, the mortality associated with the elective operation must be small, and the time selected for the procedure should not modify this figure. Second, subsequent function and normal growth should be interfered with as little as possible. Finally, the feelings of the infant's parents cannot be ignored. It frequently is cruel if not impossible to keep emotionally distraught parents waiting weeks or years for the arrival of the ideal date.

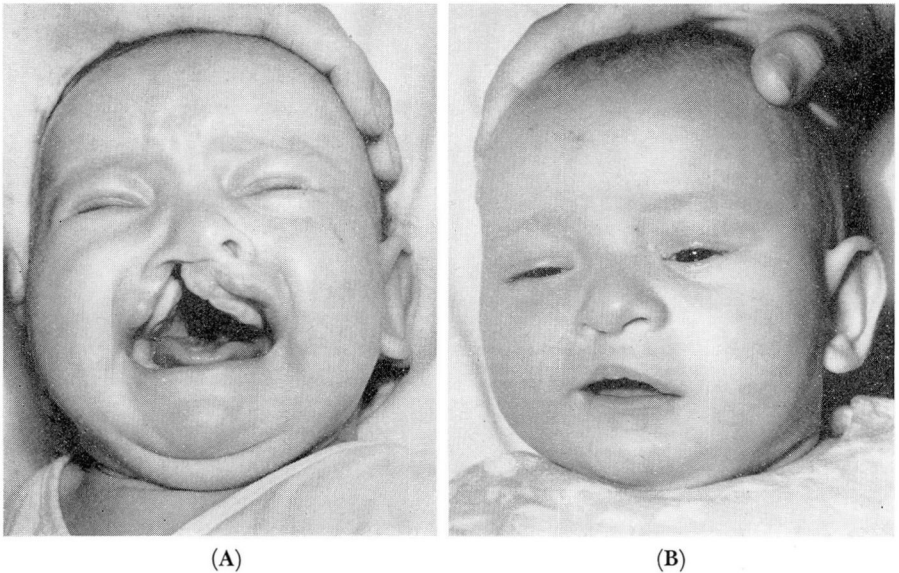
The plastic surgeon is called upon to repair a number of these congenital anomalies, specifically those in which subsequent cosmetic appearance is a

\**Chief Resident in Surgery.*

factor, and those for the repair of which various plastic technics are required. The most common defects are cleft lip, cleft palate, deformities of the external ear, webbed fingers, hypospadias, congenital ptosis of the eyelid, and anomalies of branchial cleft origin. The purpose of this paper is to present a brief discussion of procedures of choice and a reasonable timetable for their surgical repair.

### Cleft Lip and Palate

Cleft lip, cleft palate, or the combined defect is found once in approximately 800 newborn infants. Surgical procedures for their primary repair have become reasonably well standardized and the probability of good cosmetic and functional results is high (Fig. 1).



**Fig. 1.** (A) Preoperative photograph of a three-month-old infant with wide unilateral cleft lip. (B) Photograph showing results after repair by the triangular flap method.

For the unilateral cleft lip, most plastic surgeons employ a flap repair using either a triangular or a square flap just above the lip vermillion, to overcome the problems inherent in linear approximation of the lip margins.<sup>1</sup> Repair of the double lip requires similar closures on each side, usually carried out in one operation. The time of choice for this repair is the immediately postnatal period. The earlier that surgery is completed, the less the emotional trauma that is inflicted on anguished parents. Moreover, the infant tolerates the procedure well, whether it be carried out on the day of birth or within the first few weeks thereafter. After postoperative hospitalization of nine or 10 days, the essentially normal-appearing infant is returned to his mother only a few days after her own discharge from the hospital.

There has been and continues to be sporadic argument as to the advisability of early repair of the cleft palate. Some surgeons recommend postponement of repair until the child is five or more years old, on the ground that facial bone development is interfered with by early repair. The evidence for this interference is inconclusive, and the majority of plastic surgeons recommend surgical repair when the child is between 14 and 18 months of age.<sup>2</sup> This period of time allows considerable growth both of the oral cavity and of the palatal flaps, and at the same time assures closure of the palate before improper speech habits have become established. The Von Langenbach operation, with its lateral relaxing incisions and thorough undermining of the palate flaps, is employed. Set-back operations designed to lengthen the short palate may be used at the time of primary closure, but usually are deferred until such time as a real need for such lengthening is demonstrated.

### Deformities of the External Ear

The so-called "lop-ear" deformity, or prominent ears, is associated either with an insufficiently sharp, or an absent ante-helix. Its proper repair requires complete breaking of the cartilage spring, with removal of a strip of cartilage, if necessary, to make an ante-helix stand out from the head at normal height (Fig. 2). The primary consideration as to time of operation is that it be prior to school

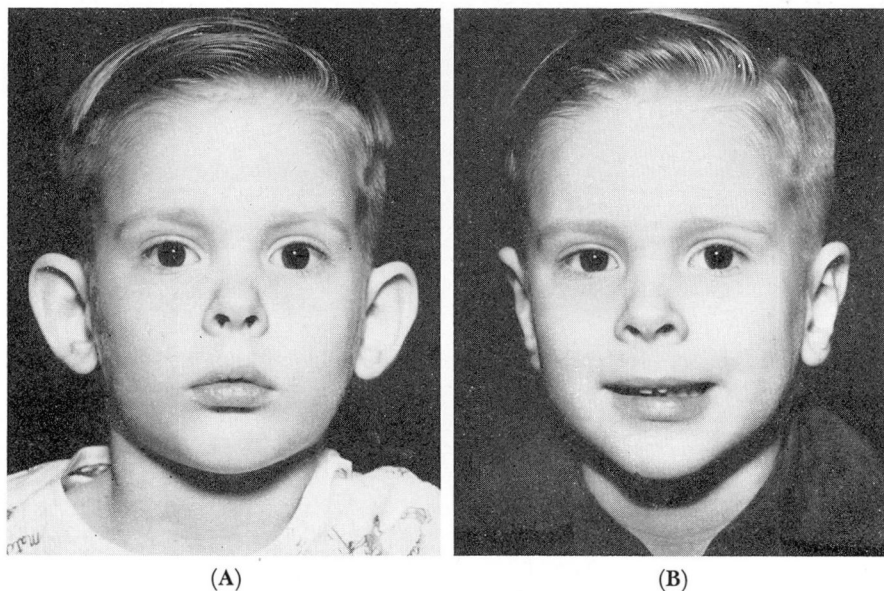


Fig. 2. (A) Preoperative photograph of a four-year-old child with bilaterally prominent ears (B) Photograph showing results after surgical repair.

age, to avoid the emotional complications incident to the inevitable teasing of young children at that time. Since a little co-operation on the child's part makes infinitely more pleasant the application of dressings, removal of sutures, and subsequent protection of the newly repaired ears, the operation usually is scheduled during the summer of his fourth or fifth year.

Congenital absence of all or part of an ear also is repaired at about this time, allowing approximately a full year for its completion.<sup>3</sup> The actual procedure consists of initial utilization of existing ear remnants to fit into the proposed reconstruction; implantation of shaped, preserved, or autogenous cartilage; and finally, elevation of the ear flap with the included cartilage and resurfacing of its medial surface and adjacent scalp with a skin graft. Absence of the associated external ear canal is repaired only if a bony canal and associated middle-ear structures can be roentgenographically demonstrated. Normal function of such a reconstructed canal also requires the presence of an ear drum.

### Webbed Fingers

The separation of webbed fingers and skin grafting of their raw surfaces is deferred until the immediately preschool age, provided that growth of the individual digits is proceeding normally and that there is no evidence of interference with function of any of the fused parts. The reasons for this choice of time are the larger size of the fingers, the increase in understanding of the older child and in his ability to co-operate. More fundamental deficiencies requiring bone and tendon repair or digit reconstruction may be taken care of at this age, but usually are deferred until considerably later because of the great need for patient education and co-operation (Fig. 3).

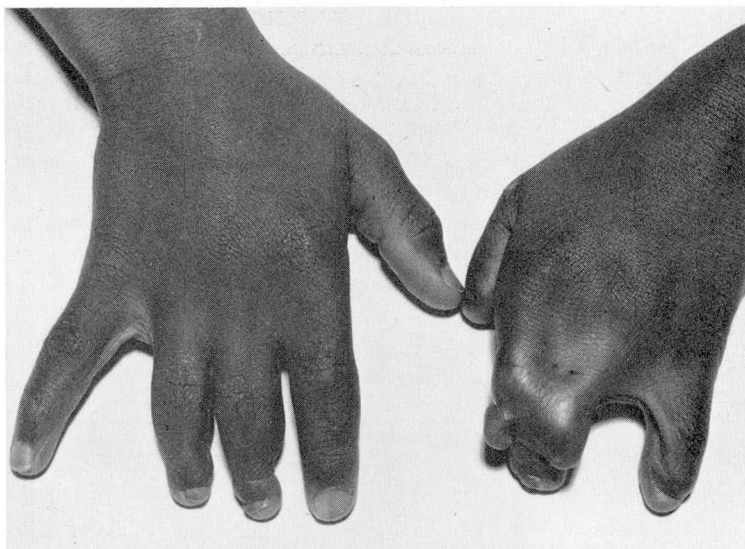
Webbed toes offer little cosmetic problem to the patient of any age and are repaired only rarely—and then only when such repair is demanded by anxious parents.

### Hypospadias

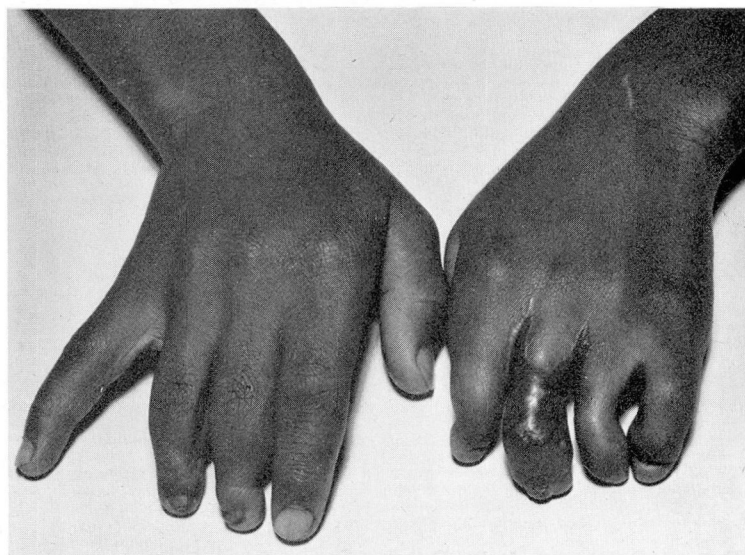
Several methods are available for the repair of hypospadias. All methods require meticulous removal of the fibrous tissue associated with the chordee. They differ only in the technic for constructing the skin-lined urethral channel on the shaft of the penis. The most common and probably most successful procedure is that in which the tube is constructed from local skin flaps.<sup>4</sup> Its completion requires either two or three operations during a period of from three to nine months, barring complications. Repair is deferred as long as possible to permit maximum penile growth and to obtain maximum co-operation from the patient. The requirement that a boy stand to urinate makes it necessary to proceed with the reconstruction prior to school age if the ridicule of schoolmates is to be avoided.



(A)



(B)



**Fig. 3.** (A) Preoperative photograph of the hands of a nine-year-old child with severe syndactyly already interfering with growth and function. (B) Photograph showing results after surgical repair.

### Congenital Ptosis of the Upper Eyelid

Congenital drooping of the upper eyelid may be partial or complete, unilateral or bilateral. If it is minimal, with almost normal function of the levator

muscle, the Blascovicz operation, in which the muscle itself is shortened, preserves optimal function as well as produces a good cosmetic result. If the degree of ptosis is moderate or severe, the procedure of choice is the insertion of a fascia lata sling attached superiorly to the fascia covering the frontalis muscle of the forehead. This allows full mobility of the eyelid controlled by the frontalis, without undue exposure of the globe at rest. A minimal deformity may be corrected at any time in the preschool period. The more severe deformity may result in visual difficulties, with positioning of the head and neck to permit vision beneath the ptotic lid. It is essential that repair be carried out before these complications develop and cause permanent damage.

### Anomalies of Branchial Cleft Origin

Most branchial cleft remnants are invisible or unnoticed at birth, becoming obvious only with the appearance of swelling or a fluid discharge through a small skin orifice on the neck. There is no particular time of choice for their elective repair; excision is advised when they are discovered, on the basis that sooner or later they will become infected and require surgical treatment under more difficult circumstances.

The small preauricular sinuses frequently occurring just anterior to the external ear often are considered as being branchial cleft remnants. There is little evidence to support this view; they more likely are sinuses associated with lines of fusion of the various embryonic segments of the ear itself. If they become infected, excision is necessary.

### Other Anomalies

Brief mention should be made of several less common anomalies. Congenital facial paralysis is fortunately only partial in most instances. If sufficient facial nerve function is present to provide even slight tone to the facial musculature, operative repair can do little to improve the condition and may do considerable damage to minimally functioning structures. In the absence of any demonstrable function, mechanical support by fascia lata may be employed in the childhood period, with the knowledge that additional surgery is practically inevitable. The use of masseter muscle slings or the like should be avoided, at least until adolescence. Exploration or graft of the facial nerve is of no value.

Facial hemiatrophy is a most difficult surgical problem for which no completely satisfactory solution has been proposed. Every possible material, from skin to shredded polyethylene, has been buried as a free graft beneath the skin to provide normal facial contours with little success. It appears that the recently reported dermal-fat pedicle,<sup>5</sup> i.e., a graft of fat with an attached layer of dermis and carrying its own blood supply, may offer the best approach. The evidence is good that such transplanted fat and dermis will survive without serious shrinkage.

References

1. Anderson, R.: Repair of cleft lip. *Cleveland Clin. Quart.* **21**: 180-186, 1954.
2. Bill, A. H., Jr.; Moore, A. W., and Coe, H. E.: Time of choice for repair of cleft palate in relation to type of surgical repair and its effect on bony growth of face. *Plast. & Reconstruct. Surg.* **18**: 469-473, 1956.
3. Steffensen, W. H.: Comments on reconstruction of external ear. *Plast. & Reconstruct. Surg.* **16**: 194-200, 1955.
4. Byars, L. T.: Functional restoration of hypospadias deformities; with a report of 60 completed cases. *Surg., Gynec. & Obst.* **92**: 149-154, 1951.
5. Neumann, C. G.: Use of large buried pedicled flaps of dermis and fat; clinical and pathological evaluation in treatment of progressive facial hemiatrophy. *Plast. & Reconstruct. Surg.* **11**: 315-332, 1953.