

# THE EFFECT OF IPRONIAZID OINTMENT ON TROPHIC ULCERS ASSOCIATED WITH RAYNAUD'S PHENOMENON

## *A Clinical Note*

ARTHUR L. SCHERBEL, M.D.,  
Department of Rheumatic Disease

GEORGE H. CURTIS, M.D.,  
Department of Dermatology

and

JOHN W. HARRISON, M.D.  
Department of Rheumatic Disease

**T**ROPHIC ulcers of the finger tips may occur as a complication of Raynaud's phenomenon. Usually they are painful and cause considerable discomfort. In general, therapy is unsatisfactory. Although sympathectomy often results in healing of the ulcers, they are likely to recur. Medical treatment with vasodilators and blocking agents are of questionable value.<sup>1</sup> The local application of glyceryl trinitrate has been reported<sup>2</sup> to be effective in the relief of Raynaud's phenomenon, though an annoying headache may occur as a side effect of treatment.<sup>3</sup> In our experience this treatment has had little influence on gangrenous ulcers.

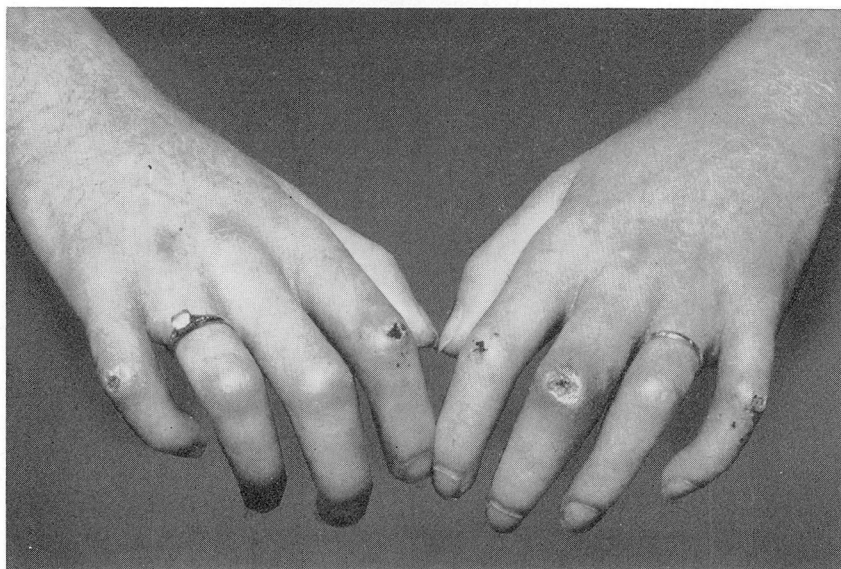
During the past five years we have used iproniazid\* ointment, from 2 to 5 per cent in a water-soluble base, in the treatment of 23 patients. This group consisted of 14 patients with progressive systemic sclerosis and five patients with acrosclerosis complicated by ulceration of the finger tips, two patients with systemic lupus erythematosus in whom painful ulcerations appeared over interphalangeal joints, and two patients with advanced Raynaud's disease in whom painful ulcerations of the finger tips developed within six months and one year, respectively, after sympathectomy.

The ointment was applied twice daily to the ulcers, and the fingers were wrapped lightly with gauze. Within from 24 to 72 hours pain disappeared, and after a few weeks the ulcers usually healed (Fig. 1). Of the group of 23 patients, 19 had complete relief of pain, and 18 had complete healing of the ulcers. However, eight patients had recurrence of pain and ulcers within from three weeks to six months after temporary discontinuation of the treatment.

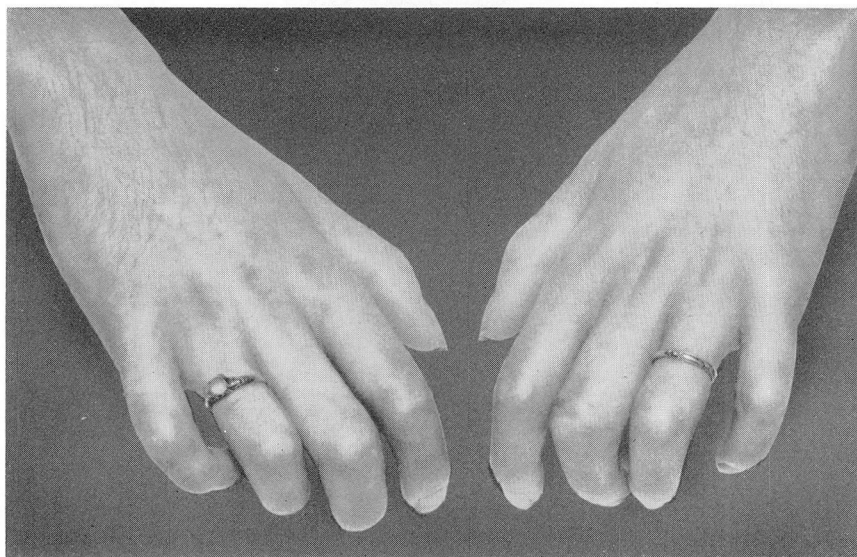
Intolerance to local applications of the ointment has not developed, and no complications from this medication have been observed. The mechanism responsible for the relief of pain as well as for the stimulation of healing of the ulcers has not been determined.

---

\*Marsalid phosphate, Hoffmann-LaRoche, Inc. The material for this study was supplied through the courtesy of Hoffmann-LaRoche, Inc., Nutley, New Jersey.



A



B

**Fig. 1. (A)** Painful trophic ulcerations over the proximal interphalangeal joints of a 24-year-old woman who had severe progressive systemic sclerosis. **(B)** Complete healing of ulcers 19 days after 3 per cent iproniazid ointment was applied twice daily. Pain diminished within 24 hours after the ointment was applied.

### Summary

1. Trophic ulcers associated with Raynaud's phenomenon are painful and often difficult to treat.
2. In a series of 23 patients who had trophic ulcers occurring as a complication of Raynaud's disease or secondary Raynaud's phenomenon, the application of iproniazid ointment often resulted in decrease of pain and healing of the ulceration. When treatment was discontinued, pain and ulceration sometimes recurred.
3. The pharmacologic action has not been determined.

### References

1. Scherbel, A. L.: Raynaud's disease and Raynaud's phenomenon. *Am. Pract. & Digest Treat.* 4: 266-270, April 1953.
2. Kleckner, M. S., Jr.; Allen, E. V., and Wakim, K. G.: Effect of local application of glyceryl trinitrate (nitroglycerine) on Raynaud's disease and Raynaud's phenomenon; studies on blood flow and clinical manifestations. *Circulation* 3: 681-689, May 1951.
3. Allen, E. V.; Barker, N. W., and Hines, E. A., Jr.: *Peripheral Vascular Diseases*, ed. 2. Philadelphia: W. B. Saunders Company, 1955, p. 84 (825 pp.).