

ELECTRONIC CARDIAC PACEMAKER AFTER OPEN-HEART OPERATIONS

Report of a Case of Tetralogy of Fallot with Atrioventricular Block That Reverted to Sinus Rhythm

FREDERICK OLMSTED, WILLEM J. KOLFF, M.D.,
Division of Research

and

DONALD B. EFFLER, M.D.
Department of Thoracic Surgery

SINCE the advent of open-heart operations, surgical damage to the conduction system during operation has become prevalent. Complete atrioventricular (AV) block cannot always be avoided and has been a factor contributing to mortality, either immediately after the operation or later. Now, complete AV block has become reversible by means of cardiac pacemakers. A cardiac pacemaker provides a rhythmic electric stimulus to the ventricles to increase the ventricular rate. If the stimulus is adequate, the ventricles accept the rhythm imposed by the pacemaker, provided that it is faster than the intrinsic ventricular rhythm. Experimentally, in a dog with a sinus rhythm of 85 beats per minute, a heart rate of 90 can be imposed by the pacemaker, but not a rate lower than 85 (Fig. 1). In a dog with heart block and a ventricular rate of 40, any rate in excess of 40 can be imposed.

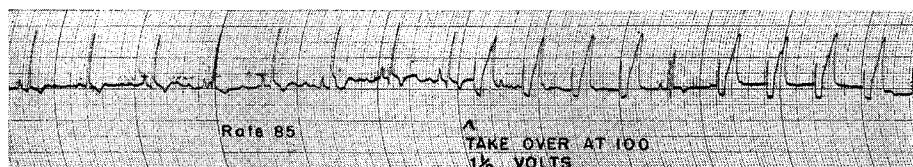


Fig. 1. Electrocardiogram of a dog in which were implanted myocardial electrodes. A normal ventricular rate of 85 was supplanted by an imposed pacemaker rate of 100.

Zoll¹ has designed a pacemaker for use with external electrodes. He advocates this mainly for treatment of diseases such as heart block with Stokes-Adams syndrome. Burchell² uses a pacemaker with external electrodes to maintain the ventricular rate in patients who have AV block after open-heart operations.

Allen and Lillehei³ use a pacemaker that is connected to one electrode on the myocardium and to one under the skin. They have lost only one patient from AV block, of 40 consecutive patients who underwent open-heart operations. That patient, a child, died after he himself tore out the myocardial electrode. Allen and Lillehei³ have noted that in most cases of surgical AV block the heart regains a normal sinus rhythm if the patient is maintained for a few days at an

This work was supported by a grant to Doctor Kolff from the Cleveland Area Heart Society.

adequate ventricular rate by the pacemaker. Even if the sinus rhythm cannot be restored and the ventricular rate is to remain permanently slow, the heart has adequate time to adjust to the new slow rate.

One elaborate pacemaker^{4,5} amplifies the sinus (P) waves with transistors and a hearing-aid battery; the artificial impulse is applied directly to the ventricles.

An increase in ventricular rate, notwithstanding heart block, can be obtained in some patients by administration of chronotropic drugs, such as, isopropylar-terenol hydrochloride. Some patients, however, are quite refractory to the drug, or become so, and an adequate cardiac output can be attained only by electric stimulation.

To undertake open-heart operations without a pacemaker at hand no longer seems justifiable. We use the pacemaker described below, when AV block is recognized during the operation.

Description of Electronic Pacemaker

The internal electrodes are made of 26-gauge stainless-steel stranded wires 15/1,000 inch in diameter coated with Teflon* except for the tips. When in use, the electrodes are sutured against the ventricular myocardium in two places. This has the advantages that low current and voltage can be used and that even if one electrode does slip out, it can be placed on some other part of the body and the other electrode still can drive the heart.

The circuit of the pacemaker is designed to meet three requirements (Fig. 2). The terminals to be used on the patient are carefully isolated by an output transformer for the possibility of line-voltage connection. The output impedance is low, matching that of the myocardium, in order to avoid distortion of the wave contour in the myocardium and to insure that the stimulus voltage is that indicated by the control setting. The shape of the stimulus wave is a round-topped spike of less than a millisecond in duration and is rectified so that it is completely monophasic.

A conventional regulated power supply is led to a multivibrator; its frequency (stimulus rate) is controlled by a variable grid bias. The multivibrator activates a neon indicator lamp, the signal is then rectified and is applied to a power tube. The output from this tube is connected by an isolation transformer through another rectifier to the patient.

Case Report

The patient was a 5½-year-old girl who had tetralogy of Fallot. When she was one and one-half years old, she underwent operation for relief of severe anoxic episodes,

*Manufactured by Falls Hollow Staybolt Company, Cuyahoga Falls, Ohio.

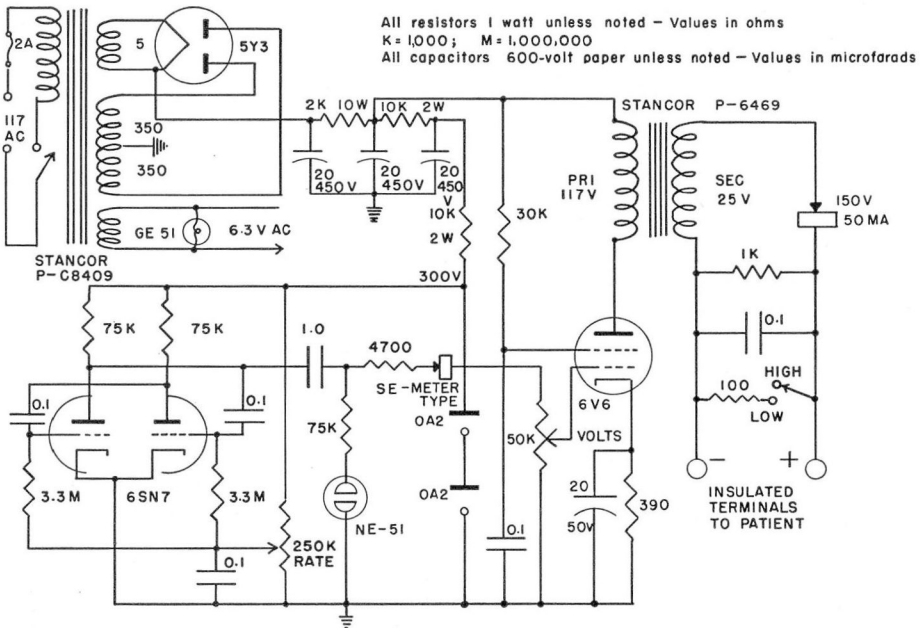


Fig. 2. Schematic diagram of an electronic pacemaker designed for direct connection to the ventricular wall.

comprising a Potts anastomosis* between the pulmonary artery and the aorta. Post-operatively, however, there were some cyanosis, and clubbing of the fingers. At the time of examination at the Cleveland Clinic, cardiac catheterization studies were instituted and pressures in the right ventricle were found to equal those in the left. Movie films made with the Philips image amplifier disclosed a high interventricular septal defect, severe infundibular stenosis, valvular pulmonic stenosis, and 60 per cent dextroposition of the aorta. It was decided to close off the Potts anastomosis and to attempt intracardiac repair using the open-heart approach.

During the operation the patient was maintained with extracorporeal circulation by means of a 13-inch Kay and Cross oxygenator** and a nonocclusive roller-type plastic tube pump at a flow rate of 90 ml. per kilogram of body weight per minute. The total duration of the run was 48 minutes; the duration of total bypass was 32 minutes; the heart was arrested for 24 minutes. Since it was not possible to estimate the time required to close the Potts anastomosis, two arterial cannulae were used, one in the subclavian artery and one in the left common femoral artery, so that even if the aorta had to be clamped on both sides of the anastomosis, both upper and lower parts of the body still would be able to receive blood. In addition to the usual cannulae placed in the venae cavae, another cannula was placed in the left atrium to control any possible build-up of back pressure in the pulmonary veins.

After the artificial heart-lung had been started, the Potts anastomosis was carefully isolated and closed with a double silk ligature. Then the heart was electively arrested with potassium citrate solution. The right ventricle was opened from its midpoint to the

*Performed by Dr. Willis Potts, Children's Memorial Hospital, Chicago, Illinois.

**Manufactured by Pemco, Inc., 5663 Brecksville Road, Cleveland 31, Ohio.

annulus of the pulmonary valve, which was incised to relieve the valvular stenosis. A large mass of abnormal muscular tissue was sharply dissected from the ventricular septum and the anterior wall of the ventricle. The interventricular septal defect, about $\frac{7}{8}$ inch in diameter, was closed by an oval patch of Ivalon sponge carefully attached with 12 interrupted sutures. After closure of the ventricular incision, the clamp was removed from the aorta, and the heartbeat started within one minute; however, total AV block was present. The ventricular rate was adequate, but, since we knew from previous experience that it might decrease later, the stainless-steel ends of the two fine electrodes were sutured to the ventricular wall on both sides of the heart and were brought out through stab wounds for connection to the pacemaker. A short trial proved that the pacemaker was able to supplant the ventricular rhythm. The postoperative course was uneventful except for the symptoms of heart block which are described below.

At 12:00 noon, immediately after operation, the patient's heart rate was first maintained with the pacemaker at a rate of about 80. A postoperative chest roentgenogram showed the two electrodes to be in position on both sides of the heart (Fig. 3). At 5:20 p.m.

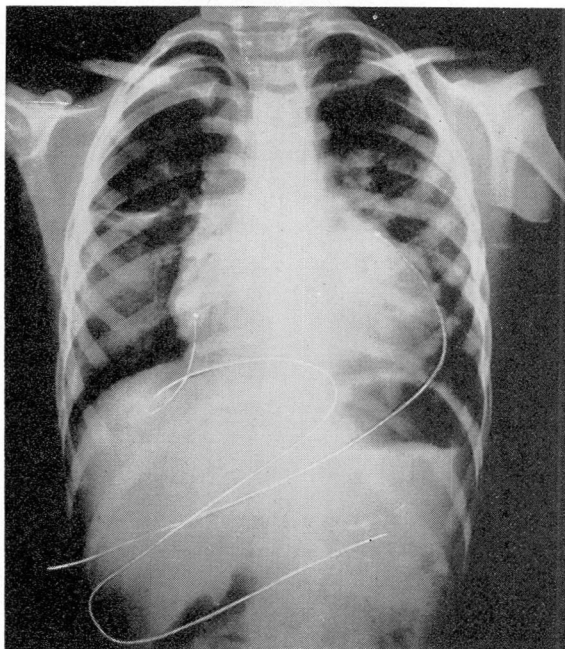


Fig. 3. Postoperative chest roentgenogram that shows the thin stainless-steel (Teflon-coated) wires on either side of the heart, where they are sutured against the myocardium.

that day the pacemaker was disconnected because the patient was able to maintain a heart rate between 70 and 80, although there still was a total block. During the night, however, the pulse rate gradually decreased to 60; the following morning, when it had decreased to 54, she was returned to pacemaker stimulation. The rate was set for between 80 and 90 beats per minute.

The preoperative electrocardiogram is shown in (Figure 4, 7). That taken while the pacemaker was functioning showed that the ventricular rate of about 85 usually followed

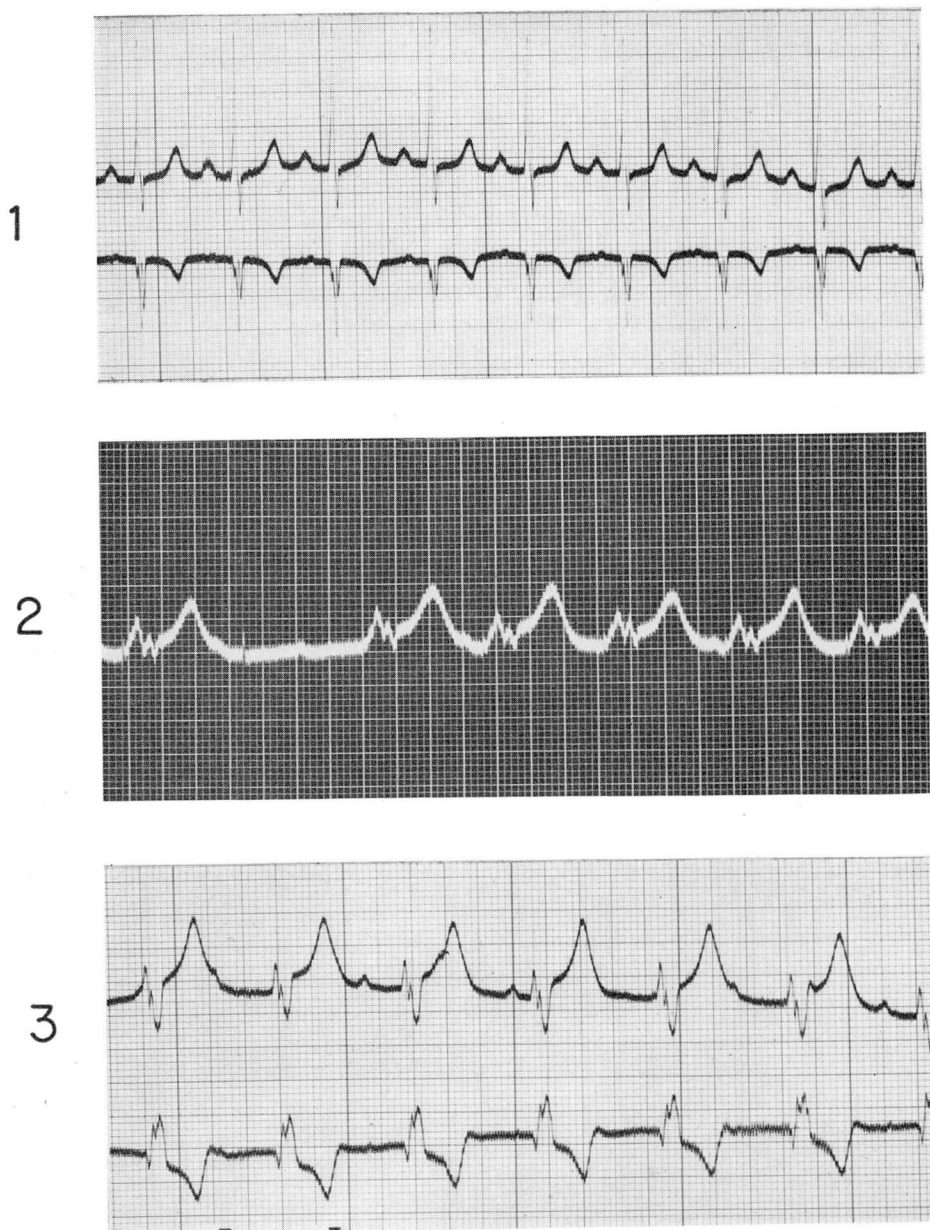


Fig. 4. Electrocardiograms: (1) immediately preoperative—sinus rhythm rate was 100; (2) first postoperative day—ventricles follow pacemaker at a rate of 83 except for one missed beat; (3) fourth postoperative day—AV block; ventricular rate was 80.

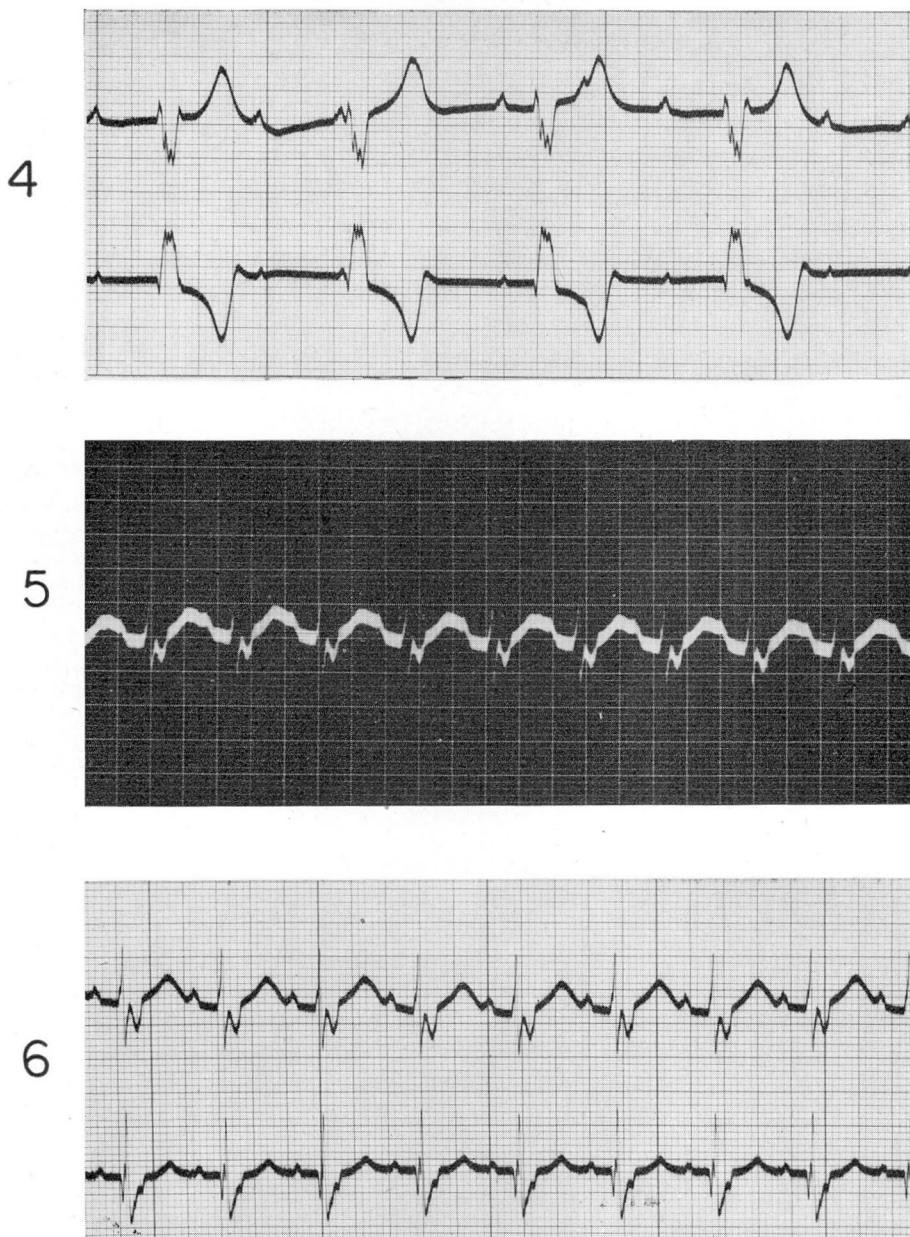


Fig. 5. Postoperative electrocardiograms: (4) seventh day—AV block; ventricular rate decreased to 55; (5) twelfth day—a high ventricular rate of 115 was outrunning the pacemaker that had been set at about 80; it proved to be the sinus rhythm; (6) thirteenth day—heart rate had decreased to 100 beats per minute.

with but an occasional missed beat (Fig. 4, 2.). On the second day after operation the patient became restless if the pulse did not follow the pacemaker, or when the pulse fell to between 48 and 50 while the pacemaker was off. The voltage of the pacemaker had to be increased to 7 volts (from 5 volts) to obtain a pulse rate of 80 in response to an electric pulse rate of 88. On the third day after the operation the pacemaker was removed because with or without it an idioventricular rate of 80 was maintained. The electrocardiogram made on the fourth postoperative day revealed a total AV block with a ventricular rate of about 80 (Fig. 4, 3). For the next few days the patient's clinical condition was satisfactory, although the electrocardiograms consistently showed a complete AV block with a ventricular rate of about 80. However, on the eighth postoperative day the ventricular rate decreased to 64. An electrocardiogram made on the eleventh postoperative day still showed complete AV block with a ventricular rate of about 55 (Fig. 5, 4); at 2:30 p.m. the pacemaker was reconnected to obtain a ventricular rate of about 80. Cessation of the pacemaker caused return to complete AV block with a heart rate of about 54. At 11:00 a.m. on the twelfth postoperative day the patient suddenly had a pulse rate of 100 while the pacemaker was set to maintain a ventricular rate of 80. An electrocardiogram revealed a sinus rhythm with a ventricular rate of 115, which made the pacemaker superfluous (Fig. 5, 5). The heart rate slowed down during the following days, as shown on an electrocardiogram made on the thirteenth day (Fig. 5, 6).

By this time the patient's general condition was excellent. She was extremely gay and happy, and moved freely about in the bed with the wires trailing behind her. There was no evidence of myocardial insufficiency. The electrodes were withdrawn from the heart simply by removing the surgical tapes that held them to the chest and then pulling them out. The patient was discharged on the eighteenth postoperative day.

During the twelve days in which the pacemaker was intermittently used, it became necessary gradually to increase the impulse from 5 to 16 volts. The patient seemed to be unaware of the electric impulse at all times.

Summary

Experience with the course of open-cardiotomy patients with heart block leads us to recommend that electrodes be placed on the heart of any patient in whom atrioventricular block occurs during operation, even though the ventricular rate appears to be satisfactory at the time. The cardiac pacemaker should be used in children whose ventricular rates fall below 90, and in adults whose rates drop below 80.

A cardiac pacemaker with internal electrodes was used successfully on a postcardiotomy patient whose 12-day, complete heart block was carried to recovery. It is recommended that a cardiac pacemaker be available at the time that all intracardiac operations are performed.

References

1. Zoll, P. M.; Paul, M. H.; Linenthal, A. J.; Norman, Leona R., and Gibson, W.: Effects of external electrical currents on heart; control of cardiac rhythm and induction and termination of cardiac arrhythmias. *Circulation* 14: 745-756, Nov. 1956.

ELECTRONIC CARDIAC PACEMAKER

2. Burchell, H. B.: Clinical problems related to surgical repair of intracardiac defects with aid of extracorporeal pump-oxygenator. *Circulation* **16**: 976-987. Dec. 1957.
3. Allen, P., and Lillehei, C. W.: Use of induced cardiac arrest in open heart surgery; results in 70 patients. *Minnesota Med.* **40**: 672-676, Oct. 1957.
4. Folkman, M. J., and Watkins, E.: Artificial conduction system for management of experimental complete heart block. *Surgical Forum*: In press; personal communication.
5. Vanderschmidt, C. F.: Transistor pulse amplifier and pulse output circuit for heart block work. *Surgical Forum*: In press; personal communication.