

LEIOMYOMA OF THE TRACHEA

Report of a Case

LAURENCE K. GROVES, M.D.,

Department of Thoracic Surgery

WILLIAM R. BIDDLESTONE, M.D.,

Department of Pulmonary Disease

and

LAWRENCE J. McCORMACK, M.D.

Department of Pathology

TUMORS rarely occur in the trachea and most of those that do occur are malignant. We are reporting a case of an unusual benign neoplasm, a leiomyoma, of the trachea which we believe is the sixth such case to be recorded in the literature.

Moersch, Clagett, and Ellis¹ in reviewing 82 cases of tracheal neoplasms classified 35 as benign and 47 as malignant tumors. However, with the exception of one, a chondroma, the lesions that they classified as benign tumors often are considered not to be truly neoplastic: papilloma, tracheopathia osteoplastica, amyloid tumor, and xanthoma. Malignant tracheal tumors are most commonly either carcinomas indistinguishable from bronchogenic carcinomas, or "cylindromas." It has been traditional to group carcinomas of cylindromatous pattern and adenomas of carcinoid structure under the term *bronchial adenoma*. We believe that this grouping is illogical because it infers that a "cylindroma" is a benign tumor. The carcinoid bronchial adenoma is a relatively benign lesion; however, by comparison, the cylindromatous carcinoma, which tends to occur more proximally in the respiratory tract, is definitely carcinomatous and usually lethal. Cylindromatous carcinoma in the respiratory tract is rare; no cases have been seen at the Cleveland Clinic since 1948, yet in these past 10 years carcinoid bronchial adenoma has been diagnosed in 21 patients.²

A few benign or malignant smooth-muscle tumors of the respiratory tract have been reported.³⁻⁵ We have found references to only five, all leiomyomas, occurring in the trachea. Dorenbusch⁶ reported one case in which a leiomyoma occurred a short distance below the right vocal cord on the tracheal wall; the neoplasm was removed via a cervical approach to the trachea. Greer and Winn⁷ described another case in which a leiomyoma occurred in the terminal trachea arising from the membranous portion, and obstructed both main bronchi; the tumor was removed transtracheally via a right thoracotomy. Unger⁸ reported a leiomyoma of the trachea in a 15-year-old girl; the tumor was treated bronchoscopically on three occasions and, according to Greer and Winn,⁷ subsequently required open thoracotomy. Two other cases were cited, but no details were given, in a review by Gilbert, Mazzarella, and Feit.⁹

Report of Case

A 56-year-old man had episodes of coughing, wheezing, and shortness of breath, symptoms that had become progressively more frequent and more severe during the four years before examination in May 1955. The symptoms initially occurred only at night but later appeared at any time. In describing his respiratory distress, the patient stated that it felt as though a ball valve allowed him to inspire but prevented his expiration. On physical examination the initial impression was that the patient had bronchial asthma; but, for thoroughness, bronchoscopic examination was performed. At that examination a polypoid tumor, movable on a broad base, was found arising from the membranous portion of the trachea approximately half way between the larynx and the carina. When observed at expiration the mass was seen to fall completely across the lumen of the trachea. The tumor was soft and could be readily passed anteriorly by the bronchoscope.

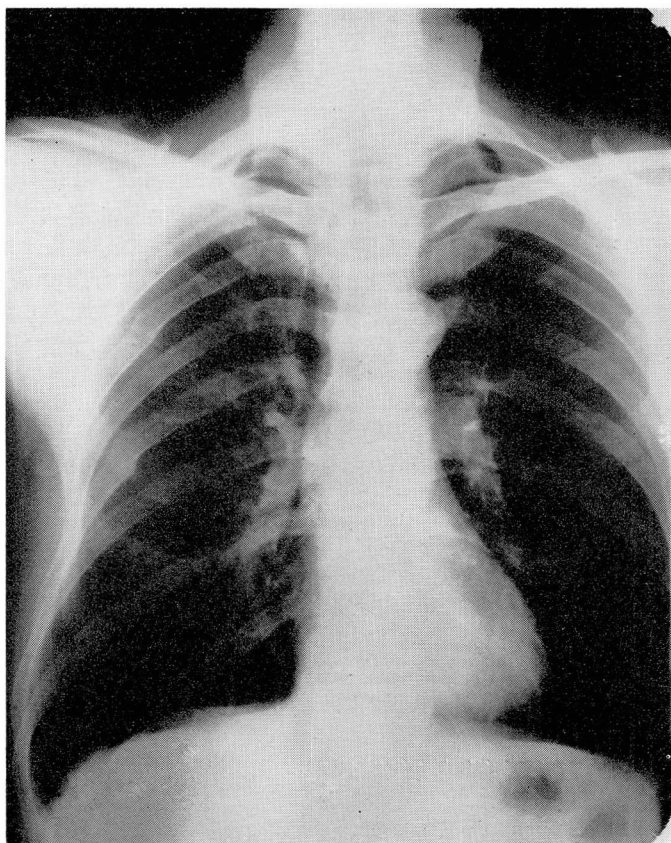
Roentgenograms of the chest demonstrated the valuable assistance that a lateral view can give. The appearance of the anterior-view roentgenogram was normal (Fig. 1A), but on the lateral-view roentgenogram, a small shadow could be seen in the superior mediastinum superimposed on the tracheal outline (Fig. 1B).

Because the tumor completely filled the trachea on expiration and because of the danger of further obstruction as a result of the trauma of bronchoscopic manipulation, the patient was hospitalized immediately and surgically treated the following day. The anesthesiologist attempted to pass a long endotracheal tube beyond the neoplasm, but some respiratory obstruction was still apparent until the chest was opened by a right thoracotomy. The tip of the endotracheal tube was then properly positioned distal to the neoplasm by direct palpation of the trachea. After the trachea was mobilized, the tumor was readily palpable immediately below the thoracic inlet. The posterior membranous trachea was incised and the tumor, including its base, was removed by sharp dissection, leaving a defect in the tracheal mucosa approximately 1 cm. in diameter. The defect was readily closed transversely with fine silk sutures.

Pathologic examination of the operative specimen revealed a smooth, glistening mass, measuring 25 by 20 by 20 mm. (Fig. 2). It seems remarkable that a mass of this size allowed sufficient airway for maintenance of life. (The cross section of the average trachea is stated to be 16.5 by 14.4 mm.¹⁰) The mass was composed of white tissue that was firm and rubbery.

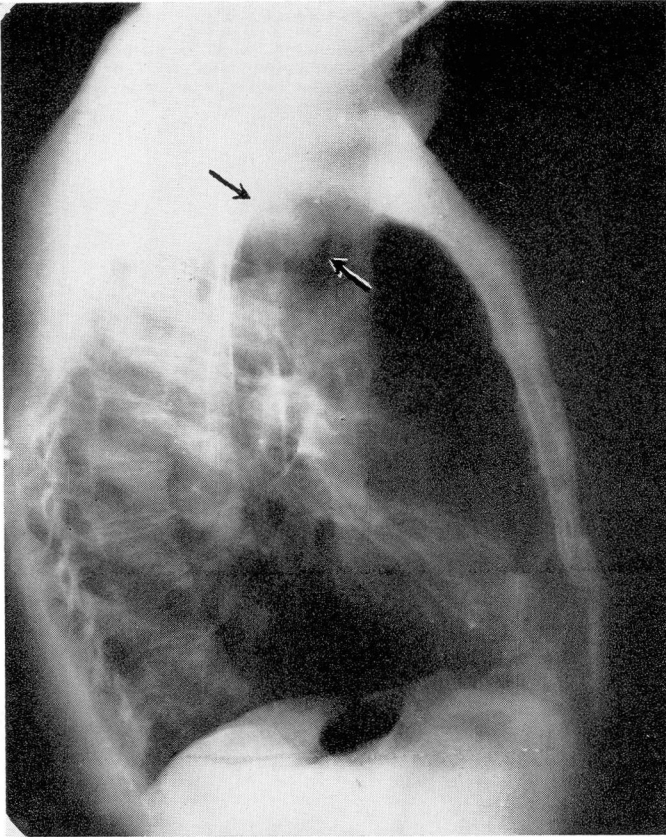
Microscopically, the tumor in large part was covered by stratified squamous epithelium. The underlying neoplasm consisted of long, slender, spindle cells arranged in anastomosing bundles (Fig. 3). The individual cell nuclei were elongated and uniform in size and shape. The nuclear chromatin was dispersed finely throughout the nucleus. No mitosis was seen. Mallory's phosphotungstic acid hematoxylin stain demonstrated relatively coarse intracellular fibrils. The fibrils occasionally terminated in small hooks (Fig. 4). Masson's trichrome stain outlined red-staining interlacing bundles of spindle cells that were separated from each other by delicate bands of green-staining collagen. No invasion of the base was apparent.

Postoperative course. The patient has been asymptomatic since operation. Findings were normal on bronchoscopic examination performed two years postoperatively. The site of the previous neoplasm could not be identified.



A

Fig. 1. Discrepant findings on roentgenograms of the chest. **A**, normal findings on the classic type of roentgenogram.



B

Fig. 1. B, lateral-view roentgenogram; arrows point to tumor mass.

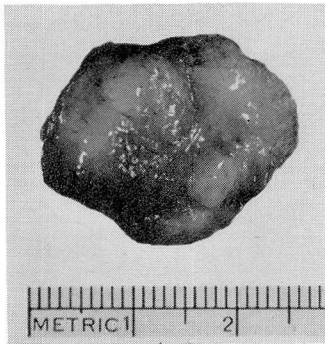

Fig. 2. Photograph of surgically removed tumor. Note its size. It was situated entirely within the tracheal lumen.

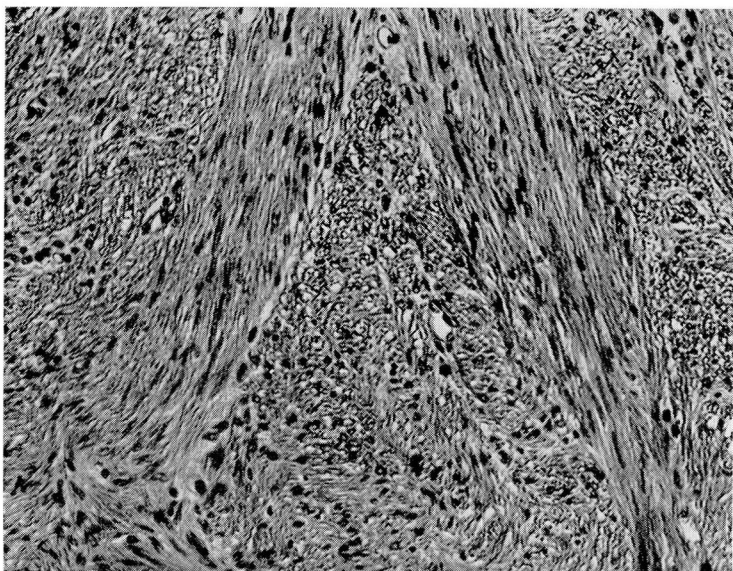


Fig. 3. Photomicrograph showing interlacing bundles of spindle cells. Hematoxylin-eosin and methylene blue; X 240.

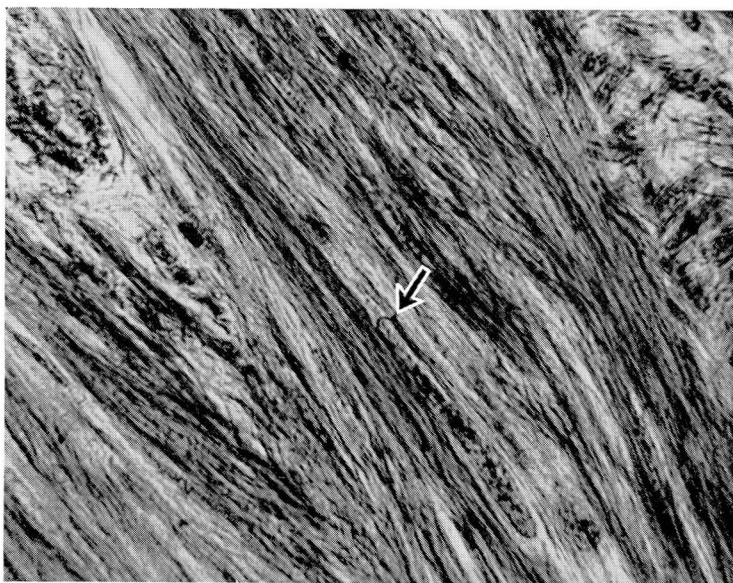


Fig. 4. Photomicrograph showing coarse intracellular fibrils. A small hook characteristic of myofibril termination is present. Mallory's phosphotungstic acid hematoxylin stain; X 700.

Summary

A case of leiomyoma of the trachea is reported because of its unusual nature and dramatic, favorable response to treatment. Because of his severe wheezing, the patient at first was considered to be asthmatic. Organic respiratory obstruction may closely mimic asthma, and frequently the two conditions may be differentiated only by endoscopic examination.

References

1. Moersch, H. J.; Clagett, O. T., and Ellis, F. H., Jr.: Symposium on bronchial and pulmonary disease; tumors of trachea. *M. Clin. North America* **38**: 1091-1096, July 1954.
2. Knesevitch, E. M.; McCormack, L. J.; Effler, D. B., and Groves, L. K.: Bronchial adenoma: clinicopathologic study of 21 cases. *Cleveland Clin. Quart.* **24**: 160-173, July 1957.
3. Freireich, K.; Bloomberg, A., and Langs, E. W.: Primary bronchogenic leiomyoma. *Dis. Chest* **19**: 354-358, March 1951.
4. Randall, W. S., and Blades, B.: Primary bronchogenic leiomyosarcoma. *Arch. Path.* **12**: 543-548, Nov. 1946.
5. Hirose, F. M., and Hennigar, G. R.: Intra-bronchial leiomyoma. *J. Thoracic Surg.* **29**: 502-511, May 1955.
6. Dorenbusch, A. A.: Leiomyoma of trachea; case report. *A.M.A. Arch. Otolaryng.* **61**: 470-471, April 1955.
7. Greer, A. E., and Winn, G. L.: Leiomyoma of trachea; case report. *J. Thoracic Surg.* **33**: 237-241, Feb. 1957.
8. Unger, L.: Recognition of nonallergic asthma. *Dis. Chest* **22**: 671-684, Dec. 1952.
9. Gilbert, J. G.; Mazzarella, L. A., and Feit, L. J.: Primary tracheal tumors in infant and adult. *A.M.A. Arch. Otolaryng.* **58**: 1-9, July 1953.
10. Brash, J. C., Editor: *Cunningham's Text-Book of Anatomy*, ed. 9. New York: Oxford University Press, 1951, p. 704 (1604 pp.).