

# OBSERVATIONS CONCERNING RENAL CIRCULATION

## *Angiography of Kidneys Removed from Hypertensive or Normotensive Patients*

THOMAS F. MEANEY, M.D.,

Department of Radiology

ALFRED E. DODSON, M.D.,\* EUGENE F. POUTASSE, M.D.,

Department of Urology

and

LAWRENCE J. McCORMACK, M.D.

Department of Pathology

SINCE aberrations in the renal circulation in experimental animals can be demonstrated by angiography,<sup>1-5</sup> the present study was undertaken for two purposes: (1) to determine whether there are roentgenographically detectable alterations in the arterial system of kidneys removed from hypertensive patients; and (2) if such alterations are present, to determine whether they can be recognized by clinical renal angiography.

### Material and Methods

Twenty-nine excised kidneys were selected from necropsy or from surgical specimens. Sixteen of the kidneys were from hypertensive and 13 from normotensive patients.

*Angiography of excised kidneys.* A barium-latex suspension having a particle size of approximately 30 microns was injected through a cannula into the main renal artery of each kidney. This particle size prevented the passage of the material through the capillaries into the venous system. To obtain good renal filling, the suspension was injected by manometric control under a pressure greater than the patient's usual diastolic pressure by from 10 to 20 mm. Hg. In a few instances higher pressures were used, but there was no apparent increase in the vascular filling. The cannula was removed and the vessels were ligated. Roentgenograms of the kidney were then made using a cardboard technic with a 40-inch focal-film distance. The technical factors were 50 milliamperes, 35 kilovolts, and  $1\frac{1}{2}$  seconds.

### Findings

The pathologic diagnoses of the conditions of the 29 kidneys are listed in Table 1.

*Arterial system in normal kidneys from normotensive patients.* The roentgenograms of the three normal kidneys (Group 1, Table 1) were notable because of three

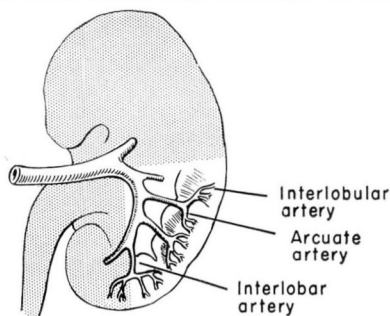
---

\*Formerly Fellow in the Department of Urology; present address, West 511 22nd St., Spokane, Washington.

features (Fig. 1): (1) uniformity of luminal size in the large and medium-sized vessels and the interlobar and arcuate arteries; (2) good filling of the interlobular arteries (cortical arterioles) that usually arise in a fanlike pattern from the arcuate arteries and supply the cortex of the kidney; and (3) uniform distribution of those terminal vessels that extend almost to the periphery of the renal parenchyma (Diagram 1, Fig. 1).

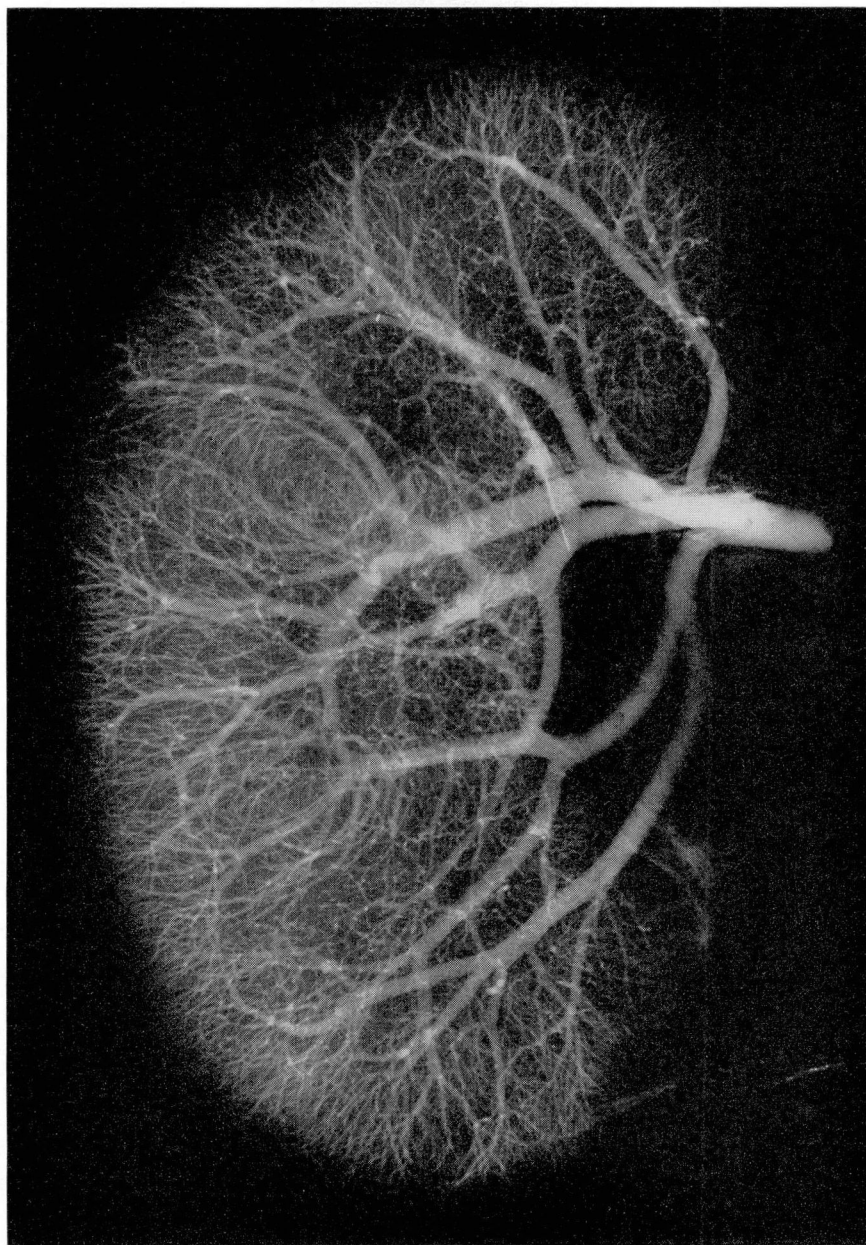
**Table 1.**—*Pathologic diagnoses of conditions of kidneys excised from 29 hypertensive or normotensive patients*

Group	Pathologic diagnosis	Number of patients,		
		total	hyper- tensive	normo- tensive
1	Normal	3	0	3
2	Vascular disease	10		
	Arteriolar nephrosclerosis . . . . .	8	8	0
	Polyarteritis nodosa . . . . .	1	0	1
	Aneurysm of renal artery . . . . .	1	0	1
3	Disease of glomerulus	6		
	Glomerulonephritis . . . . .	4	4	0
	Intercapillary glomerulosclerosis . . . . .	1	1	0
	Lupus erythematosus . . . . .	1	1	0
4	Infectious renal disease	6		
	Pyelonephritis . . . . .	3	0	3
	Acute necrotizing pyelonephritis . . . . .	1	0	1
	Acute suppurative nephritis . . . . .	1	1	0
	Hydronephrosis and pyelitis . . . . .	1	0	1
5	Anoxia	2		
	Lower nephron nephrosis . . . . .	2	0	2
6	Other disease	2		
	Congenital hypoplasia . . . . .	1	1	0
	Renal cyst . . . . .	1	0	1
Total		29	16	13



**Diagram 1.** Wedge section of the normal kidney showing the anatomy of the renal artery and its branches.

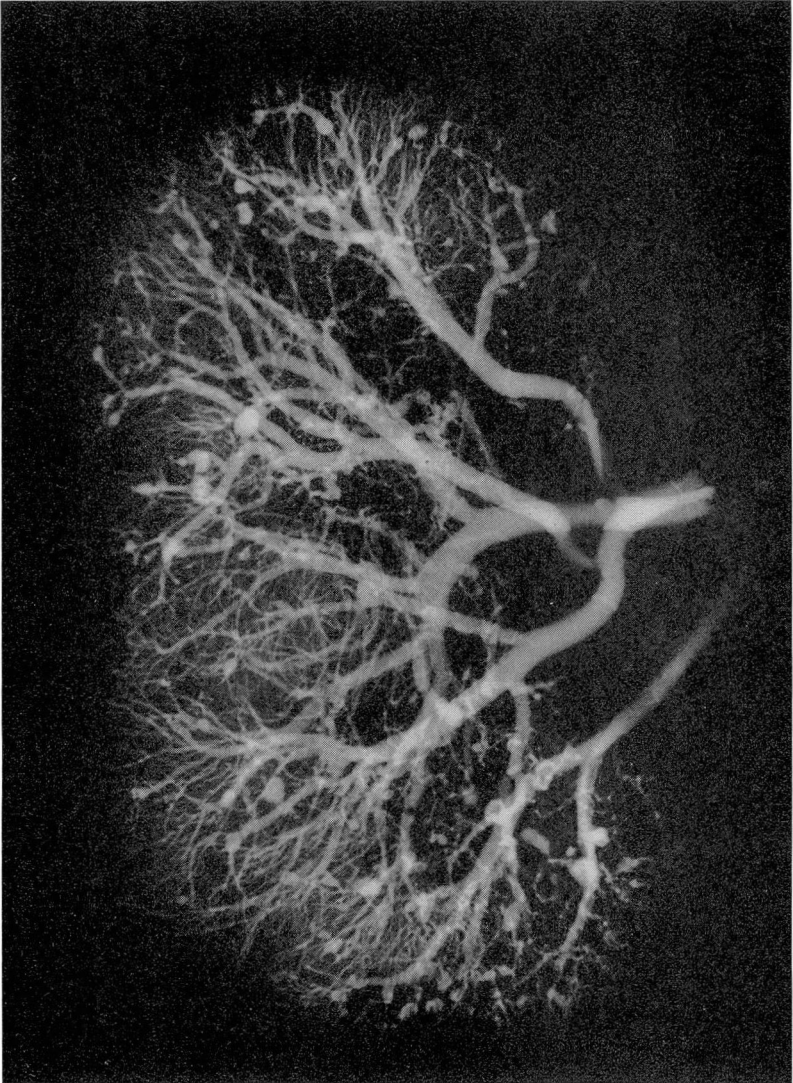
*Arterial system in pathologic kidneys from normotensive patients.* Two of the 10 patients having vascular disease (Group 2, Table 1) were normotensive. One had polyarteritis nodosa and the other had a calcified congenital aneurysm of



**Fig. 1.** Angiogram of kidney at necropsy, from a 28-year-old normotensive patient who died after craniotomy. The arterial pattern is normal: the cortical arterioles (interlobular arteries) are well filled and extend to the periphery of the cortex; the interlobar arteries are uniform in distribution and luminal size.



the renal artery. The arterial pattern in the kidney from the patient with polyarteritis nodosa was notable because it was the only one in this series which indicated a pathognomonic abnormality of the small vessels (Fig. 2). The filling of the arterial tree was complete, but numerous small saclike outpouchings extended from the vessels. These outpouchings, which represented micro-

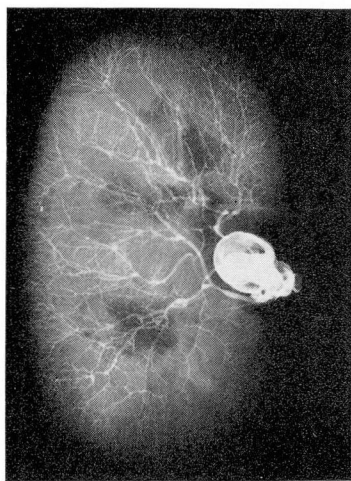


**Fig. 2.** Angiogram of kidney at necropsy, from a 57-year-old normotensive patient who had polyarteritis nodosa and who died from perforation of the ileum as a result of infarction. There is normal filling of the cortical arterioles. The significant finding is the multiple, small, saclike out-pouchings of the medium- and small-sized arteries which represent aneurysms.

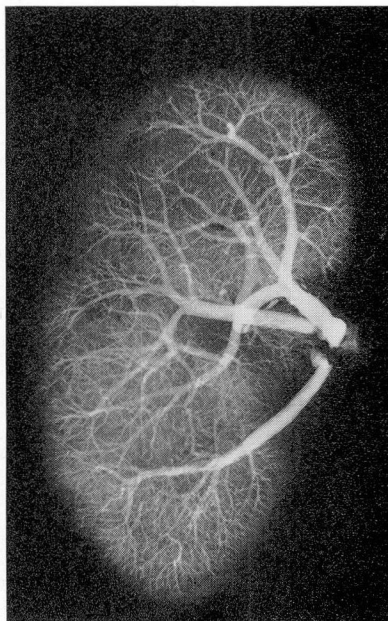
aneurysms, had resulted from focal necrosis of the arterial walls. Although these aneurysmal abnormalities of polyarteritis nodosa long have been recognized histopathologically, we believe that this is the first report of their recognition on roentgenograms. The renal roentgenogram of the patient with the aneurysm of the main renal artery showed a fairly normal arterial pattern distal to the aneurysm (Fig. 3).

Five of the six patients having infectious renal disease (Group 4, Table 1) were normotensive. Roentgenograms of the three kidneys from patients having pyelonephritis showed no striking abnormality and showed fairly normal filling of the terminal vessels; the diagnosis of pyelonephritis was incidental and none of the patients died of renal disease. The roentgenogram of the kidney from the patient having acute necrotizing pyelonephritis and that from the patient having hydronephrosis and pyelitis also gave no indication of arterial abnormality in so far as the injection pattern was concerned.

Both of the patients having lower nephron nephrosis (Group 5, Table 1) were normotensive, and the renal angiograms of both patients showed fairly normal filling of the terminal vessels (Fig. 4).



**Fig. 3.** Angiogram of excised kidney from a 57-year-old patient having aneurysm of the main renal artery. Preoperatively, the blood pressure was 175/80 mm. Hg and the blood-urea nitrogen content was 21 mg. per 100 ml. The aneurysm is well outlined by the injected material, and the cortical arterioles are well filled. There was no pathologic evidence of nephrosclerosis.



**Fig. 4.** Angiogram of kidney at necropsy, from a 66-year-old patient having early lower nephron nephrosis following pneumonectomy for carcinoma of the lung. The blood pressure had been 130/68 mm. Hg and the blood-urea nitrogen content 21 mg. per 100 ml. There is a normal arterial pattern similar to that shown in Figure 1.



One of the two patients in Group 6 (Table 1) was normotensive. The pathologic diagnosis was a renal cyst. A roentgenogram of the kidney from this patient showed a normal arterial pattern.

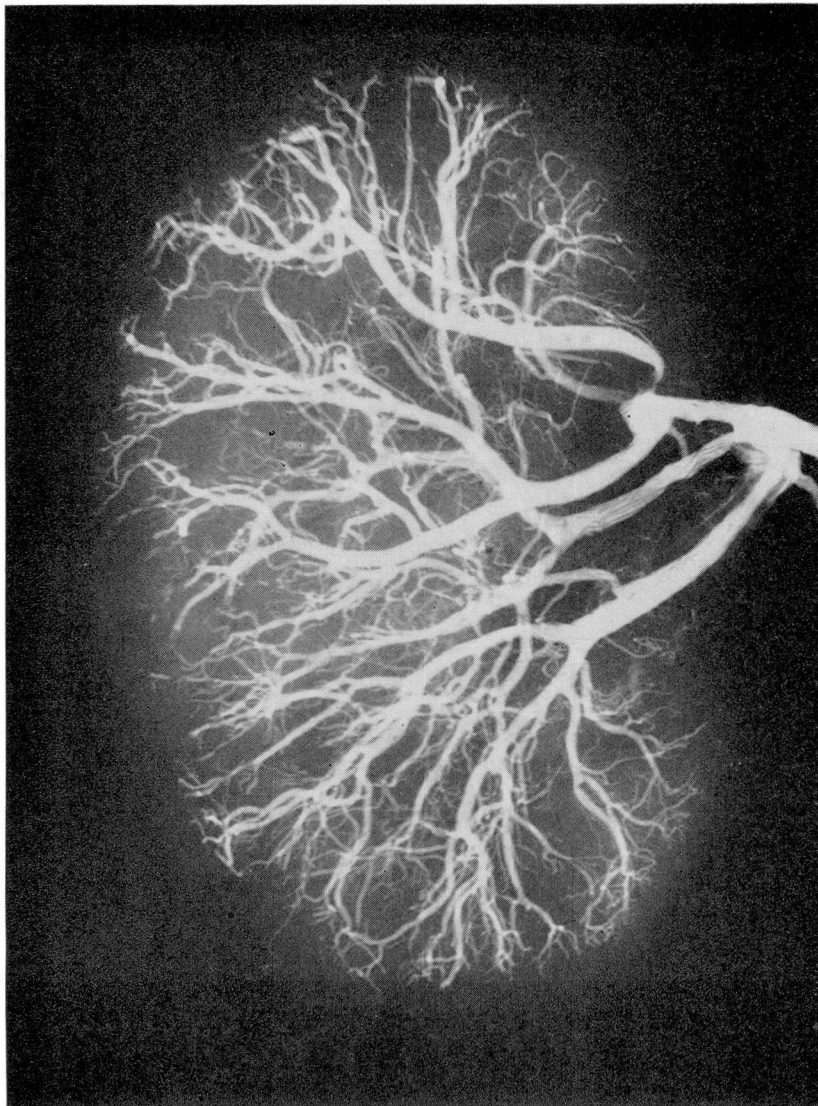
*Arterial system in pathologic kidneys from hypertensive patients.* Patients were considered hypertensive who had elevation of systolic and diastolic blood pressure and who showed pathologically demonstrable effects of hypertension. In contrast to the normal arterial pattern observed roentgenographically in the kidneys from all 13 normotensive patients, an abnormal pattern—diminution or absence of filling of the interlobular arteries—was observed roentgenographically in the kidneys from all 16 hypertensive patients.

Eight of the 10 patients having vascular disease (Group 2, Table 1) were hypertensive. The pathologic diagnosis of the condition of the kidney from each of these eight patients was arteriolar nephrosclerosis. In all eight, the renal angiograms after injection of the barium-latex suspension showed diminution or absence of filling of the interlobular arteries (cortical arterioles), indicating the pathologic abnormality of intimal thickening and resultant reduction in luminal size (Fig. 5).

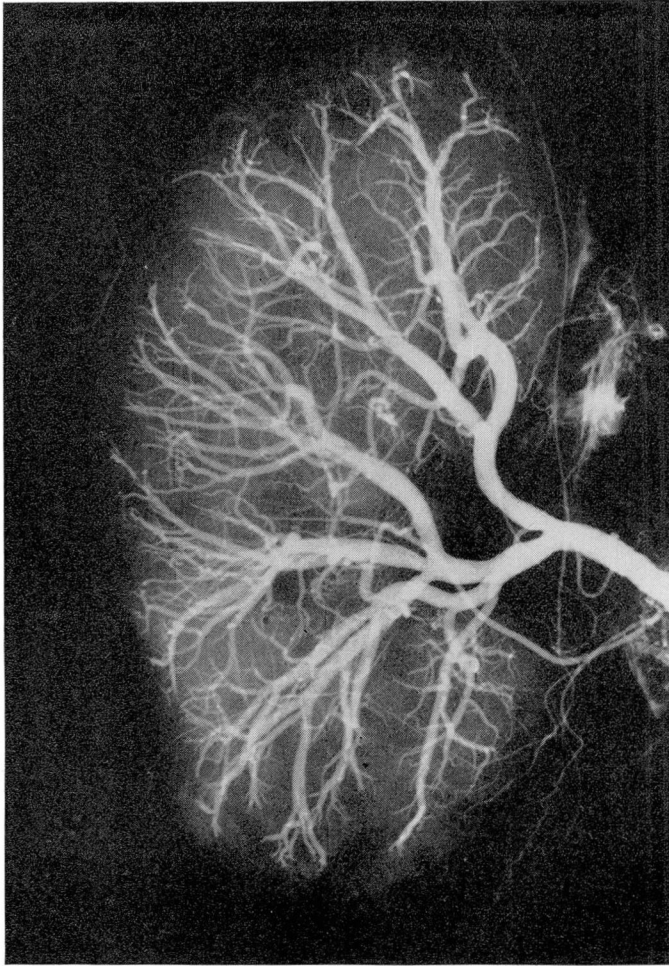
All six of the patients having glomerular disease (Group 3, Table 1) were hypertensive. The arterial pattern of the kidneys from the four patients having chronic glomerulonephritis was similar to that of the patients having arteriolar nephrosclerosis. The striking roentgen feature was the diminution or absence of filling of the interlobular arteries (Fig. 6). The more advanced changes of glomerulonephritis also were reflected in the arterial pattern by changes in the interlobar arteries (Fig. 7). These changes, similar to those observed in the later stages of nephrosclerosis, consisted of irregularity of luminal size. The histopathologic changes in the interlobar arteries were those of nephrosclerosis, which usually is associated with advanced glomerulonephritis. The roentgen arterial patterns of the kidneys from the patient having intercapillary glomerulosclerosis and from the patient having lupus erythematosus showed diminution or absence of filling of the interlobular arteries.

One of the six patients having infectious renal disease (Group 4, Table 1) was hypertensive. The pathologic diagnosis of the kidney from that patient was acute suppurative nephritis. The roentgen arterial pattern of this kidney (Fig. 8) was essentially the same as that in the nephrosclerotic and glomerulonephritic kidneys, and involved diminution or absence of filling of the interlobular arteries.

One patient in Group 6 (Table 1) was hypertensive. The pathologic diagnosis was congenital hypoplasia. The term "congenital hypoplasia" refers to a structurally normal but small kidney and is distinct from the atrophic pyelonephritic kidney. The roentgenogram of the kidney from this patient showed a small parenchymal mass and an arterial pattern similar to that seen in the kidneys from other hypertensive patients. Arteriolar nephrosclerosis was present.



**Fig. 5.** Angiogram of kidney at necropsy, from a 53-year-old patient who had arteriolar nephrosclerosis and who died of cerebral hemorrhage. The blood pressure had been 266/152 mm. Hg and the blood-urea nitrogen content 102 mg. per 100 ml. There is pronounced diminution in the filling of the cortical arterioles (compare with Figure 1). Pathologically, there were marked intimal thickening and reduction in the luminal size of small arteries and arterioles.



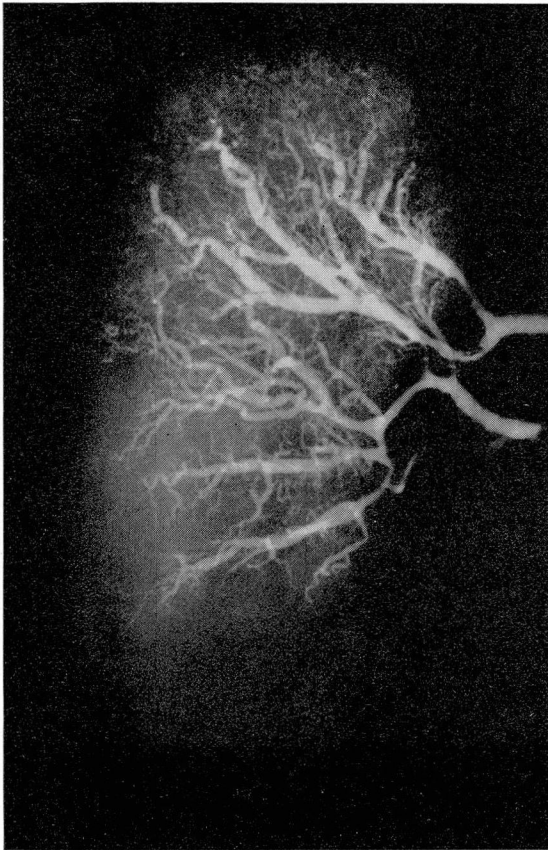
**Fig. 6.** Angiogram of kidney at necropsy, from a 60-year-old patient who died of chronic glomerulonephritis. The blood pressure had been 210/100 mm. Hg and the blood-urea nitrogen content 158 mg. per 100 ml. The arterial pattern is similar to that shown in Figure 5, and correlated with the pathologic findings of intimal thickening and luminal narrowing.

#### Comment

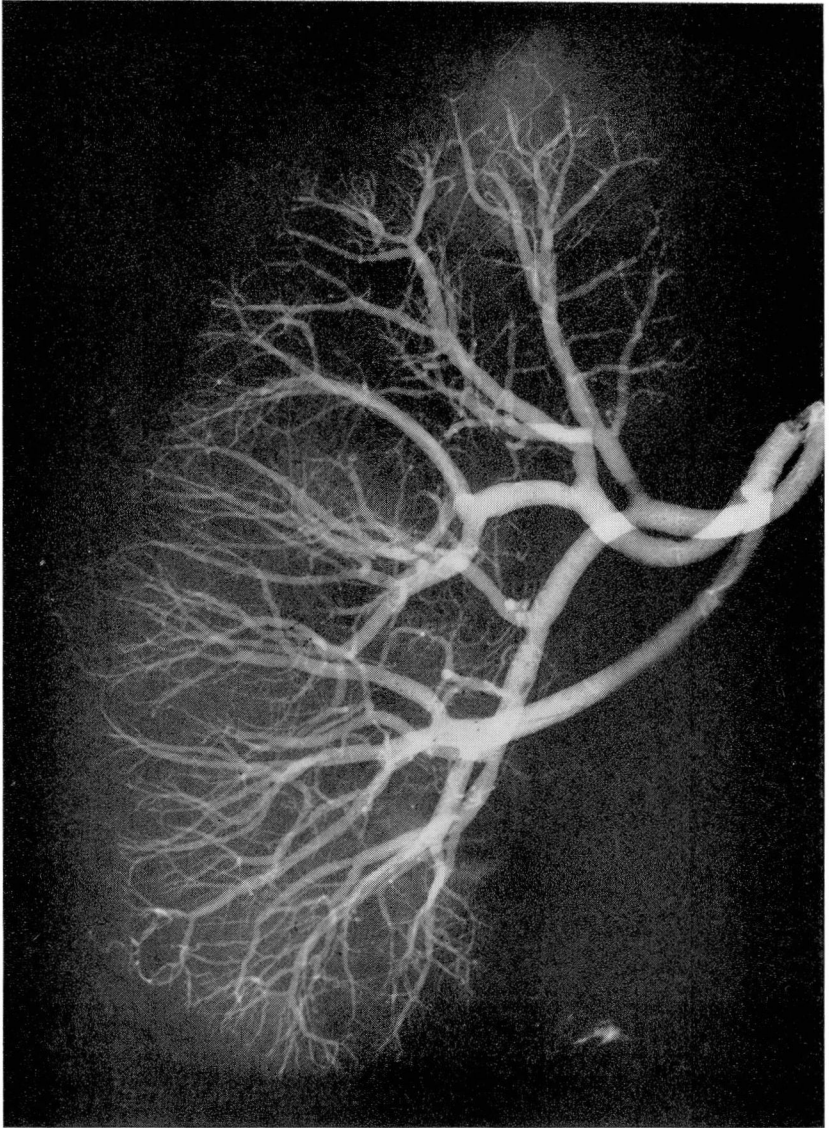
The roentgenograms of the kidneys from the 16 hypertensive patients showed a characteristic abnormality after barium-latex suspension had been injected into the kidneys—diminution or absence of filling of the terminal arteries. None of the roentgenograms of the 13 normotensive patients showed that abnormality. In the renal angiograms of the patients having advanced vascular disease associated with hypertension, irregularities also were observed



in the luminal caliber of the medium-sized vessels. The pathologic findings confirmed these angiographically observed abnormalities and indicated definite reduction in luminal size of the cortical arterioles. This pattern of arteriolar nonfilling in the cortical region of the kidneys from patients with hypertension is strikingly similar to the arteriolar pattern observed in animals having renal cortical ischemia under various experimental conditions including induced hypertension. In this study, the angiographic findings in kidneys from hypertensive patients indicate a reduction in luminal size and, by inference, the presence of cortical ischemia.



**Fig. 7.** Angiogram of kidney at necropsy, from a 60-year-old patient who died of advanced chronic glomerulonephritis. The blood pressure had been 170/90 mm. Hg and the blood-urea nitrogen content 192 mg. per 100 ml. There are extreme variation in luminal size of the medium-sized vessels and scant filling of the cortical arterioles which are irregular in size and distribution. (One branch of the renal artery was not injected.) The vessels are similar to those shown in Figure 6, and in addition there were arteriosclerotic changes in the large vessels.



**Fig. 8.** Angiogram of a kidney at necropsy, from a 50-year-old patient having acute suppurative nephritis. The blood pressure had been 240/140 mm. Hg and the blood-urea nitrogen content 28 mg. per 100 ml. There is absence of filling of the cortical arterioles. Pathologic changes of arteriolar nephrosclerosis with luminal narrowing were superimposed on the suppurative nephritis.

The arterial changes in these kidneys are not always of sufficient magnitude to be demonstrable by renal aortography. However, with modification in technique, particularly by serial angiography it is sometimes possible to obtain good visualization. Thus, renal angiography may aid in the diagnosis of some of the renal diseases that manifest themselves by changes in the small renal arteries.

### Summary

The arterial patterns of kidneys removed from 29 patients, 16 of whom were hypertensive and 13 of whom were normotensive, were demonstrated roentgenographically after injection of a barium-latex suspension. The arterial patterns of all of the kidneys from hypertensive patients exhibited a characteristic abnormality—diminution or absence of filling of the interlobular arteries (cortical arterioles)—which is strikingly similar to that observed in experimental animals with renal ischemia. That abnormality was not evident in any of the renal angiograms from normotensive patients.

The arterial pattern of the kidney from a patient having polyarteritis nodosa without hypertension showed multiple saclike outpouchings that we believe may be pathognomonic of this disease.

The clinical application of these findings to present-day renal angiography is sometimes limited by the inadequate visualization of these small arteries. However, when they can be visualized, the appreciation of the arterial changes may be useful in the diagnosis of renal diseases particularly those associated with hypertension.

### References

1. Trueta, J., and others: *Studies on Renal Circulation*. Springfield, Illinois: Charles C Thomas, 1947, pp. 187.
2. Daniel, P. M.; Peabody, C. N., and Prichard, M. M. L.: Observations on circulation through cortex and medulla of kidney. *Quart. J. Exper. Physiol.* **36**: 199-203, Oct. 1951.
3. Daniel, P. M.; Peabody, C. N., and Prichard, M. M. L.: Cortical ischaemia of kidney with maintained blood flow through medulla. *Quart. J. Exper. Physiol.* **37**: 11-18, Feb. 1952.
4. Daniel, P. M.; Prichard, M. M. L., and Ward-McQuaid, J. N.: Renal circulation in experimental hypertension: angiographic and morphological studies in rabbit. *Brit. J. Surg.* **42**: 81-95, July 1954.
5. Daniel, P. M.; Prichard, M. M. L., and Ward-McQuaid, J. N.: Angiographic study of renal circulation in experimental hypertension in dog. *Brit. J. Surg.* **42**: 212-216, Aug. 1954.