

# COBALT-60\* TELETHERAPY FOR PALLIATION OF CARCINOMA OF THE THORACIC ESOPHAGUS

THOMAS F. MEANEY, M.D.,† and ROBERT A. HAYS, M.D.

Department of Radiology

**C**ARCINOMA OF THE ESOPHAGUS presents a distressing problem in management. Despite the improvement in surgical and radiologic technics, only 2 to 3 per cent of patients having this disease survive for five years after the diagnosis. Since most cases are diagnosed only after esophageal obstruction has developed and the tumor has spread to involve regional or distant lymph nodes, the primary objective of treatment usually is palliative—relief of the esophageal obstruction.

Surgical resection or a bypassing procedure frequently has been performed for the relief of obstruction even when the disease is uncontrollable and despite a significant operative mortality in patients in the older age group.<sup>1</sup> The objective of treatment is to give the patients the satisfaction of being able to swallow during the remaining months of life. Without treatment these patients eventually may not be able to swallow even saliva. Other procedures have been employed with the hope of palliation—such as bougienage which temporarily dilates the obstruction but is painful and exposes the patient to the risk of perforation, and gastrostomy which permits nourishment of the patient but denies him the pleasure of eating—but they have been abandoned in most medical centers because of unsatisfactory results.

For the most part the results of palliative roentgen therapy heretofore have been disappointing. The inability to relieve the dysphagia may be attributable to many factors, physiologic, pathologic, and physical. The physiologic factors include the advanced age (average age, 62 years) and the poor nutritional status of the patient when he first is seen (average loss of weight since onset of symptoms, 26 pounds). The pathologic factor is the lack of consistent radiosensitivity of the tumor. Lesions involving the lower end of the esophagus frequently are adenocarcinomas that are inconstant in their response to irradiation. Lesions that involve only a short segment of the esophagus usually contain a considerable amount of fibrosis and respond poorly to irradiation; whereas, superficial spreading lesions that involve longer segments of the esophagus respond much better to irradiation.<sup>2</sup>

The physical factors that have hindered the effectiveness of irradiation of esophageal carcinomas include: depth of the lesion which may preclude an adequate dose for control of the tumor; secondary dermatologic and constitutional reactions that were not justified or desired in view of the expected poor result.

---

\*The radioactive material used in this study was supplied on authorization of the Atomic Energy Commission, Oak Ridge, Tennessee.

†Fellow in the Department of Radiology.

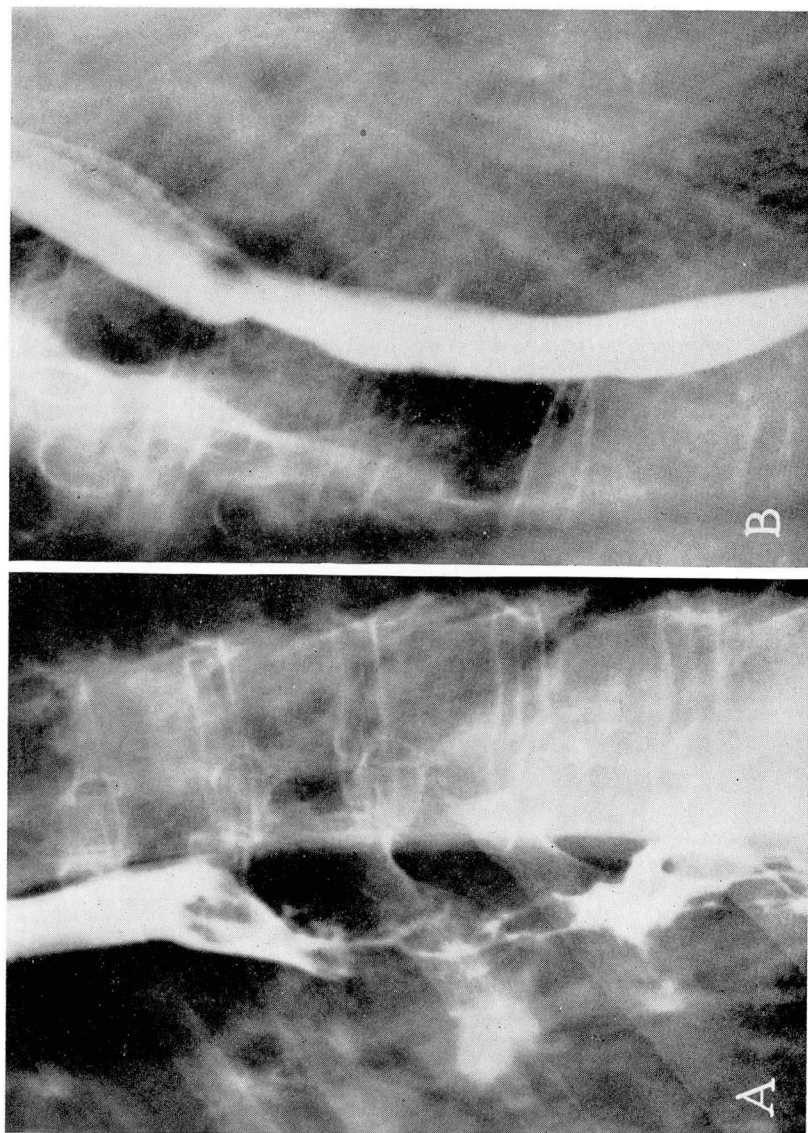
Supervoltage irradiation has immeasurably aided the radiotherapist in delivering a more nearly cancerocidal dose to deeply lying tumors. In comparison with other types of irradiation, supervoltage irradiation has a "skin-sparing" effect and better dosage levels at the tumor site and causes fewer systemic reactions because of the smaller volume of irradiated tissue. The cobalt-60 teletherapy unit emits gamma radiation equivalent in energy and physical distribution in the body to that produced by a 3,000,000-volt roentgen-ray machine.

In some medical centers the results of palliative roentgen therapy have been rewarding. Nielsen,<sup>3</sup> for example, has reported complete or nearly complete abolition of obstructive symptoms in four fifths of his patients who were adequately treated with rotational therapy in the medium voltage range (200 to 250 kv.). Autopsy examinations of the patients treated by irradiation have revealed, in many instances, that the primary tumor had been completely eradicated and that death had been caused by distant metastases.<sup>3,4</sup>

Cobalt-60 teletherapy has been employed at the Cleveland Clinic since September 1954, and a rotational device for this unit has been used since September 1955. Twelve patients having carcinoma of the thoracic esophagus have been treated. (Cases of carcinoma of the cervical esophagus are not included in this report because these lesions constitute another and special therapeutic problem.) All 12 of our patients were referred by the Department of Thoracic Surgery because of either one or both of the following limitations to surgical therapy: (1) the presence of extensive lesions, (2) the patients were poor-risk candidates for surgery.

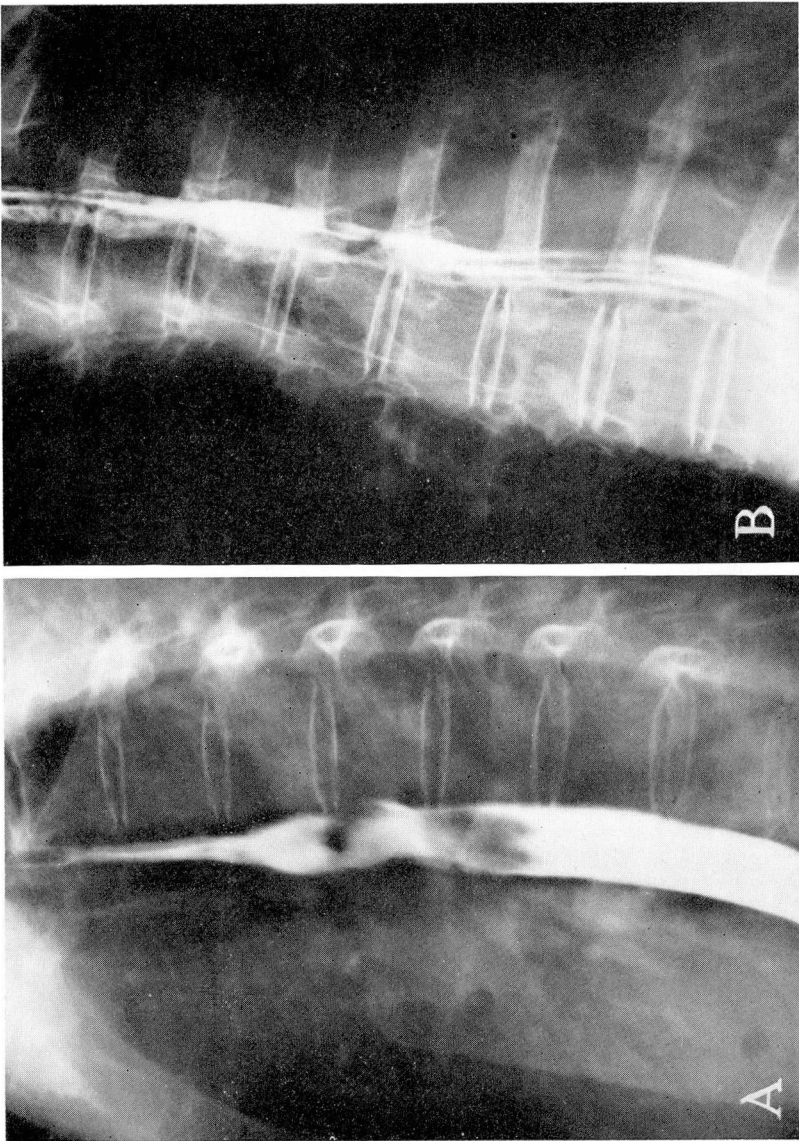
Postirradiation roentgen examination of the esophagus was made of only 7 of the 12 patients. Many of our patients reside at considerable distances from the Clinic and are unable to return for follow-up examinations; their follow-up care is being managed by their local physicians. In six of the seven patients whom we followed, palliation was gratifying, and in some of these a fairly normal mucosal pattern traversed the former site of the tumor. In the seventh patient of our series the disease progressed despite treatment.

Roentgen findings before and after cobalt-60 teletherapy in each of three patients are shown in Figures 1 through 3. The first patient (Fig. 1A) had an extensive squamous cell carcinoma of the mid-esophagus. Following cobalt-60 teletherapy the patient had no dysphagia and the esophagogram (Fig. 1B) appeared to be normal except for absence of peristalsis through the segment formerly occupied by the tumor. Nine months after treatment, the patient was asymptomatic. The second patient (Fig. 2A) had an undifferentiated carcinoma occupying the middle third of the esophagus, at the level of the aortic arch. Prior to treatment, the patient was unable to swallow solids. After treatment, dysphagia was relieved and the postirradiation roentgenogram showed no evidence of tumor (Fig. 2B). Nine months after completion of cobalt-60 teletherapy, biopsy showed only chronic esophagitis. No dysphagia was present when the patient was last examined, 17 months after the termination of the cobalt-60 teletherapy. The third patient had a squamous cell carcinoma that occupied the mid-third of the esophagus (Fig. 3A). After irradiation, the esophagogram (Fig. 3B) showed no evidence of tumor, although there was a constriction at the site formerly occupied by the neoplasm. The patient had no dysphagia at the time he was last examined, four months after termination of treatment.



**Fig. 1.** (A) Squamous cell carcinoma of the upper third of the esophagus. There is a long segment of esophagus that is diffusely infiltrated by tumor. (B) Postirradiation appearance of the esophagus; no demonstrable evidence of tumor.





**Fig. 2.** (A) Tumor mass, occupying the mid-third of the esophagus, which proved to be an undifferentiated carcinoma. (B) Postirradiation: fairly normal mucosal pattern traverses the former site of the tumor.

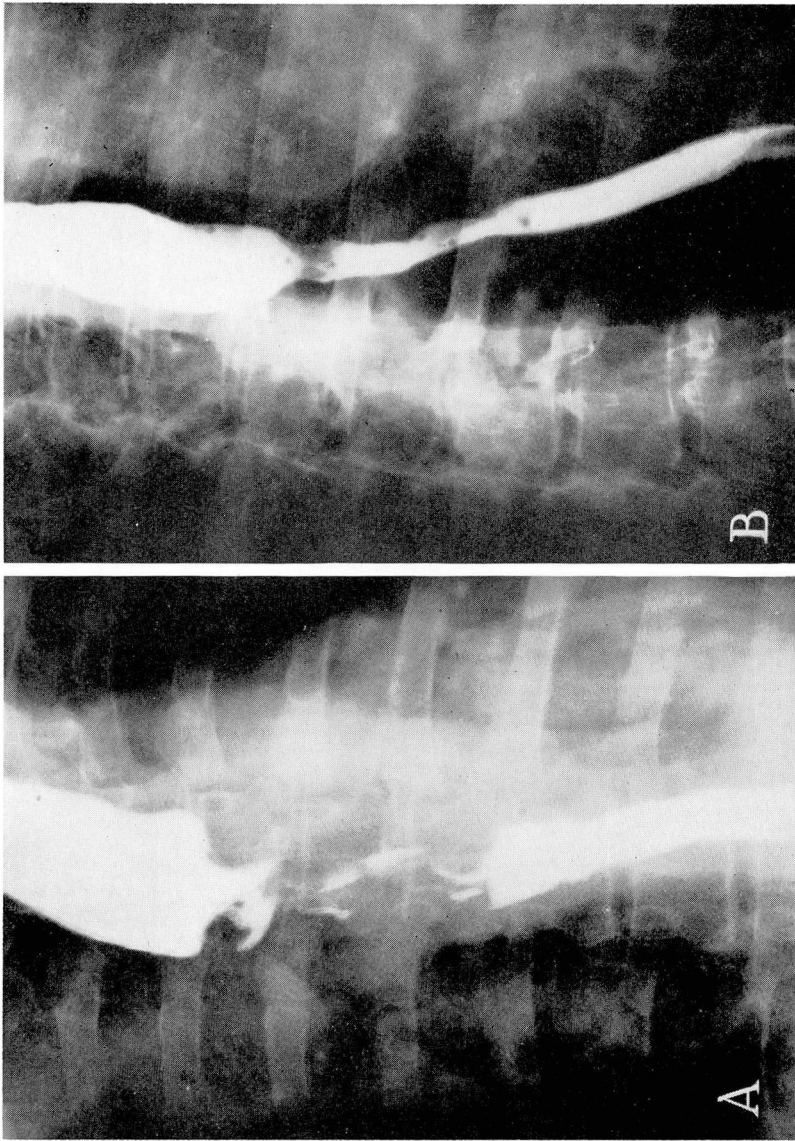


Fig. 3. (A) Diffusely infiltrating and constricting carcinoma of the mid-third of the esophagus. (B) Postirradiation: no demonstrable tumor, although a constriction is present at the former site of the tumor.

### Summary and Conclusions

Palliation is the primary objective in the treatment of most patients with carcinoma of the thoracic esophagus. Cobalt-60 teletherapy has given encouraging results according to the follow-up findings in six of seven patients with carcinoma of the thoracic esophagus: it has brought about regression of the obstructing tumors without mortality and without significant morbidity. It is doubtful that cobalt-60 teletherapy or supervoltage roentgen-ray treatment using rotational technics will significantly increase the five-year survival rate of patients with carcinoma of the thoracic esophagus, but cobalt-60 teletherapy should be seriously considered for those patients in whom definitive resection is unwarranted or is not feasible.

### References

1. Sweet, R. H.: Results of radical surgical extirpation in treatment of carcinoma of esophagus and cardia, with 5 year survival statistics. *Surg., Gynec. & Obst.* **94**: 46-52, Jan. 1952.
2. Buschke, F.: Surgical and radiological results in the treatment of esophageal carcinoma. *Am. J. Roentgenol.* **71**: 9-24, Jan. 1954.
3. Nielsen, J.: Clinical results with rotation therapy in cancer of esophagus; preliminary report based on 174 cases. *Acta radiol.* **26**: 361-389, 1945.
4. Standquist, M.: Transthoracic roentgen treatment of cancer of oesophagus. *Acta radiol.* **22**: 172-193, 1941.