

PROGRAM AND PROCEEDINGS OF THE SCIENTIFIC SESSIONS OF THE FIFTH ANNUAL FELLOWSHIP REUNION OF THE FRANK E. BUNTS EDUCATIONAL INSTITUTE

September 9 and 10, 1955

Friday, September 9

— ABSTRACTS —

Morning Session

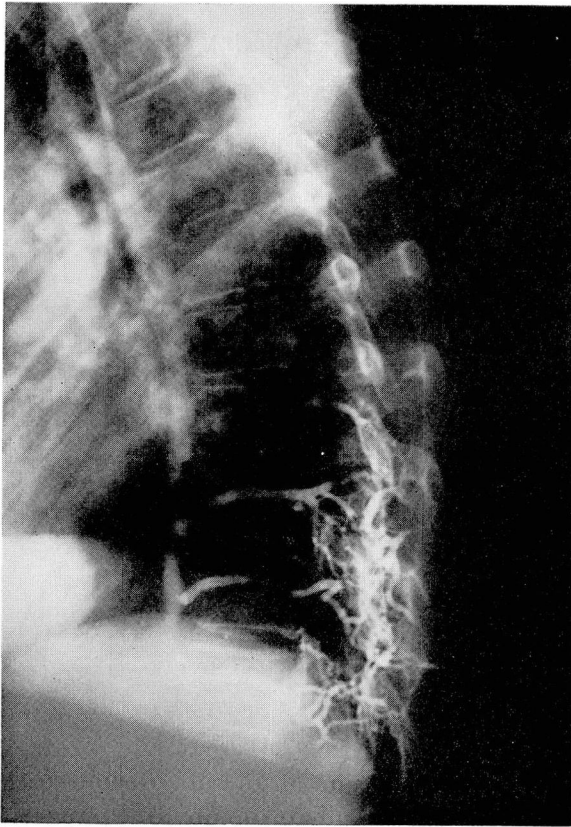
F. A. LeFevre, M.D., *Presiding*

1. INTRA-OSSEOUS VENOGRAPHY. Robert Schobinger von Schowingen, M.D., Buffalo, New York.

Intra-osseous venography is a new and simple technic that renders visible venous pathways that have partially or completely escaped visualization by other means. The technic of intra-osseous venography is as follows: After sedation of the patient with Demerol hydrochloride and Seconal sodium, a bone marrow aspiration needle is introduced, under local anesthesia, into the medullary cavity of the selected bone. Correct positioning of the needle is verified by aspiration of bone marrow; then 10 to 15 cc. of 50 to 70 per cent Urokon sodium is injected under constant moderate pressure. During injection of the last 3 or 4 cc., the roentgenograms are taken. No untoward effects were noted, and none should be expected if the necessary precautions against idiosyncrasies to the contrast medium or local anesthetic agent are observed.

Intra-osseous venography was performed in order to study: the changes affecting the azygos veins in the presence of mediastinal or pulmonary tumors; the vertebral plexi in normal and in pathologic conditions; the possibility of demonstrating isolated bony metastases much earlier than is possible by conventional methods; and the possibility of localizing pelvic tumors more adequately.

The area of visualization by intra-osseous venography is determined by the site of injection of the contrast medium (Fig.), as follows:



Intra-osseous venogram. Introduction of contrast medium into lower dorsal spinous process of normal patient. External vertebral plexus is moderately well demonstrated while the internal vertebral plexus is extremely well visualized over at least three vertebral spaces. From this latter plexus, the medium is drained into the azygos vein through several intercostal veins.

Site of injection and positioning of patient	Area of visualization
Ninth or tenth rib in the right midaxillary line, with the patient in supine position (medium passes through corresponding intercostal veins)	Azygos vein
Injection similar to the above, but in the left midaxillary line	Hemiazygos vein
Spinous process of D-11 or D-12, with the patient in a straight lateral position (right side down if pathologic condition is on right side, or vice versa)	Azygos system

FIFTH FELLOWSHIP REUNION

Any dorsal or lumbar spinous processes

External and internal vertebral plexi in area corresponding to site of injection

Protuberances of peripheral bones

Superficial and deep venous circulation of that extremity

Iliac crest, greater trochanter or pubic bone
(simultaneous bilateral injections provide best results)

Pelvic venous system

The following conclusions are based on the review of some 150 injections. (1) In patients having certain types of mediastinal and pulmonary tumors, obstruction of the azygos vein can be demonstrated. (2) Malignancies involving the spinal cord and possibly the vertebral bodies may produce an obstruction to the flow of contrast medium within the internal vertebral plexus at the level of the lesion. The medium is deviated distally, with resultant filling of the inferior vena cava, ascending lumbar veins, or azygos vein at a lower level. (3) Localized malignant processes of bone may cause an obstruction of the regional veins, interruption of the intramedullary diffusion of contrast medium, and the development of collateral circulation.

The great potentialities, the simplicity of technic, and the relative safety of intrasosseous venography certainly invite further investigative work.

* * *

2. AN UNUSUAL CASE OF PERIARTERITIS NODOSA. Salvatore R. La Tona, M.D., Niagara Falls, New York.

The multiplicity of the signs and symptoms of periarteritis nodosa is a constant challenge to the diagnostic acumen of the physician. The case to be reported illustrates this challenge and is unusual in that the patient had nearly all of the protean manifestations of periarteritis nodosa and that, in spite of severe recurrences, he survives five years after the onset.

Periarteritis nodosa is described as a systemic disease affecting medium-sized and small arteries. Some (Zeek, P. M.: *Am. J. Path.* **22**: 777, 1952) consider it to be a syndrome of multiple etiologies and go so far as to delineate distinct etiologic subgroups. Although I, among others, agree with this concept, in practice overlapping symptomatology makes it difficult to distinguish these subgroups—as in the case to be described.

The patient is now 47 years old. Hemoptysis in June 1951 led to segmental lobectomy with removal of a lung cyst. However, a month later he developed muscle and joint pains with swelling of one joint, and subsequently purpura over both legs. Diagnoses of rheumatoid arthritis and thrombocytopenic purpura were suggested. These symptoms together with hemoptysis and hematuria were present in February of 1952, at which time the provisional diagnosis of periarteritis nodosa was established by biopsy. Since then, he has had recurrence of pains and purpura, left orchitis superimposed on testicular

hemorrhage, pneumonitis, transitory hypertension, peripheral neuritis with foot drop and laryngeal palsy, cerebral thrombosis with hemiplegia, and semicoma of undetermined origin. He continues to have foot drop, hoarseness, stiffness of the legs and recurrences of purpura and pain. His condition is deteriorating and he is becoming increasingly irritable.

At various times he had been mildly or severely anemic with normal or increased white blood cell counts and constant elevation of sedimentation rate. Platelet counts always have been normal. The urine has shown red blood cells and albumin on occasion. Chest roentgenograms have shown recurring cystlike areas, and electrocardiograms have shown slight myocardial changes. Biopsy of the gastrocnemius muscle showed typical vascular lesions with necrosis and leukocytic and eosinophilic infiltration and fibrin thrombi in skin and in muscle. No etiologic agent has been identified. However, he was given a sulfa drug at the time of operation in 1951.

Treatment has been supportive, with physiotherapy and courses of ACTH and cortisone, antacids and potassium chloride. At present he can still walk with a cane and a brace on the right foot.

* * *

3. SEIZURE STATES AND PREGNANCY. Cary Suter, M.D., Charlottesville, Virginia.

This study of the relationship of seizure states (convulsions) to pregnancy was suggested from a consideration of three general clinical observations: (1) Seizure states are predisposed by any condition that leads to retention by the body of an excess of sodium and water. During pregnancy and the premenstrual periods fluid retention often occurs, and in eclampsia abnormal retention of sodium and water reaches a peak. (2) The initial onset of the seizure states came during pregnancy, according to a number of patients. (3) Improved therapy for seizure states has made it possible for more women who are subject to this condition to marry and to undergo pregnancy with success.

Of a group of 1000 patients having seizure states who were seen under the Seizure Control Program in the State of Virginia, 107 had histories of pregnancy. The correlation between seizure states and the pregnancies is reported in the Table. Of the 20 patients in whom the seizures were definitely more severe during pregnancy, 14 had had seizures of the grand mal and 6 of the psychomotor types. Eight of the 17 patients whose seizure states had had their initial onsets during pregnancy and continued postpartum, had shown some clinical evidence of toxemia; 9 of these 17 patients had had grand mal seizures and 8 had had mainly psychomotor seizures. Of the eight patients with onset definitely related to eclampsia, six showed typical psychomotor seizures with temporal lobe electroencephalogram focus. From the findings in these 17 patients, it is evident that the prevention of severe toxemia of pregnancy will result also in the prevention of many seizure states.

The following principles govern the treatment of the woman with seizure states who becomes pregnant: (1) *Weight control.* Total gain in weight during pregnancy should not exceed 18 pounds, and sudden gain in weight should be avoided. Weight gain above

this limit should be counteracted by a strict low-sodium diet and, if necessary, diuretics or ion-exchange resins should be administered. To insure strict adherence to the above regimen and best results, the patient should be hospitalized. (2) *Drug therapy*. The anticonvulsant drugs must be administered regularly. If the patient cannot take the drugs orally because of nausea and vomiting or during labor, she should receive injections of sodium phenobarbital as a substitute. The administration of the anticonvulsant drugs or of phenobarbital is especially important just before, during, and immediately after delivery.

With careful medical supervision, most women with seizure states can experience a relatively normal pregnancy and delivery, without harm to mother or child.

Table. — *Correlation of seizure states and pregnancy*

Status of seizure state during pregnancy	No. of women
Not known	35
No change	28
Increased severity	20
Original onset	17
Increased incidence	7
TOTAL	107

* * *

4. DOES THE AORTIC HOMOGRAFT DEVELOP ARTERIOSCLEROSIS? An


Experimental Study*. Edwin R. Fisher, M.D., Pittsburgh, Pennsylvania.

Evidence has rapidly accumulated of the immediately beneficial effects of aortic transplants. Most of these transplants are used to restore luminal continuity at sites of arteriosclerotic aneurysm or thrombosis. Since arteriosclerosis may be a metabolic disease, it seemed pertinent to study the fate of fresh and of lyophilized aortic homografts in rabbits having a metabolic arteriosclerosis experimentally induced from a diet containing 2 per cent cholesterol. Previous experimental studies of the fate of aortic homografts have not been concerned with the effects of experimental arteriosclerosis, and there has not been as yet full clinical evaluation of the development of arteriosclerosis in aortic homografts in patients.

The data show that aortic homografts in cholesterol-fed rabbits are more vulnerable to atherosclerosis than the remainder of the host's aorta or of the aortas of cholesterol-fed control animals. The lesions observed within the grafts were histochemically and morphologically identical with those that developed in control sites and in control animals. Further, it was conspicuously evident that fresh homografts were more severely affected

*Accepted for publication in *SURGERY*.

than were those prepared by lyophilization. Some of the fresh homografts developed aneurysmal dilatation (Fig.) and, in several, luminal occlusion resulted from the presence of large atheromatous plaques.



Aorta from rabbit (2 per cent cholesterol in diet for 70 days) with fresh homograft revealing aneurysm containing arteriosclerotic plaque. Small plaques are noted in remainder of host's aorta.

It is uncertain whether experimental cholesterol arteriosclerosis in rabbits can be identified with clinical arteriosclerosis in patients, so that it is not certain that human aortic homografts will show susceptibility to arteriosclerosis which has been demonstrated in the rabbit. However, as human aortic homografts of long duration become available, the clinical significance of this study can be finally evaluated.

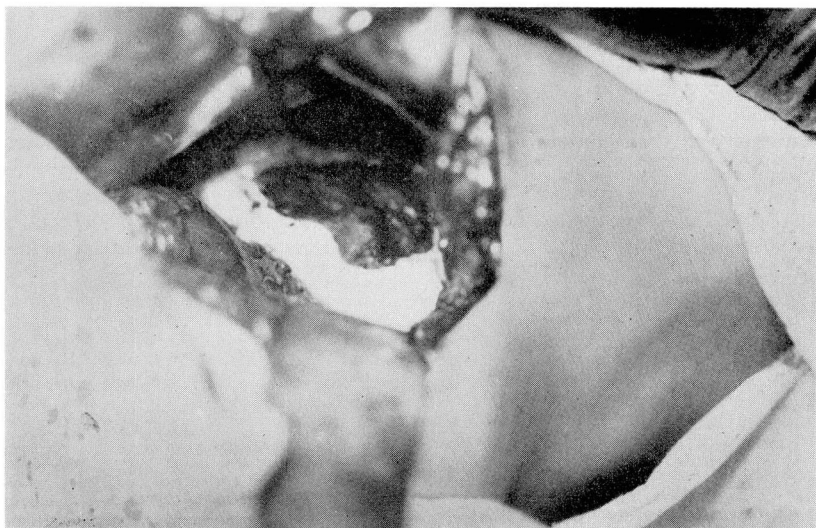
* * *

5. AN IMPROVED METHOD OF ADRENAL DENERVATION FOR ESSENTIAL HYPERTENSION*. Sherman A. Eger, M.D., The Jefferson Medical College, Philadelphia, Pennsylvania.

The purpose of this paper is to introduce an improved method of adrenal denervation and to describe its effects in patients having essential hypertension who were followed one to four years postoperatively. The method consists of surrounding each completely denervated adrenal with Oxycel cotton (oxidized cellulose) which, although absorbable, produces a cocoon-like barrier of fibrous tissue that is impenetrable to regenerating nerves and does not compromise the blood vessels. This method of denervation produces permanent changes in the adrenal—and thereby adds one important step to the method of denervation employed by the late Dr. George W. Crile whom some of us had the pleasure of knowing and the privilege of assisting in those operations about 25 years ago.

The operation is performed retroperitoneally through a five-inch incision parallel to and one inch below the twelfth rib. The lower edge of the adrenal appears when the kidney is rotated medially. All nerves are severed close to the adrenal under direct vision; those near to the central vein are severed last when all sides can be seen. The completely denervated adrenal is then encased in a one-inch-thick layer of Oxycel cotton (Fig.). A drain is inserted and the kidney is returned to its normal position. Operating time is about one hour. Patients are permitted out of bed on the second postoperative day, and are discharged from the hospital on the tenth postoperative day. An interval of four to six weeks is allowed before denervating the other adrenal, so that the first adrenal has had

*Accepted for publication in *POSTGRADUATE MEDICINE*.



The completely denervated left adrenal has been covered with Oxycel cotton except for its anterior surface that is covered last. Upper pole of kidney with attached fat also is shown.

time to recover from any operative trauma. Adrenal replacement therapy was indicated in only one case. There was one operative death resulting from congestive heart failure that had existed preoperatively.

Adrenal biopsies at the time of denervation routinely showed cells of the cortex to be swollen and their characteristic arrangement to be indistinct; likewise, the medulla contained numerous large cells and nerves. Two years later autopsy in one case showed those same adrenals to have cells of normal size, in normal arrangement, and to be devoid of nerves.

The best postoperative results were obtained in hypertensive patients whose blood pressures preoperatively fell to unquestionably normal levels during the profound sleep produced by the Sodium Amytal test. Therefore, it is the degree of neurogenic element present that is important regardless of the age of the patient or of the duration of the hypertension. The degree to which the blood pressure falls during profound sleep indicates the effect that denervation of the adrenals will have on the hypertension. All five of the hypertensive patients (one half of the total series) whose blood pressures became normal during this test obtained a similar but seemingly permanent response after operation. The operation is contraindicated when the amount of fall in blood pressure during the sleep test is not of sufficient degree to influence favorably the present state and future course of the hypertension. Operating for advanced hypertension after serious organic complications have developed does about as much good as operating for cancer after it has metastasized.

* * *

6. SURGICAL MANAGEMENT OF HYPERTENSION. J. W. Shirer, M.D., Pittsburgh, Pennsylvania.

* * *

7. NEEDLE BIOPSY OF THE LIVER. John J. Grady, M.D., Lakewood, Ohio.

Needle biopsy of the liver should be performed in patients having or suspected of having the following conditions: (1) hepatic disease in which the findings on hepatic function tests are inconclusive; (2) hepatic disease in which the etiology is obscure; (3) jaundice; (4) cirrhosis (biopsy performed to estimate the prognosis and occasionally to evaluate therapy); (5) systemic diseases that are known to involve the liver, in which the usual procedures have failed to establish the diagnosis. One of the prime values of needle biopsy of the liver is the demonstration of malignancy, either primary or metastatic.

On the basis of findings on needle biopsy of the liver, the diagnoses in 151 patients were as follows:

Diagnosis	No. of patients
Cirrhosis of the liver	51
Degenerative diseases	31
Metastatic carcinoma	23
Normal hepatic tissue	21
Chronic inflammatory diseases	18
Extrahepatic biliary obstruction	2
Miscellaneous	5
TOTAL	151

No fatalities and only two serious complications were attributable to the procedure. In patients with a palpable liver and no tendency to bleed, the anterior subcostal approach with the Vim-Silverman needle is recommended.

Needle biopsy of the liver need not be confined to use in teaching or to research institutions, but can and should be part of the clinical investigation of patients with hepatic disease in any private hospital.

* * *

8. THE THERAPEUTIC TRIAL FOR SUSPECTED AMEBIC DISEASE. Ferdinand J. Hruby, M.D., Cleveland, Ohio.

Within the past two decades amebic disease has been recognized as a problem that no longer has geographic limitations. The manifestations of this disease may be protean and the diagnosis difficult. Because of technical difficulties, attempts to isolate the amebic organism may be unsuccessful.

A presumptive clinical diagnosis of amebic disease and a therapeutic trial of anti-

amebic medication is justifiable in certain selected cases. A painstaking history with particular emphasis on foreign travel is essential. Amebic disease may produce symptoms mimicking functional gastrointestinal disease, and a diagnosis of psychoneurosis can mistakenly be made. Episodes of discomfort may occur weeks or months apart and are only partially relieved by antispasmodics, diet, and sedation. In addition, amebiasis may produce more conspicuous symptoms such as obscure fever, vague abdominal pain, diarrhea, and the signs and symptoms of hepatitis. Amebiasis, particularly amebic granulomas, may simulate certain surgical conditions. Ill-advised surgery has a high mortality rate in the presence of amebic infection.

The first patient had a diagnosis of psychoneurosis after she had been under observation in several institutions. She was a chronic complainer who had had episodal bouts of fatigue and vague intestinal symptoms. Twelve years previously, she had travelled extensively in South America. After fruitless clinical study, including warm stage stool examinations, she was placed on antiamebic treatment. Her response to this treatment was prompt and dramatic, and she has remained well for the past year since treatment.

The second case demonstrates how amebic disease may produce dramatic and severe symptoms. A 42-year-old dentist had suffered fever, aching, loss of weight, and marked asthenia for several weeks. All diagnostic studies were unrevealing and abdominal Hodgkin's disease was considered. On further inquiry, he stated he had been in the Navy and had served in the Philippines, but had had only rare episodes of mild diarrhea. He was placed on amebicidal treatment and the response was favorable following one course of antiamebic therapy. He has remained well for the past five years. In his case, the psychological trauma of a hopeless prognosis (Hodgkin's disease) and the possibility of a laparotomy were avoided.

The course of treatment in both of these cases consisted of five daily injections of emetine hydrochloride (1 grain) followed by carbarsone, $3\frac{3}{4}$ grains, twice daily for ten days. Recently, the use of emetine has been supplanted by other drugs including antibiotics and newer arsenical preparations (Fumagillin, Arsthinol, Carbomycin, etc.).

These two patients illustrate the fact that amebiasis may cause vague symptoms, that the disease may be difficult to diagnose, and that a course of antiamebic therapy can result in dramatic improvement. Despite negative laboratory findings, a therapeutic trial of antiamebic therapy is indicated in selected cases.

* * *

9. CHRONIC GRANULOMATOUS LESIONS OF THE RIGHT COLON SIMULATING MALIGNANCY. J. A. Lehman, M.D., Philadelphia, Pennsylvania.

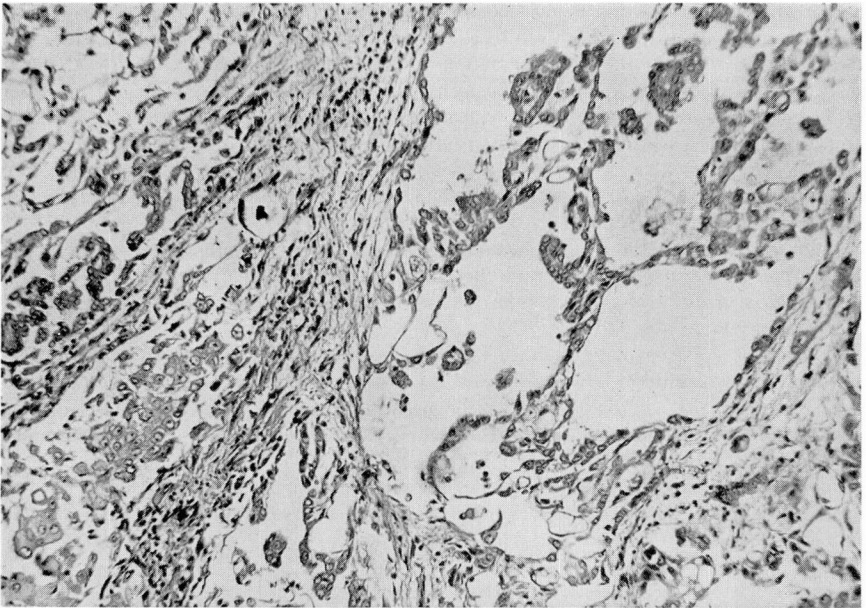
* * *

10. MESOTHELIOMA OF THE PERITONEUM. George W. Knabe, M.D., Dayton, Ohio.

Primary tumors of the mesothelium of the peritoneum are rare. They occur either as solitary growths or as disseminated nodules and plaques that characteristically involve the peritoneum superficially. Microscopically, these tumors often are similar to the proliferation of mesothelium in peritoneal inflammation, a similarity that aids in their identification. Sometimes they are so well differentiated that in biopsied material they

are mistaken for inflammatory processes. Localized and diffuse forms both of benign and of malignant types occur. The diffuse malignant growths always are fatal; they may have multiple sites of origin but it is more likely that they arise from peritoneal dissemination. Metastases usually are via lymphatics, although they rarely are more distant than to regional lymph nodes. The diffuse tumors often are accompanied by abundant mucoid ascitic fluid that contains hyaluronic acid.

The multipotentiality of the mesothelial cell accounts for great variations in microscopic appearance of primary peritoneal tumors. They can, however, be roughly grouped into five variants on the basis of histopathologic patterns: (1) *Tubular mesotheliomas*, (2) *Papillary mesotheliomas*, (3) *Fibrous mesotheliomas*, (4) *Undifferentiated mesotheliomas*, (5) *Mixed-type mesotheliomas* (Fig.).



Mixed-type mesothelioma, showing mesothelial-lined spaces together with nests of undifferentiated cells. Hematoxylin and eosin (X150).

Clinically, the benign peritoneal mesotheliomas produce only the signs and symptoms of an enlarging mass. Malignant forms occur in aged persons and usually cause vague gastrointestinal distress, abdominal swelling, and loss in weight; death occurs several months to a year after the onset of symptoms. The course resembles that of abdominal carcinomatosis. The diagnosis usually is made at autopsy, although the findings on biopsy at laparotomy or on cytologic examination of ascitic fluid may suggest the diagnosis. When the fluid is viscous, an attempt should be made to discover whether hyaluronic acid is present. In tissue specimens the character of the mucoid material should be studied by staining for mucin. The secretion produced by mesothelioma is of connective-tissue origin and does not react as does the epithelial mucin elaborated by adenocarcinoma. Localized mesotheliomas are adequately treated by wide excision, but in diffuse malignant forms the only treatment thus far shown to be of value is the intraperitoneal administration of radioactive colloidal gold.

* * *

**11. COMMON CAUSES OF PAINFUL SHOULDER. R. H. Jacques, M.D.,
Columbus, Ohio.**

* * *

**12. CHANGES IN THE ASPECT OF NEUROSURGERY OVER TWENTY-ONE
YEARS. W. B. Hamby, M.D., Buffalo, New York.**

* * *

Friday, September 9

— ABSTRACTS —

Afternoon Session

W. J. Engel, M.D., Presiding

**1. A NEW METHOD FOR HEPATIC RESECTION*. John R. Robinson, M.D. and
Harvey R. Butcher, Jr., M.D. (By Invitation), St. Louis, Missouri.**

Control of hemorrhage is the greatest problem associated with resection of large segments of the liver. The hepatic suture technic of Terrier and Auvray (Terrier, F., and Auvray, M.: *Rev. de chir.* **18**: 706, 1898) with certain important modifications is similar to the one herein advocated. The method essentially involves a "cobbler type" of stitch inserted with a special, long, blunt, flexible wire needle (Fig.).

This technic has been used successfully in four cases and has the following advantages:

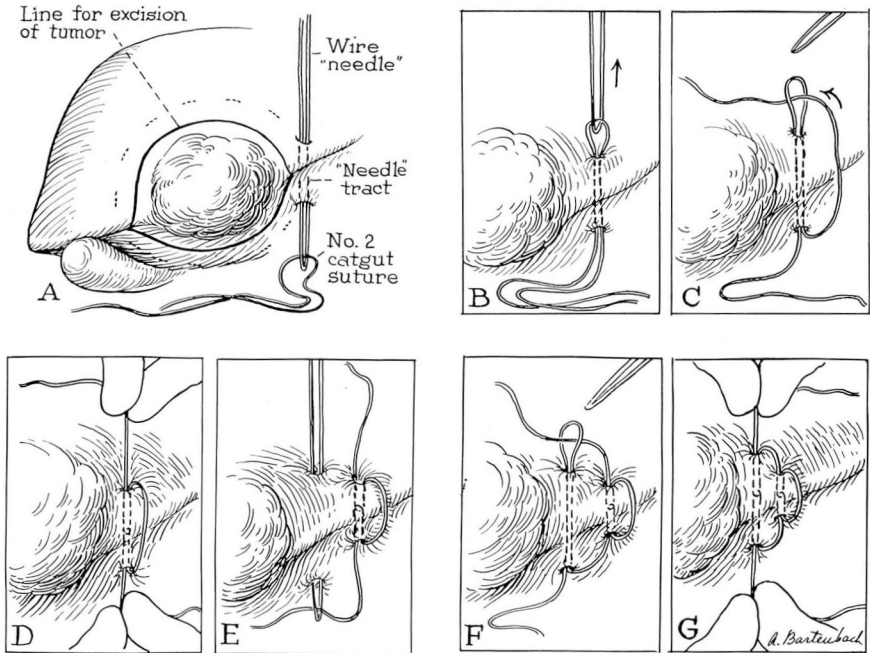
1. Hepatic vessels and large bile ducts are not punctured; the special needle readily passes through thick portions of hepatic parenchyma.

2. There is minimal danger of tearing the liver upon tightening this suture, because the pull is more equally distributed around the encompassed parenchyma.

3. No portion of the liver adjacent to the proposed line of resection escapes enclosure with this suture that is simple and can be rapidly placed.

4. There is minimal danger of hemorrhage and air embolism because the suture cannot slip, as it is continuous with the surrounding segments; therefore, large traumatic lacerations of the liver as well as tumors can be handled rapidly with minimal loss of blood.

**Accepted for publication in SURGERY.*



Technic

(A) A No. 16 silver wire, 20 inches long, is bent like a hairpin so that an open narrow loop is formed. This loop acts as the needle point, and is passed through hepatic parenchyma near (1 to 2 cm. proximal) to the line of hepatic resection. (B) The suture (No. 2 chromic catgut, full length) is passed through the "point" of the needle, and the needle is withdrawn back through the parenchyma so that a loop of catgut is pulled through the liver. (C) The free end of the suture is passed through the catgut loop previously drawn through the liver. (D) Both ends of the suture are drawn taut, allowing the interlocking junction to be drawn half way through the needle tract. (E, F, G) Tension is maintained on the previously placed suture while the above steps are repeated every 2 to 3 cm. until the portion of the liver to be resected has been completely encompassed. The liver is then transected 1 cm. parallel and adjacent to the suture line, and any small vessels that ooze on the cut surface are ligated.

* * *

2. THE NOBLE PLICATION OPERATION ON THE SMALL INTESTINE, FOR THE MANAGEMENT OF RECURRENT OBSTRUCTION FROM ADHESIONS. Robert P. Dutlinger, M.D., Harrisburg, Pennsylvania.

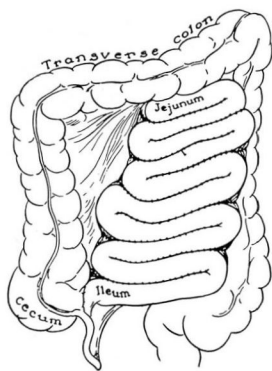
The management of recurrent obstruction from adhesions in the small intestine often presents a difficult and distressing problem. The majority of patients having these obstruc-

tions already have undergone a number of operations, and many have become psychoneurotic and addicted to drugs or to alcohol. However, if definite mechanical obstruction of the bowel is present, additional surgical treatment may be necessary.

The intraperitoneal instillation of substances such as mineral oil, papain, and amniotic fluid to prevent the formation of adhesions has not been successful. The usual procedure has been to divide the adhesions, thus freeing the kinked loops of bowel. Unfortunately, in many instances obstructing kinks have recurred, necessitating another similar operative procedure.

In 1937, Nobel (Noble, T. B., Jr.: *Am. J. Surg.* 35: 41-44, Jan. 1937) described an operation that he termed *plication of the small intestine*. He reported having employed the procedure successfully in the management of adhesions. He stressed the principle that adhesions should be 'controlled' in the sense that they be localized to a previously determined area. His observations were not challenged or confirmed until five years ago when surgeons began to report encouraging results from the procedure.

The operative technic consists of mobilizing the small intestine, releasing all adhesions and plicating parallel loops throughout its length (Fig.). This operation may be of considerable magnitude. The technic may also be applied in a limited fashion, i.e., to a limited segment of small intestine rather than to its entire length. The latter method usually is employed at the time of an initial operation, such as for an abscess with adherent loops of bowel in the immediate vicinity. The detailed technic of intestinal plication has been discussed at some length in the literature. In general, it is considered preferable to employ a continuous suture of catgut placed midway between the mesenteric and antimesenteric borders of adjacent loops, assuring an ample loop at each end without kinking.



Schematic drawing showing
Noble method of plication of small intestine.

Twelve operations in which the Noble plication was employed have been performed at the Harrisburg Hospital, with postoperative follow-up from two to three years. Six of the procedures were segmental in type, while six were complete plications for recurrent obstructions. The results in the latter group are excellent in four, fair in one, and poor in one. The results of the six segmental type of plications cannot as yet be adequately evaluated; however, no obstructive symptoms have developed in any of the patients to date.

The Noble plication operation merits further investigation as a method of treating chronic or recurrent obstruction of the small intestine in carefully selected cases. The segmental type of plication seems to be a valuable adjunct as a primary procedure in the prevention of obstruction of the small bowel in patients with severely damaged visceral peritoneal surfaces.

* * *

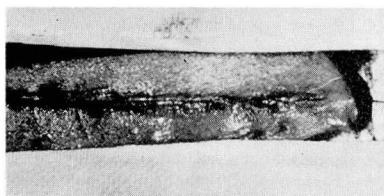
3. A NEW TYPE OF WOUND CLOSURE USEFUL IN PEDIATRIC SURGERY.

Houghton F. Elias, M.D., Beatrice, Nebraska.

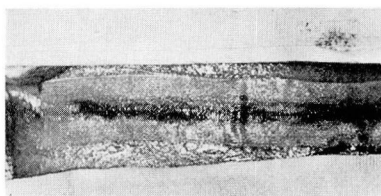
Recently a vinyl resin-base plastic material (Aeroplast) has been developed which is nontoxic (Choy, D. S. J., and Wendt, W. E.: U. S. Armed Forces M. J. 3: 1241-1255, Sept. 1952.), nonsensitizing, and nonallergenic (Simon, S. W., and Rinard, L. A.: J. Aviation Med. 24: 530-531, Dec. 1953.). This film is insoluble in body fluids, and its solvent evaporates in seconds after it has been applied. It has proved useful as a sterile protective covering for burns and wounds.

It was thought that this plastic material might be an ideal dressing for pediatric surgery because it is waterproof, it will stand the stress of repeated flexing, it is easily applied, and it is simple to remove. The strength of the film has been measurably increased by the incorporation of gauze mesh in its construction. Wound edges that previously have been approximated by a subcuticular suture can be held in place with this reinforced film, so that the subcuticular suture can be removed immediately after application of the dressing (much in the same fashion that a tailor's basting stitch is removed) while maintaining accurate wound approximation.

This procedure is excellent for maintaining apposition of the edges in a reasonably short incision. The dressing is convenient, gives accurate approximation, maintains sterility over an aseptic wound and obviates subsequent removal of skin sutures from a struggling child.



A. 'Basting' stitch being removed.



B. Completed closure.

* * *

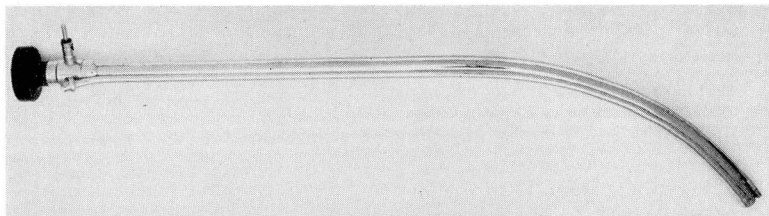
4. ADVANTAGES OF PIRIDOCAINE HYDROCHLORIDE (LUCaine) FOR SPINAL OR SADDLE BLOCK ANESTHESIA IN CERTAIN OPERATIONS. W. R. T. Metzner, M.D., San Antonio, Texas.

* * *

5. A NEW GASTROENTEROSCOPE. Charles A. Lamb, M.D., Boston, Mass.

This report concerns a new gastroenteroscope that I have designed for use during abdominal surgery when it is necessary to determine the point of bleeding, to view the duodenum and its entering ducts, or to determine whether multiple lesions are present

in the colon. The new instrument has an unusually wide field of visualization and is not difficult to use. It is 54 cm. long, 1.5 cm. in diameter, and is curved in the distal third of its length, so as to permit easy visualization of portions of the gastrointestinal tract at some distance from its insertion (Fig.). A series of 12 prisms within the scope reflects the image accurately to the eyepiece.



Photograph of the gastroenteroscope.

The gastroenteroscope can be inserted into the stomach through a gastrotomy in the pyloric area, from which location the instrument can be passed into the esophagus and, by being reversed in direction, into the duodenum. To visualize the entire mucosal surface of the colon, two colotomies are necessary: one at the hepatic flexure, the other just below the splenic flexure.

For two days prior to gastroenteroscopy the patient should be given a nonresidue diet so that the gastrointestinal tract will be as free as possible from solid matter, and a non-absorbable sulfonamide should be administered. Twenty-four hours before surgery I always prescribe a broad-spectrum antibiotic; this may not be necessary, but none of my patients ever has developed a contaminated wound that could be attributed to the gastroenteroscopy.

* * *

6. ESOPHAGITIS: Report of a Case Treated Surgically. Roy H. Thompson, M.D., Cleveland, Ohio.

A 65-year-old housewife was admitted to Woman's Hospital on August 8, 1953, because of complaints of heartburn, nausea, and progressively severe postprandial emesis for the preceding three months. The physical examination was essentially negative. Roentgenographic studies revealed a moderately dilated esophagus with esophagitis, cholecystitis, and cholelithiasis. After discharge from the hospital 15 days after admission, the referring surgeon performed several esophageal dilatations.

Three months after initial admission, the patient was readmitted because of dysphagia and emesis. Through a left thoracotomy, the diaphragm was opened and sutured loosely about the esophagus. She was discharged 25 days postoperatively.

Eleven months after initial admission the patient was readmitted to the hospital. In spite of continued dilatations, her symptoms had worsened and she steadily had lost weight. The thoracotomy was reopened and the junction of the esophagus and stomach

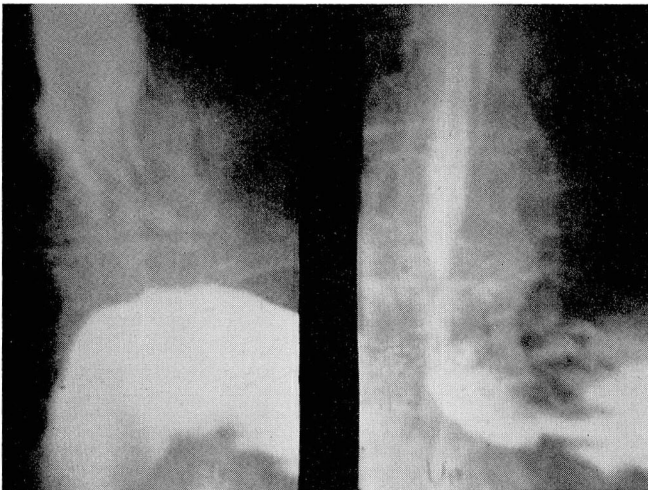
was resected. A new stoma was made in the cardia anteriorly, into which the esophagus was inserted with a long stump and invaginated. The diaphragm was loosely closed around the cardia that remained partly in the thorax.

The pathologic specimen was 4 cm. in length and 1.75 to 3 cm. in diameter. Histopathologic study showed chronic esophagitis and gastritis with stenosis of the esophageal lumen.

The patient's weight decreased to 80 pounds and esophageal dilatation was resumed under fluoroscopic control. Gradually the ability to swallow liquids was regained. The patient's diet progressively included increasingly solid foods. When therapy had reached a degree sufficient to allow the passage of a No. 45 F. olive-tipped bougie, the patient was discharged—approximately three months after admission.

The patient first noted heartburn, a symptom of regurgitation, three months prior to her initial hospitalization. Experimentally, Giuseffi, Grindlay, and Schmidt (Giuseffi, V. G., Jr., Grindlay, J. H., and Schmidt, H. W.: *Proc. Staff Meet., Mayo Clin.* **29**: 399, 1954) found that esophagitis developed in dogs approximately three months after the removal of the phrenic crura that controls canine regurgitation. Schmidt also reported a large series of cardiospasm patients, one third of whom had disease of the gall bladder (Schmidt, H. W.: *Proc. Staff Meet., Mayo Clin.* **29**: 153, 1954). Furthermore, the actions of the myenteric plexus of Auerbach and of the submucosal plexus of Meissner are correlated and account for the powerful circular muscles secondary to the inflammation in the wall of the lower esophagus in esophagitis. In the case of this report the first operation removed the effect of the diaphragm with no improvement. The second operation eliminated the normal gastric opening and removed the diseased area.

At follow-up examination two years postoperatively (Fig.), the new stoma functioned normally with no evidence of regurgitation in the upright and in the Trendelenburg positions. The patient had gained 55 pounds and had no complaints.



Roentgenograms after barium swallow, obtained two years postoperatively: (a) No regurgitation apparent (patient in 45-degree Trendelenburg position); (b) Patent stoma (patient in upright position).

This operation is not new and has been reported as attended with varying degrees of success.

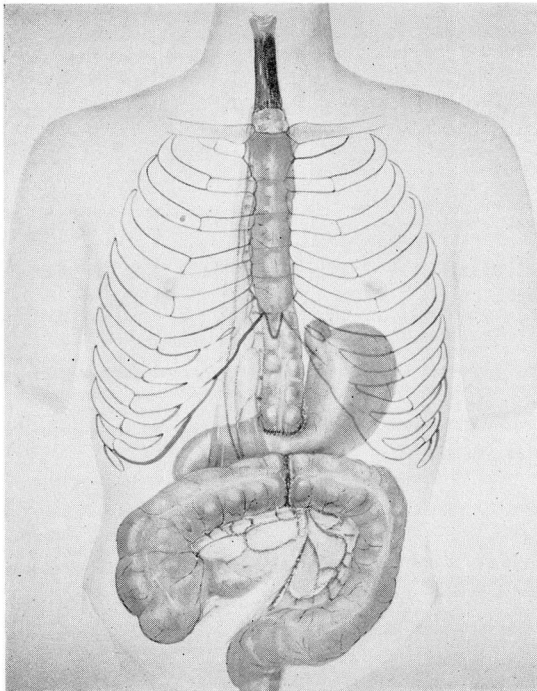
In conclusion, it may be said that the pinchcock action of diaphragm and the cardiac and inferior esophageal sphincters do not appear to be essential to prevent abnormal regurgitation.

* * *

7. ESOPHAGEAL RECONSTRUCTION UTILIZING THE TRANSVERSE COLON. William E. Neville, M.D., Cleveland, Ohio.

Recent interest in the utilization of the transverse colon in esophageal reconstruction has resulted from consideration of the three great advantages offered by this method: (1) excellent blood supply; (2) bowel length usually adequate to reach the neck in the case of the high esophageal resection; and (3) greater inherent resistance of the colon to peptic ulceration than that either of the jejunum or of the stomach, each of which has been used in esophageal reconstruction.

This report outlines my experience in utilizing the transverse colon for esophageal reconstruction after resection for carcinoma or tracheo-esophageal fistula (Fig.).



Schematic drawing showing the result of utilizing the transverse colon for esophageal reconstruction after operation for tracheo-esophageal fistula.

Two teams of surgeons and assistants have been employed for resection of an esophageal carcinoma above the aortic arch. The 'thoracic' team resects the esophageal lesion through a right thoracotomy, while the 'abdominal' team mobilizes the colon. Either the proximal or the distal end of the bowel is passed into the chest through an incision in the diaphragm anterior to the liver. The thoracic team performs the high esophageal anastomosis either anterior or posterior to the hilum, while simultaneously the abdominal team performs the colocolostomy and cologastrostomy. For esophageal lesions below the aortic arch, the entire operation can be performed through a left transthoracic transdiaphragmatic incision. We have performed this operation on nine patients with carcinoma, with satisfactory results to date.

Delayed reconstruction of the esophagus using the transverse colon has been performed on one child with tracheo-esophageal fistula. Immediately after ligation of the fistula, it was impossible primarily to anastomose the ends of the esophagus; therefore, the blind upper end of the esophagus was brought out into the neck, and the atretic lower end was resected. A feeding gastrostomy was performed through a separate abdominal incision. When the child was one year old, the transverse colon was interposed between the upper end of the esophagus and the stomach. In this instance, the colon was passed into the neck through an anterior mediastinal tunnel. One end was anastomosed to the esophagus, and the other to the distal end of the stomach. Except for requiring subsequent revision of the esophagocolostomy, the patient has progressed well. He eats in a normal manner and his weight has steadily increased.

* * *

8. INTERBODY SPINAL FUSIONS. J. R. Stacy, M.D., Oklahoma City, Oklahoma.

* * *

9. TRANSPLANTATION OF URETERS INTO AN ILEAL POUCH. James I. Farrell, M.D., and John E. Kearns, M.D., Evanston, Illinois.

Diversion of the urinary stream, after cystectomy for carcinoma or because of congenital anomaly, generally has been unsatisfactory. Various operations that have been devised to divert the urinary stream into the colon have had mortality rates up to 50 per cent, and the survivors often have had serious sequelae, including hyperchloremic acidosis, colon-ureteral reflux, renal damage, and stricture at the site of anastomosis.

Recently Hoeffner and Bricker reported good results after transplantation of ureters into isolated segments of ileum, without the late complications of urinary infection and acidosis. We have been favorably impressed with the principle of their procedure for several reasons: (1) the site of implantation remains free of infection; (2) there is no pressure exerted on the transplanted ureter to cause stasis; (3) there is no absorption of urinary waste products from the ileal pouch; (4) since no attempt is made to reconstruct a sphincter between the intestine and the ureter, there is little likelihood of stricture. We have used this procedure in six patients with carcinoma of the bladder. Short-term results have been good.

* * *

10. **LIPOMATOUS REPLACEMENT OF THE KIDNEY:** Report of Two Cases.

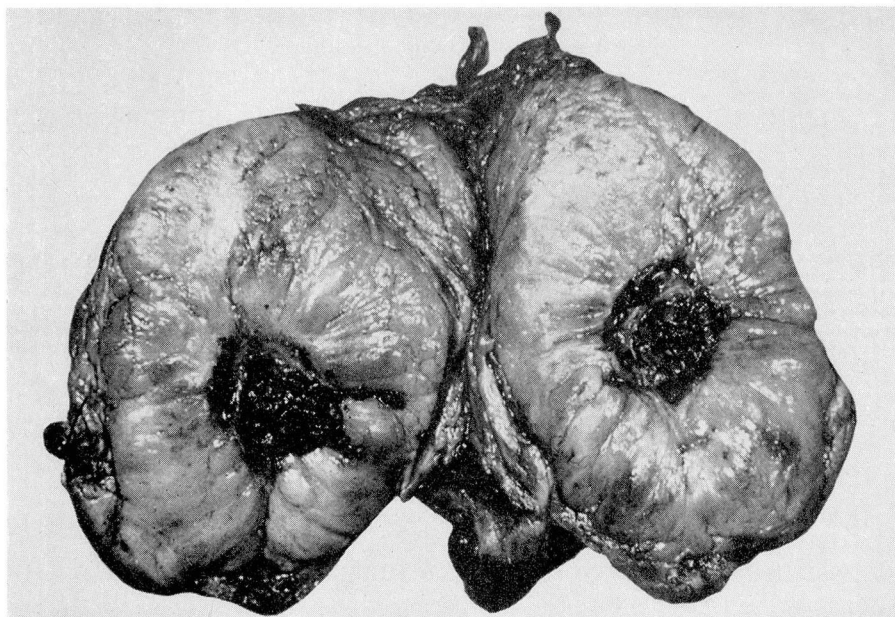
Richard C. Crowell, M.D., St. Joseph, Michigan.

Lipomatous replacement of the kidney, although uncommon, must be considered in the differential diagnosis between renal tumor and renal stone, with or without pyonephrosis.

It is described by Bell (Bell, E. T.: Renal Diseases. Philadelphia, Lea & Febiger, ed. 5, 1946) under the term *lipomatosis*, as a benign disease that rarely causes symptoms other than those attributable to associated renal calculi or pyonephrosis, unless the growth becomes very large.

Since the term *lipomatosis* implies the presence of lipomas, which may become the site of sarcomatous change, the term *lipomatous replacement* better characterizes the process. The fat that replaces the renal parenchyma in this condition arises from the peripelvic fat or from the fat in the renal sinus; the stimulus to its growth is believed to be atrophy of renal tissue. This atrophy is attributable to renal calculi in most cases (76 to 79 per cent), to pyelonephritis fibrosis, or less commonly, to renal tuberculosis. The fatty overgrowth merely replaces lost renal tissue and is not invasive, so that only exceptionally does it become massive and present as a tumor.

Preoperative differential diagnosis is difficult, particularly in the absence of renal stone. The kidney is usually functionless, and pyelography shows deformities that cannot be distinguished from those of renal pelvic or parenchymal tumor. This difficulty is illustrated in the two cases presented. The first patient had a long history of left renal calculus and was considered to have a calculous pyelonephrosis. The initial findings in the second patient strongly suggested either renal neoplasm or nonopaque calculi. The indicated treatment in both patients was nephrectomy—more urgently in the second because of the possibility of renal tumor.



Cross section of the gross specimen of the kidney of the second patient, showing inspissated old blood and pus in the pelvis of the kidney and only a fine rim of renal tissue remaining.

Saturday, September 10

Morning Sessions

R. S. Dinsmore, M.D., *Presiding*

1. GRAFTING FOR MAJOR ARTERIAL OCCLUSIONS. A. W. Humphries, M.D.
2. CARDIOVASCULAR RESEARCH. I. H. Page, M.D.
3. SELECTION OF PATIENTS FOR SURGERY FOR CARDIAC LESIONS.
A. C. Ernstene, M.D.

A. C. Ernstene, M.D., *Presiding*

1. CLINICAL USE OF TAPE RECORDED ELECTROCARDIOGRAMS AND
HEART SOUNDS. W. L. Proudfit, M.D.
2. LUPUS ERYTHEMATOSUS. J. R. Haserick, M.D.
3. HAMANN-RICH SYNDROME (CHRONIC FIBROSING INTERSTITIAL
PNEUMONITIS). H. S. Van Ordstrand, M.D.
4. PRIMARY ALDOSTERONISM: PRESENTATION OF CASE.
E. P. McCullagh, M.D.
5. AMEBIASIS: THE USE OF NEWER DRUGS IN TREATMENT.
C. H. Brown, M.D.
6. ABNORMAL HEMOGLOBIN DISEASES. J. S. Hewlett, M.D.
7. PSYCHOGENIC OBSTIPATION AND HIRSCHSPRUNG'S DISEASE.
R. D. Mercer, M.D.
8. CARDIAC CATHETERIZATION. F. M. Sones, Jr., M.D.

Present Policies in the Treatment of Cancer

George Crile, Jr., M.D., *Presiding*

1. BREAST. R. S. Dinsmore, M.D.
2. HEAD AND NECK. Robin Anderson, M.D.
3. LARYNX. H. E. Harris, M.D.
4. THYROID. J. B. Hazard, M.D.
5. ESOPHAGUS. L. K. Groves, M.D.
6. LUNGS. D. B. Effler, M.D.
7. STOMACH. S. O. Hoerr, M.D.
8. COLON. R. B. Turnbull, Jr., M.D.
9. BLADDER. W. J. Engel, M.D.
10. UTERUS AND CERVIX. J. S. Krieger, M.D.
11. COBALT 60. C. M. Greenwald, M.D.
12. BONE SARCOMA. G. S. Phalen, M.D.

DISCUSSION

1. DECOMPRESSION OF THE TRIGEMINAL ROOT FOR TRIGEMINAL NEURALGIA. K. P. Taarnhøj, M.D.
2. PHEOCHROMOCYTOMA. E. F. Poutasse, M.D.
3. SURGICAL POLICY IN TREATMENT OF DUODENAL ULCER. S. O. Hoerr, M.D.
4. A NEW TYPE OF ILEOSTOMY (Movie). R. B. Turnbull, Jr., M.D.
5. THE X-RAY IN DIAGNOSIS OF INTESTINAL OBSTRUCTION. C. R. Hughes, M.D.
6. SPECIALIZED DENTAL SERVICE TO CHILDREN. J. K. Dunn, D.D.S.
7. TREATMENT OF OPTIC NEURITIS WITH ACTH AND TYPHOID VACCINE. R. J. Kennedy, M.D.

Afternoon Program

UNVEILING OF PORTRAIT OF DR. HADEN. W. E. Flannery, M.D., and John Tucker, M.D.

NEW HOSPITAL—REMARKS. R. S. Dinsmore, M.D.