

# DENTAL PROTECTION DURING ENDOTRACHEAL INTUBATION

CARL E. WASMUTH, M.D.

Department of Anesthesiology

**P**ROTECTION of the patient's dental structures during surgical procedures is a matter of increasing concern to anesthesiologists. Confidence in the increasing efficacy of muscle relaxants has resulted in greater use of intubation of the trachea—expanding the field of risk and the number of possible complications. Among these complications is damage to the teeth or to dental prostheses, the results of which may be serious. Not only may there be cosmetic disfigurement, but if the patient aspirates a dislodged tooth or fragment there may occur grave pulmonary complications or the surgical procedure may have to be prolonged in order to locate and remove the aspirated object.

Formerly, the presence of porcelain jacket crowns, synthetic fillings, gold inlays, and small bridges were possible contraindications to the use of endotracheal anesthesia. Now, because of the excellent muscular relaxation achieved with the newer drugs and improved technics, these dental conditions have become accepted risks. However, emergency conditions sometimes arise: the airway suddenly is compromised or hypoxia develops—the patient's life is in danger and immediate intubation of the trachea becomes mandatory. To visualize the larynx as quickly as possible, the patient's upper incisors become the pivot point for the laryngoscope (Fig. 1), providing leverage against anterior pharyngeal structures. This force may be so great as to damage normal teeth; but, in this situation, concern for the integrity of the incisor ridge is superseded by the immediate necessity of establishing an airway.

If a tooth or dental prosthesis is damaged and the fragments are lost, the possibilities of serious complications arise. Not only must the cosmetic damage be repaired, but all of the dental fragments must be found. During a difficult intubation or endoscopy, it is not uncommon for a dental fragment to be aspirated with a gasping respiration. Roentgenography of the chest is necessary to locate an aspirated fragment; if it is identified, it must be removed by a further operative procedure. Failure to locate and remove all dislodged dental fragments and the subsequent development of pulmonary disease may form the basis for unpleasant medicolegal action.

Numerous appliances have been recommended to prevent injury to the upper teeth. For many years, endoscopists have used lead shields to prevent damage with bronchoscopes or esophagoscopes. However, these were unsatisfactory, for the hard metal would grind against the brittle dental enamel. Anesthesiologists introduced a tooth protector made of adhesive tape, an ingenious device consisting of three or four thicknesses of zinc oxide adhesive tape with the adhesive side exposed to secure the appliance to the teeth, gums,

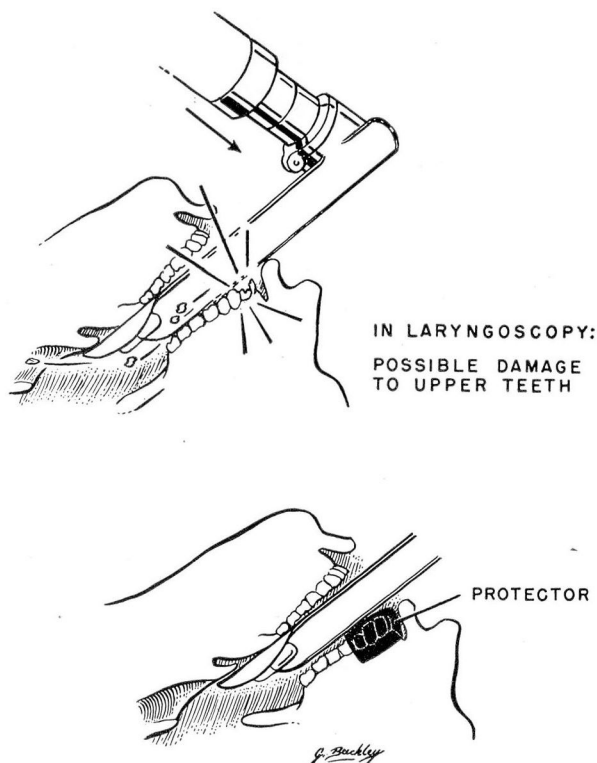


Fig. 1

lips, and skin of the face. The appliance was attached to a string so that if it did slip into the mouth it could be easily retrieved. Unfortunately, the teeth were not adequately protected by this means.

A new device that we have found to be satisfactory is the Greenblum Mouth Protector\* (Fig. 2). This adequately protects the teeth and also prevents aspiration into the trachea of any fragments that might possibly become dislodged in the mouth. This protector, made of a medium-hard but pliable rubber, fits firmly over the four incisors and two cuspids of the upper or of the lower jaw and extends from the anterior gingival margin over the teeth; applied to the upper jaw, the protector extends across the hard palate for a few centimeters (Fig. 3). The protector is so designed as to give relatively even distribution of pressure over the dental area. The edges of the incisor teeth are protected by a cushion of soft rubber embedded in the device at the points of contact with the incisor teeth. The place where the laryngoscope rests is reinforced by an additional layer of rubber. When, in spite of the protection afforded to dental

\*Greenblum Mouth Protector, Louis L. Greenblum, D.D.S., Van Aken Boulevard, Cleveland, Ohio.




Fig. 2. Enlarged photograph of tooth protector.

structures, teeth or dental prostheses are dislodged or fragmented, the pieces are confined within the cavity of the protector and are removed with it.

Primary teeth begin to lose their roots when the child is about three years of age, and continue to shed through the sixth to the twelfth years, so that they are particularly susceptible to being dislodged during oral surgical or

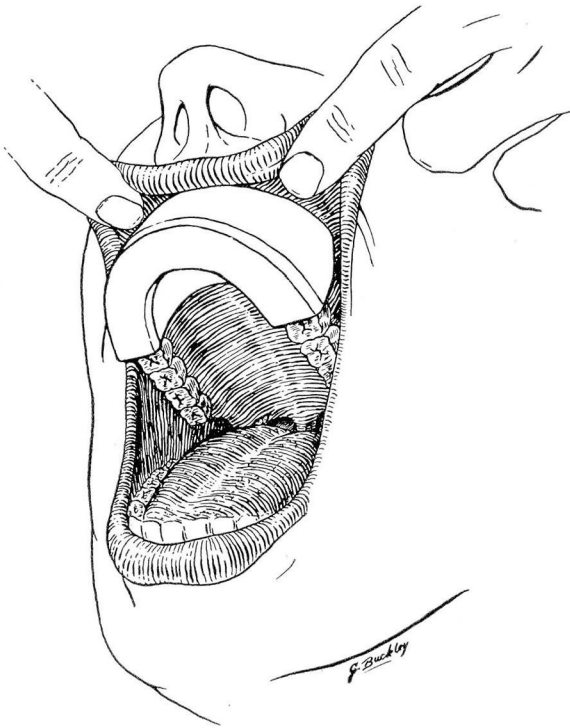


Fig. 3. Application of tooth protector to upper teeth.

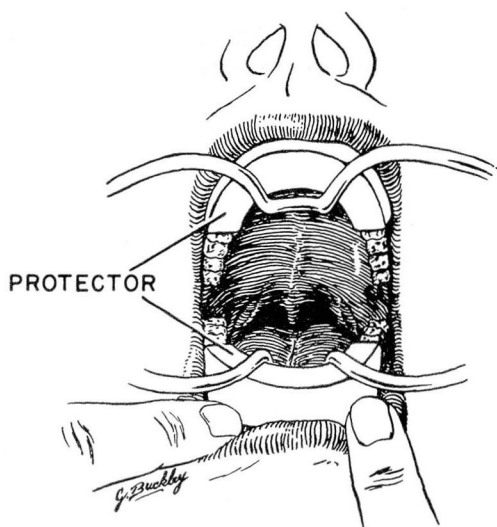


Fig. 4. Protection of the teeth in tonsillectomy.

endoscopic procedures. The small protector, which, because of its basket-like shape retains such dislodged baby teeth in the mouth, is therefore very useful in children (Fig. 4).

### Summary

A tooth protector is described which prevents damage to the incisor teeth during intubation or endoscopy.