

UROLOGIC CAUSES OF HYPERTENSION

I. Hypertension Due to Renal Artery Lesions

EUGENE F. POUTASSE, M.D.,
Department of Urology

and

HARRIET DUSTAN, M.D.
Research Division

CONCEPTS OF HYPERTENSION have undergone significant changes during the past fifty years. The early concept that hypertension was the result of a defective arterial circulation and that to lower blood pressure would be detrimental to life was slowly replaced by a recognition that high blood pressure plays an important role in the maintenance and/or progression of hypertensive vascular disease. Much of the advance in the understanding of clinical hypertension is based upon studies of experimental hypertension. Twenty years ago, hypertension was first produced in animals by (1) section of the sino-aortic depressor nerves (Koch and Mies), (2) constriction of the renal artery (Goldblatt), and (3) production of perinephritis (Page). Subsequently, experimental endocrine hypertension was elicited in rats (Selye) and the hypertension of coarctation of the aorta experimentally reproduced in dogs, although participation of renal mechanisms in the latter has not yet been fully defined.

Hypertension is now looked upon as but one manifestation of a systemic disease. Clinically, the course varies from a relatively benign state, in which the only abnormality is elevated blood pressure to a fulminant process, with widespread arteriolar necrosis. Two broad etiologic categories of hypertensive diseases are recognized. These are: (1) *primary* or *essential* hypertension, for which no single cause is demonstrable; it probably has a genetic basis and includes conditions, such as the hypertensive diencephalic syndrome, which may have specific etiologies; (2) the *secondary* hypertension; these have recognizable causes, although the pressor mechanisms may not yet be fully understood.

In most patients, the diagnosis of *primary* or *essential* hypertension is made by exclusion. It should be emphasized that hypertension of recent onset in a person less than 35 years of age who does not have a family history of hypertensive disease, as also the sudden onset of severe or malignant hypertension in an older person, should be considered secondary until thorough study has excluded definable causal mechanisms.

The mechanisms of the secondary hypertension may be grouped as (1) renal, (2) endocrine, (3) cardiovascular, and (4) neurogenic.¹ Renal hypertension is associated with lesions of the renal artery or with parenchymal disease.

Endocrine hypertension is seen in Cushing's syndrome, primary aldosteronism, and pheochromocytoma. The common types of cardiovascular hypertension occur with coarctation of the aorta and with aortic arteriosclerosis. The hypertension associated with bulbar neuropathy in poliomyelitis and acute porphyria are neurogenic.

Clinical and experimental renal hypertension are thought to be humorally mediated through the renal pressor system. Initially, some change in the renal circulation causes release of an excessive amount of the enzyme, renin; this acts on circulating renin-substrate to split off angiotonin; the latter is a pressor and vasoconstrictor polypeptide that elicits hemodynamic changes comparable to those that characterize hypertension and, experimentally, can elicit lesions of hypertensive disease.² The workings of the renal pressor system have not been well enough defined to accept it as the sole etiologic factor in renal hypertension. Recent studies indicate that secondary mechanisms may participate in the persistence of hypertension. These are adrenal,³ neural,⁴ and other renal factors.⁵

The purpose of this report is to review some of the clinical characteristics, diagnostic procedures and pathologic findings in one form of renal hypertension — that associated with lesions of the renal arteries. It is important that this condition be recognized, for it usually is remediable, often occurs in young people, and frequently assumes a rapidly destructive course.

RENAL ARTERY LESIONS

Historical Background

There are comparatively few well-documented reports of hypertension due to renal artery lesions. In a recent review of nonembolic renal artery occlusion as a cause of renal hypertension,⁶ there were listed 21 autopsy reports and 15 case reports of patients who had been relieved of hypertension by nephrectomy or thromboendarterectomy; three additional case reports of occlusive renal artery disease with hypertension were presented. Pastor and associates⁷ have since reported a case of hypertension, relieved by nephrectomy, associated with a ruptured renal artery aneurysm. A recent Cabot Case⁸ described a patient who died of a dissecting thoracic aneurysm who also had had progressive hypertensive vascular disease associated with partial occlusion of a renal artery. A number of patients with embolism of the renal artery have been reported who had transient or persistent hypertension depending on the degree of renal infarction resulting from the sudden blocking of the artery.^{9,10}

Pathology

Obstructive renal artery lesions can be divided into two main groups: *extrinsic compression* and *intrinsic arterial disease*. Both are capable of causing renal hemodynamic changes and possibly of initiating the release of renal pressor

substances. Extrinsic causes of compression of the renal artery, such as aortic aneurysm or retroperitoneal tumor, are rare, and will not be discussed here. The intrinsic types of renal artery disease include *embolism, thrombosis, developmental defects associated with fibrous intimal proliferation, aneurysm, arteriosclerotic plaques, and syphilitic arteritis.*

An *embolus*, almost invariably from a diseased heart, may obstruct the renal artery or one of its branches and thereby cause partial or total infarction of the kidney. Total necrosis of the kidney does not cause hypertension,¹¹ but partial infarction of the kidney and reduced blood supply in other areas may cause transient reversible hypertension or severe persistent hypertension.^{9,10} Laforet¹² reported the cases of three young men who died of malignant hypertension associated with renal artery lesions, one of which was a metallic embolus of the renal artery. The embolus was a shell fragment that originally had lodged in the chest but later entered the blood stream and occluded the left renal artery. Progressive malignant hypertension resulted, and the patient died shortly thereafter.

Thrombosis of the renal artery or one of its branches may produce hypertension. When there is only one artery supplying blood to the kidney, thrombosis

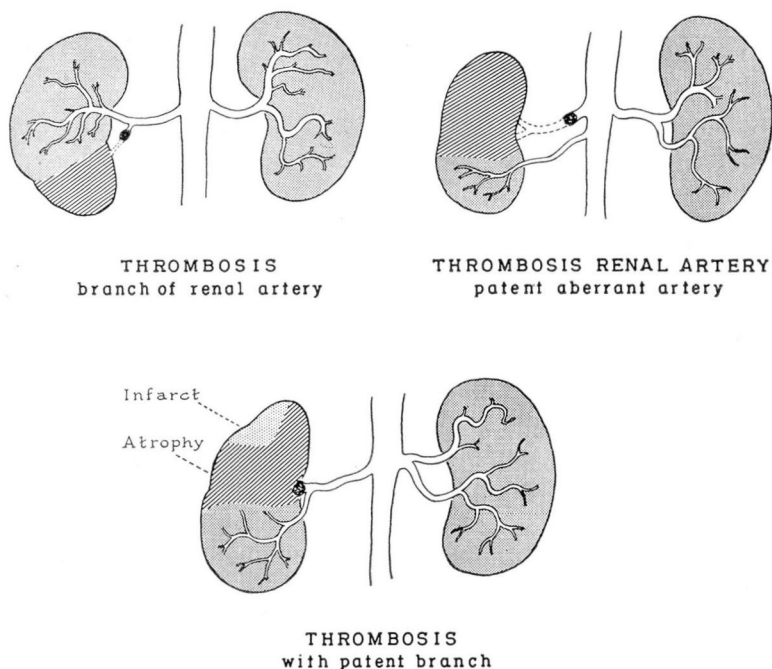
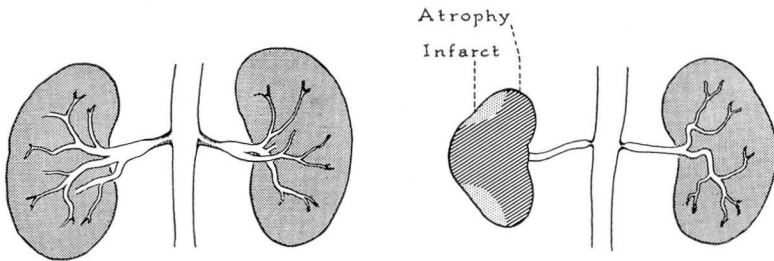


Fig. 1. Renal artery thrombosis associated with hypertension, showing variation in blood supply and renal damage. Embolism may simulate thrombosis. (Adapted from renal angiograms.)

of that artery will cause total infarction without producing hypertension.¹³ If one or more patent aberrant arteries exist, or if only a branch of the renal artery is thrombosed, a portion of the kidney will remain viable, but part of the kidney will have reduced blood supply and hypertension commonly ensues. We have observed and treated four patients with thrombosis of the renal artery associated with severe hypertensive vascular disease. The variations in blood supply, sites of thromboses, and degrees of renal infarction or atrophy are illustrated in Figure 1.

Hypertension in young people sometimes results from what may be considered *developmental defects* of the renal artery. In our experience these defects are bilateral and consist of stenosis of the aortic orifices of the renal arteries, or narrowed segments of the vessels (Fig. 2). In each patient, the bilateral lesions are similar from the roentgenographic and pathologic standpoints. In addition to reduction in diameter of the vessel itself, *fibrous proliferation of the intima* occurs in the narrowed portions and constricts the lumen still more. The result is inadequate renal circulation, release of circulating renal pressor substances and progressive hypertension. We have seen three patients, one reported elsewhere,¹⁴ who developed severe hypertensive vascular disease shortly after puberty or in young adulthood as a result of this type of lesion.



DEVELOPMENTAL DEFECTS WITH FIBROUS INTIMAL PROLIFERATION

Fig. 2. The shaded areas within the narrow portions of the renal arteries indicate fibrous intimal proliferation. (Adapted from renal angiograms.)

Hypertension has been reported in patients with congenital saccular *aneurysm* of the renal artery.^{7,15} Most patients with aneurysm of the renal artery do not have hypertension, presumably because the aneurysm does not interfere with blood flow to the kidney. Renal angiography showed no interference with renal blood flow in our seven patients who had aneurysm of the renal artery or of one of its branches. Only one of these seven patients has been hypertensive, but in this instance the patient also has an arterial lesion of the opposite kidney (Fig. 3, upper right-hand corner). This patient is under medical antihypertensive treatment at the present time.

The formation of hard *arteriosclerotic plaques* at the aortic orifices or within the renal artery constricts the lumen and interferes with blood flow. These

UROLOGIC CAUSES OF HYPERTENSION

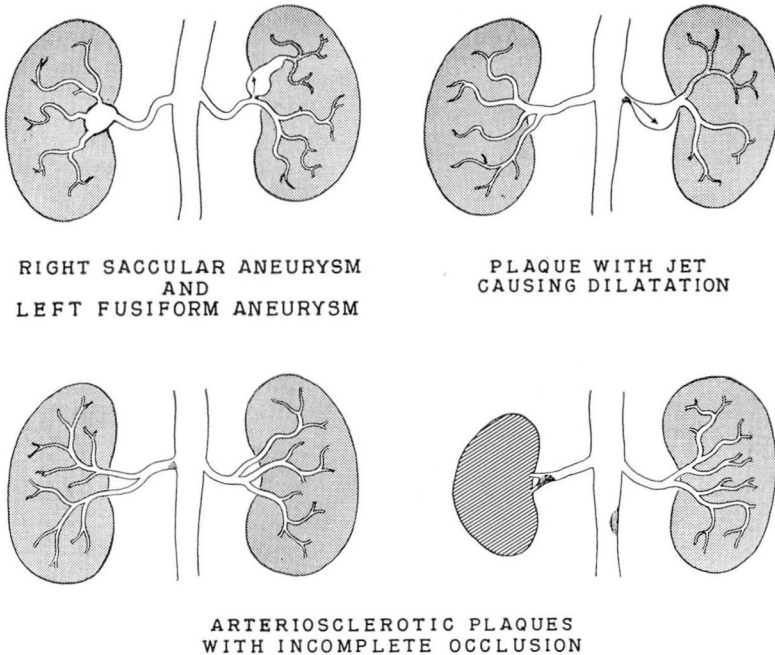


Fig. 3. Variations of hard arteriosclerotic plaques of the renal artery associated with hypertension. The jet dilatation of fusiform aneurysm effect is diagrammed. Congenital saccular aneurysms occasionally are associated with hypertension. (Adapted from renal angiograms.)

plaques usually are a local manifestation of generalized arteriosclerosis. We have had eight patients with severe hypertensive vascular disease who were shown by aortography to have arterial filling defects characteristic of this type of lesion (Fig. 3). Fusiform dilatation of the artery distal to the occluding plaque was demonstrated in three of these eight patients. It is believed that this dilatation of the artery results from the deflection of the blood stream by the obstructing plaque against the arterial wall, and that it is similar to the jet-action aneurysm occurring just beyond the coarctate segment of thoracic aorta. Dilated segments of arteries are abnormal and may be structurally weak. Rupture of the dilated aneurysmal renal artery and severe hemorrhage occurred in one patient; but since the lesion already had been recognized, nephrectomy was immediately performed. This patient recovered and has had a three-year remission of malignant hypertension.

A few instances of *syphilitic arteritis* with incomplete occlusion of the renal arteries associated with malignant hypertension have been reported.¹⁶

Laforet¹² has presented an excellent description of the pathologic changes found in both kidneys of three patients who died of malignant hypertension as the result of unilateral renal artery obstruction. In each case, the kidney with impaired blood supply showed tubular atrophy, a relative increase in interstitial tissue, and benign nephrosclerosis. The opposite kidney with the intact

renal artery, however, showed necrotizing arteriolar lesions characteristic of malignant nephrosclerosis. The situation is very similar to that described by Wilson and Byrom¹⁷ in rats with renal hypertension, where nephrosclerotic changes developed in the normal kidney, but not in the kidney whose artery was compressed.

Any constriction of the lumen of the renal artery with impairment of renal blood flow may cause reduction in the size of the kidney and focal tubular atrophy, but most of the renal epithelium is preserved. There are no significant changes in the arterioles. Further reduction of the blood flow into the kidney will result in more atrophy (Fig. 4) and possibly zones of infarction. Two of our patients with reversible malignant hypertension due to renal artery disease, had no significant reduction in the size of the affected kidneys and the pathologic changes were correspondingly minimal.

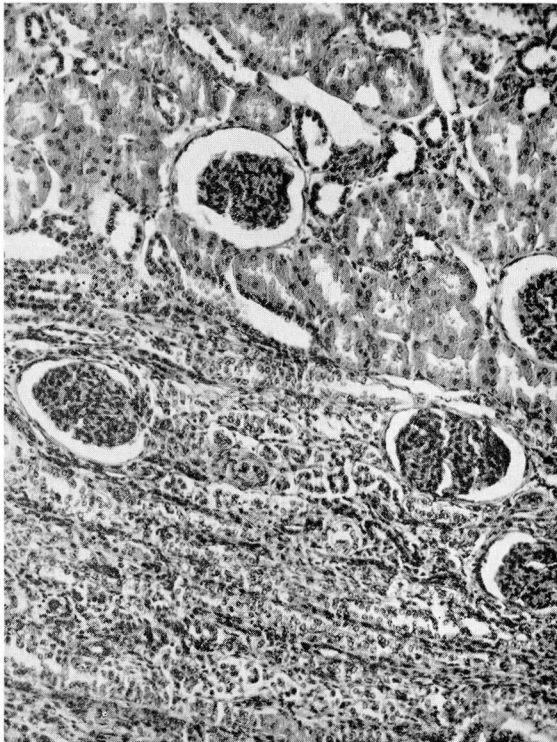


Fig. 4. Photomicrograph of lower pole of the kidney (also see Figure 9) showing the line of demarcation between the normal renal parenchyma above and the zone of atrophy below, resulting from diminished blood supply. X110.

Diagnosis of Renal Artery Lesions

Hypertension should be considered a diagnostic problem, especially in the young adult, in the elderly person, or in those patients in whom there is no

family history of essential hypertension. The *sudden onset of hypertensive vascular disease following an attack of flank pain* should make one consider the possibility of thrombosis or of embolism of a renal artery.¹⁸ The history of a patient with thrombosis of the renal artery is diagrammatically presented in Figure 5. Of more insidious onset is the hypertensive vascular disease caused by partial or incomplete obstruction of the renal artery, usually due to arteriosclerotic plaques (Fig. 6). These plaques may develop at any age, but are more likely to occur in elderly people.

Intravenous urography for visualization of the upper urinary tract should be performed in all nonazotemic hypertensive patients. There are no pathologic changes in the renal pelvis or calyces, except possibly reduction in size, in patients having lesions obstructing the renal artery; but there may be significant decreases in excretory function. Thrombosis of the renal artery will produce a nonfunctioning kidney; but if a patent aberrant artery is present, *the intravenous urogram may reveal essentially normal excretory function with only slight reduction in renal mass and may be regarded as normal* (Fig. 7). When occlusion of a renal artery is incomplete, the appearance-time of the injected contrast medium may be slightly delayed in the kidney with impaired blood supply, and the concentration of medium in the pelvis and calyces may be diminished. However, these changes can be minimal despite serious obstructive lesions of the renal artery.

In the recognition of impaired renal function due to renal artery lesions, an important aid is the comparison of urine samples obtained from both kidneys by ureteral catheterization. Severely ischemic kidneys may be anuric or oliguric. The appearance-time of injected dyes, such as indigo carmine, is delayed. Where the circulatory defect is less severe, the excretory functions of both kidneys may be compared by determinations of urinary osmolarity and electrolyte concentrations and concentrations of injected para-aminohippuric acid (PAH) in the separate urine samples. An example of the findings by this procedure is shown in the Table. The patient, a 33-year-old man, had malignant hypertension. The

Table.—Comparison of excretory functions of the kidneys in patient with malignant hypertension

Condition of kidneys	Osmolarity (mOsm./l.)	PAH (mg.%)	Na (mEq./l.)	K (mEq./l.)
Normal.	418	790	12	26
With constricted artery	362	514	9	24

intravenous urogram in this patient was considered to be normal at first examination; aortography showed partial constriction of the left renal artery with jet dilatation (Fig. 3, upper right-hand corner), and review of the urogram showed some decrease in size of the left kidney.

Translumbar aortography is the only means of demonstrating the presence of renal artery defects. It should be utilized in all patients with hypertension in whom such lesions are suspected. The procedure for aortography has been previously described.¹⁹ To obtain the utmost cooperation from the patient and to minimize the hazards of translumbar aortography, local anesthesia is used

MALIGNANT HYPERTENSION WITH THROMBOSIS OF RIGHT RENAL ARTERY AGE 28

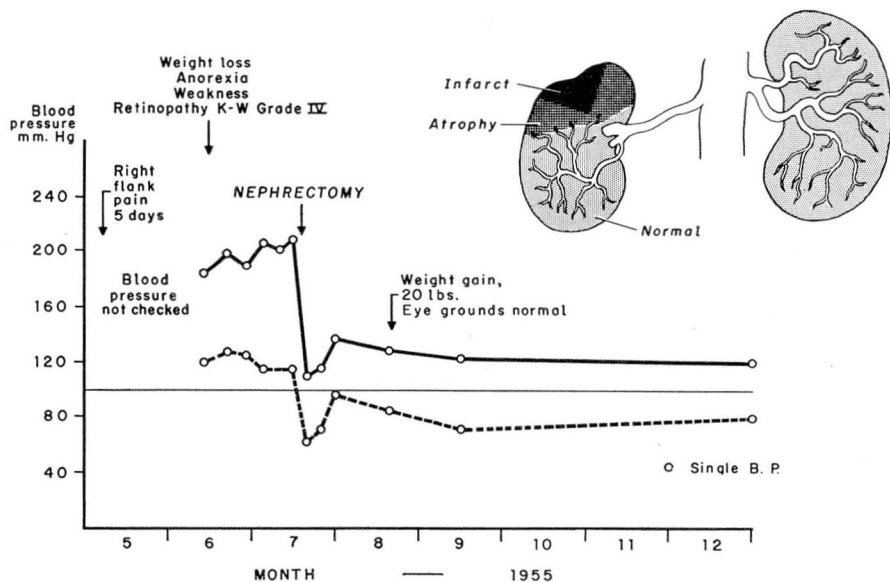


Fig. 5. Diagram of clinical course of acute onset of malignant hypertension in a young man who had had what was considered to be pyelonephritis. The preoperative aortogram showed complete occlusion of the main artery as indicated in the diagram. (Also see Figure 7.) Six months after nephrectomy he was completely well.

MALIGNANT HYPERTENSION WITH RENAL ARTERY DISEASE AGE 49

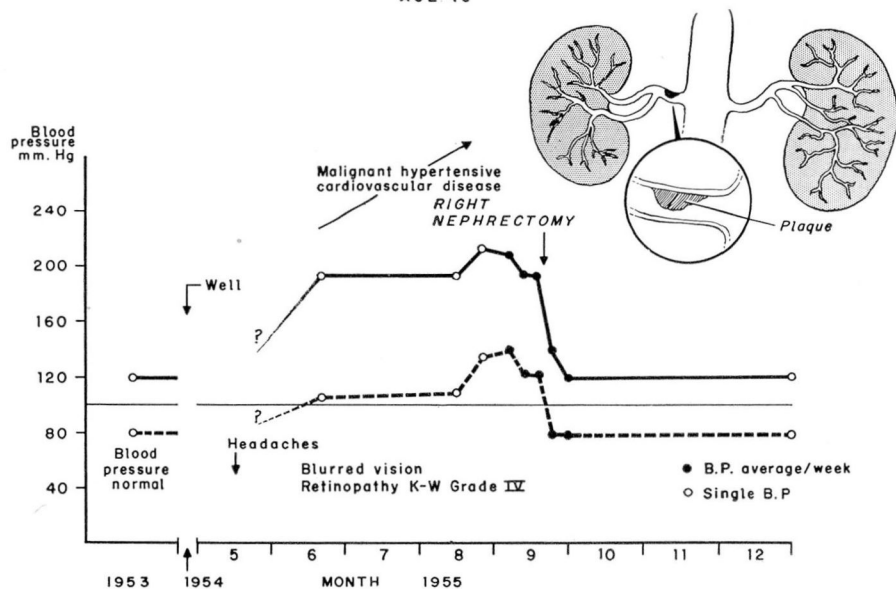


Fig. 6. Diagram of clinical course of rapidly progressive hypertension without history of flank pain. The defect in the right renal artery disclosed by preoperative aortography is diagrammed. The kidney was normal in size and showed only focal tubular atrophy. Three months after nephrectomy the patient was completely well.

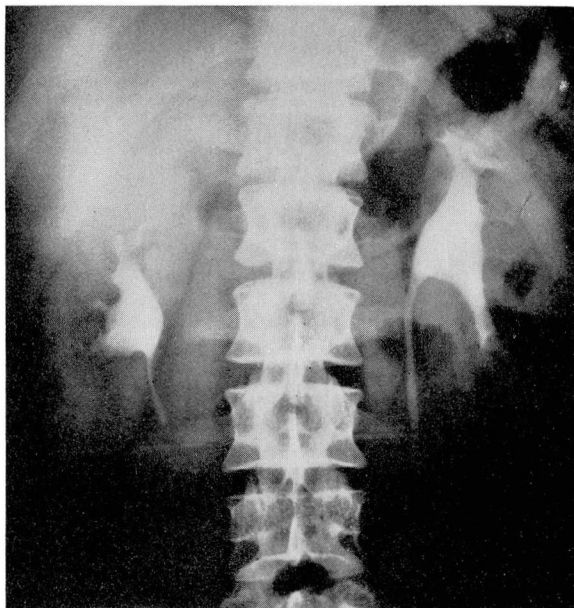

Fig. 7. Intravenous urogram of patient (also see Figure 5) who had thrombosis of the right main renal artery with a patent branch. There is slight reduction in the size of the right kidney; excretory function appears to be normal.

during the examination. In patients with extremely elevated blood pressure it is helpful to use vasodepressor drugs, such as sodium nitroprusside, hydralazine, (Apresoline*) or trimethaphan camphor sulfonate (Arfonad**), to reduce the blood pressure and thereby obtain better compression of the aorta distal to the renal arteries and filling of the arteries themselves.²⁰ The aortogram may demonstrate a filling defect in the renal artery, a narrowed lumen, absence of an important branch, reduction in the vascular system of the affected kidney, or delay in filling of the arterial system past the obstructing lesion (Figs. 8 and 9).

Results of Treatment

In patients with acute malignant hypertension of brief duration caused by a lesion obstructing a renal artery, nephrectomy results in a prompt fall in blood pressure to normal and reversal of hypertensive vascular disease. In patients with hypertension that has progressed gradually to hypertensive vascular disease, the fall in blood pressure is more gradual, reaching normal levels in two or more weeks postoperatively. The secondary mechanisms of renal hypertension, noted above, probably contribute to the persistence of the hypertensive state after nephrectomy in these latter cases.

*Apresoline, Ciba Pharmaceutical Products, Inc., Summit, New Jersey.

**Arfonad, Hoffman-La Roche, Inc., Nutley, New Jersey.

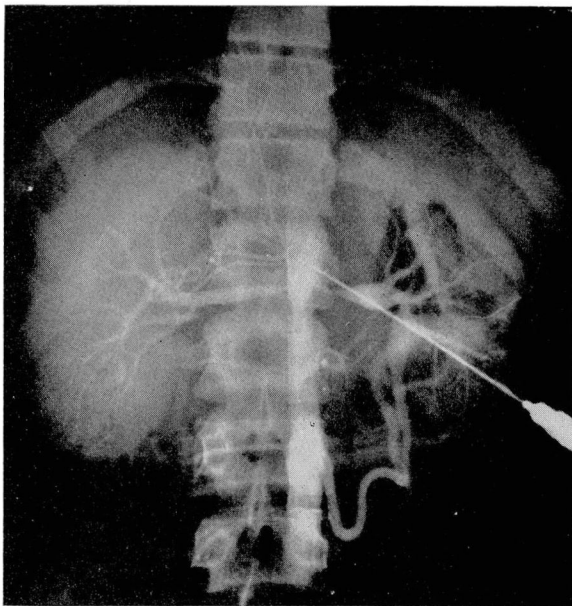


Fig. 8. Aortogram demonstrating narrow developmental defects of both renal arteries in a 15-year-old boy with hypertension (also see Figure 2). Note the distal dilations of the left renal artery. Such a lesion is amenable only to replacement arterial surgery.

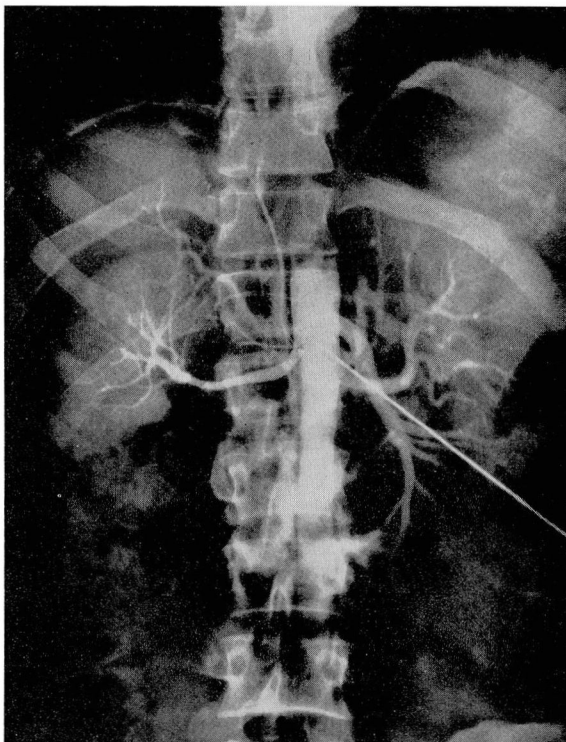


Fig. 9. Translumbal aortogram shows absence of branch of main renal artery to lower pole of right kidney (also see Figure 4). This blood vessel was approximately 70 per cent occluded by fibrous tissue. The patient was 28 years of age and had onset of moderately severe hypertension four months after an attack of renal colic. He was relieved of hypertension by nephrectomy.

In three of our four patients with renal artery thrombosis and acute hypertension, nephrectomy was followed by immediate and permanent reversal of the hypertensive state.⁶ For several days following nephrectomy, one of the three patients had hypotension and oliguria, presumably resulting from the rapid change in the blood pressure. The blood pressure in the fourth patient gradually returned to normal over a period of several months postoperatively. These patients were all men, ranging in age from 28 to 52 years.

Among the eight patients with hypertension associated with obstructive arteriosclerotic plaques of the renal artery, generalized vascular disease was so advanced in two that surgery was contraindicated; both patients now are dead. A third patient is under medical treatment at this time. Of the remaining five patients, two men, 33 and 49 years of age, respectively, had prompt remission of the syndrome of malignant hypertension following nephrectomy. The results of nephrectomy in the remaining three patients, although less dramatic, are of considerable interest. All three were elderly patients who were known to have had mild or moderate arteriosclerotic hypertension for at least several years prior to the sudden onset of malignant hypertension. In each patient, after nephrectomy, the blood pressure returned to the level that had been observed before the malignant phase of hypertension supervened. Of the latter three patients, one underwent nephrectomy three years ago and has had reversal of progressive hypertensive vascular disease; the hypertensive states in the other two are in remission, but treatment is too recent to allow final evaluation.

Two of the three young patients with bilateral developmental defects of the renal artery died in the hospital. The third has recently undergone surgical correction of both defects by means of freeze-dried artery homografts between the aorta and the distal, normal, renal artery.²¹ A gradual fall in blood pressure to normal over a two-week period followed the second renal artery homograft. No alteration of renal excretory function occurred postoperatively.

During operation, a pronounced thrill frequently has been palpable in the partially occluded renal artery. In one patient an effort was made to determine the intra-arterial pressure distal to the occlusion but the pressure was insufficient to produce a reliable reading. In another patient, an immediate fall in peripheral blood pressure of 50 mm. Hg occurred when the partially occluded renal artery was manually compressed. When the vessel was released, the blood pressure promptly rose to former levels. This phenomenon was repeated several times. When the normal renal artery to the opposite kidney was manually compressed, no change in blood pressure was noted.

It also has been noted that the kidney with impaired circulation is soft and flabby compared with the opposite kidney with normal circulation. Both kidneys in the patient who had homografts of defective, narrowed renal arteries became tense as soon as circulation was established through the grafted arteries.

COMMENT

The role of the kidneys as an etiologic factor in hypertension has been under active study for two decades. Until recently, emphasis has been placed on

primary parenchymal renal disease, such as pyelonephritis, and on obstructive uropathy as the chief causes of secondary renal hypertension. When the disease was seemingly unilateral, nephrectomy frequently was performed in the hope of removing the cause of the hypertension. Results often were disappointing. These findings will be discussed in Part II of this paper in a forthcoming issue of this Journal.

Gradually more and more cases of unilateral renal artery lesions associated with *malignant, progressive hypertensive vascular disease* have been reported. This hypertension closely simulates experimental hypertension elicited by partial compression of a renal artery. The results of nephrectomy for this type of lesion are dramatically good—a prompt or gradual fall in blood pressure, depending on the duration of antecedent hypertension, with remission of hypertensive vascular disease.

The history and the findings on examination of each hypertensive patient must be carefully evaluated before the condition is accepted as primary or essential. On the basis of this evaluation, the experienced physician can select those patients who may have secondary renal hypertension and recommend their further study by procedures outlined above.

The chief pitfalls in the diagnosis of renal artery lesions as a cause of hypertension, are the misinterpretation of inadequate aortograms and the failure to appreciate the significance of even minor variations from normal in the comparative sizes of the kidneys or their excretory functions, as shown by intravenous urography. The comparison of excretory functions of both kidneys is a valuable adjunctive measure in the diagnosis of renal hypertension. Aortography provides the only accurate means of demonstrating renal artery lesions, and should be more widely used when secondary renal hypertension is suspected. There are recognized hazards to translumbar aortography but, in selected cases, the risk involved is far outweighed by the possible benefit which will accrue from the discovery and relief of the cause of the hypertensive state.

Summary

Renal artery lesions that may produce hypertensive disease are embolism, thrombosis, developmental defects associated with fibrous intimal proliferation, aneurysm, arteriosclerotic plaques, and syphilitic arteritis. These lesions interfere with blood flow through the renal artery; they may go on to reduce the blood supply to part or all of the kidney, so that zones of renal atrophy or infarction may result. At some point in this process renal pressor substances are released that initiate vasoconstriction and hypertension.

Diagnosis of renal artery lesions as a cause of hypertension is made by careful evaluation of intravenous urograms, comparison of excretory functionings of both kidneys, and demonstration of the defect by aortography. A history of the sudden onset of nonfamilial hypertension, particularly after an attack of flank pain, is suggestive of the presence of this condition.

In properly selected patients, removal of the kidney having impaired blood supply will reverse the hypertensive state. A patient with bilateral renal artery stenosis of developmental origin has recently undergone successful homografting of both renal arteries.

Acknowledgment

We wish to thank William J. Engel, M.D., Department of Urology; and Fay A. LeFevre, M.D., and William L. Proudfit, M.D., Department of Cardiovascular Disease, for the referral of some of the patients described in this study.

References

1. Page, I. H., and Corcoran, A. C.: Arterial Hypertension: Its Diagnosis and Treatment, Ed. 2. Chicago, Year Book Publishers, Inc., 1949, pp. 400.
2. Masson, G. M. C., Corcoran, A. C., Page, I. H., and del Greco, F.: Angiotonin induction of vascular lesions in desoxycorticosterone-treated rats. *Proc. Soc. Exper. Biol. & Med.* **84**: 284-287 (Nov.) 1953.
3. Floyer, M. A.: Further studies on mechanism of experimental hypertension in rat. *Clin. Sci.* **14**: 163-181 (May) 1955.
4. McCubbin, J. W., Green, J. H., and Page, I. H.: Baroreceptor function in experimental renal hypertension (Abstract). *Circulation* **12**: 743-744 (Oct.) 1955.
5. Kolff, W. J.: Discussion of Renoprival Hypertension. Proceedings of Council on High Blood Pressure Research (1955). To be published by the American Heart Association.
6. Poutasse, E. F.: Occlusion of renal artery as cause of hypertension. *Circulation*, scheduled to appear in January 1956.
7. Pastor, B. H., Myerson, R. M., Wohl, G. T., and Rouse, P. V.: Hypertension associated with renal artery aneurysm and relieved by nephrectomy. *Ann. Int. Med.* **42**: 1122-1130 (May) 1955.
8. Case Records of the Massachusetts General Hospital, Cabot Case 41451, Clinical Diagnosis: Dissecting aneurysm of aorta. *New England J. Med.* **253**: 824-828 (Nov. 10) 1955.
9. Ben-Asher, S.: Hypertension caused by renal infarction. *Ann. Int. Med.* **23**: 431-436 (Sept.) 1945.
10. Fishberg, A. M.: Hypertension due to renal embolism. *J.A.M.A.* **119**: 551-553 (June 13) 1942.
11. Teplick, J. G., and Yarrow, M. W.: Arterial infarction of kidney. *Ann. Int. Med.* **42**: 1041-1051 (May) 1955.
12. Laforet, E. G.: Malignant hypertension associated with unilateral renal artery occlusion: three cases. *Ann. Int. Med.* **38**: 667-688 (April) 1953.
13. Regan, F. C., and Crabtree, E. G.: Renal infarction; a clinical and possible surgical entity. *J. Urol.* **59**: 981-1018 (June) 1948.
14. Fisher, E. R., and Corcoran, A. C.: Congenital coarctation of abdominal aorta with resultant renal hypertension. *A.M.A. Arch. Int. Med.* **89**: 943-950 (June) 1952.
15. Abeshouse, B. S.: Aneurysm of renal artery; report of two cases and review of literature. *Urol. & Cutan. Rev.* **55**: 451-463 (Aug.) 1951.
16. Price, R. K., and Skelton, R.: Hypertension due to syphilitic occlusion of main renal arteries. *Brit. Heart J.* **10**: 29-33 (Jan.) 1948.
17. Wilson, Clifford, and Byrom, F. B.: Renal changes in malignant hypertension. *Lancet* **1**: 136-139 (Jan. 21) 1939.
18. Wolffe, J. B., and Donnelly, D. J.: Thrombosis of renal artery simulating coronary thrombosis. *J.A.M.A.* **119**: 27 (May 2) 1942.
19. Smith, P. G., Rush, T. W., and Evans, A. T.: Technique of translumbar arteriography. *J.A.M.A.* **148**: 255-258 (Jan. 26) 1952.
20. Poutasse, E. F.: Blood pressure reduction as aid to renal angiography in hypertensive patients. *Cleveland Clin. Quart.* **22**: 83-88 (April) 1955.
21. Poutasse, E. F., Humphries, A. W., and McCormack, L. J.: Successful bilateral homografts of stenotic renal arteries associated with hypertension. In preparation.