

# FOREIGN BODIES OF DENTAL ORIGIN IN THE MAXILLARY SINUS

**WILLARD PARKER, M.D.**  
Department of Otolaryngology

and

**JOHN K. DUNN, D.D.S.**  
Department of Dental Surgery

**T**HE following two cases are presented because of their unique nature. They demonstrate the behavior of three foreign bodies of dental origin in the maxillary sinus, each of which originated in the maxillary alveolus. In two instances the objects, which were considerably larger than the natural ostium, were extruded to the outside through the nose. Two of them were associated with secondary oral antral fistulae through tooth sockets that had healed per primum following exodontia procedures.

## CASE REPORTS

**Case 1.** The patient, a 58-year-old woman, was first seen in June 1953. She complained of a chronic clear postnasal discharge of long duration which had always been worse in winter months. Following removal of the upper teeth six months previously, the post-nasal discharge became yellow, and this was accompanied by a sensation of pressure in the right cheek.

Examination revealed excessive clear mucous discharge but no pus. Transillumination of the right antrum was dim. Radiographs of the sinuses showed uniform cloudiness of the right antrum and thickened mucosa in the left antrum. There was a large opaque foreign body within the right antrum and two smaller opaque foreign bodies in the left maxillary alveolus (Fig. 1). Irrigation of the right antrum produced a purulent return.

Dental radiographs indicated that the alveolar foreign bodies were in the left maxillary cuspid and molar areas (Fig. 2). In addition, an area of radiolucency suggestive of inflammatory change was noted in the region of the left maxillary cuspid. Exploratory operation of the left maxillary cuspid area was performed on July 29, 1953. During this procedure a semisolid green material was removed which was believed to be a zinc oxide eugenol cement. An inflammatory cyst also was found and removed. Pathologic diagnosis was dental cyst with chronic inflammation.

The patient was advised to have an antromeatal window made in the right inferior meatus for removal of the foreign body and drainage of the antral suppuration, and during the same hospitalization a maxillary alveoloplasty for correction of the alveolar contours and removal of the remaining foreign body on the left. This was deferred by the patient.

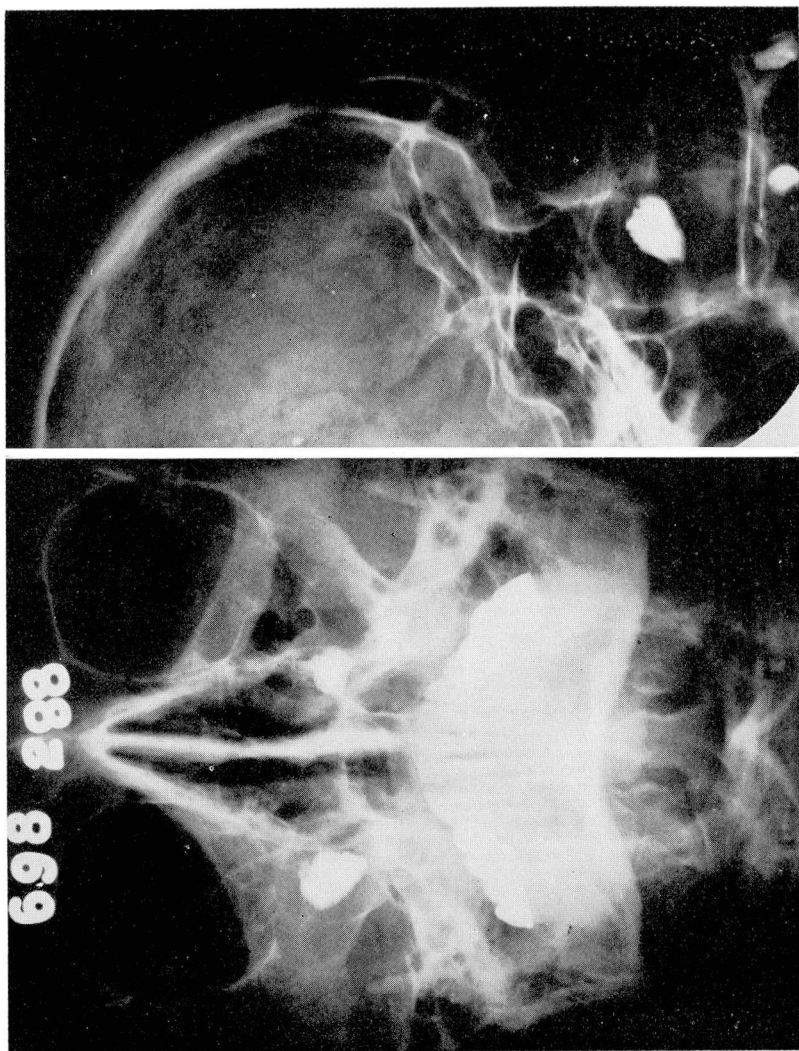
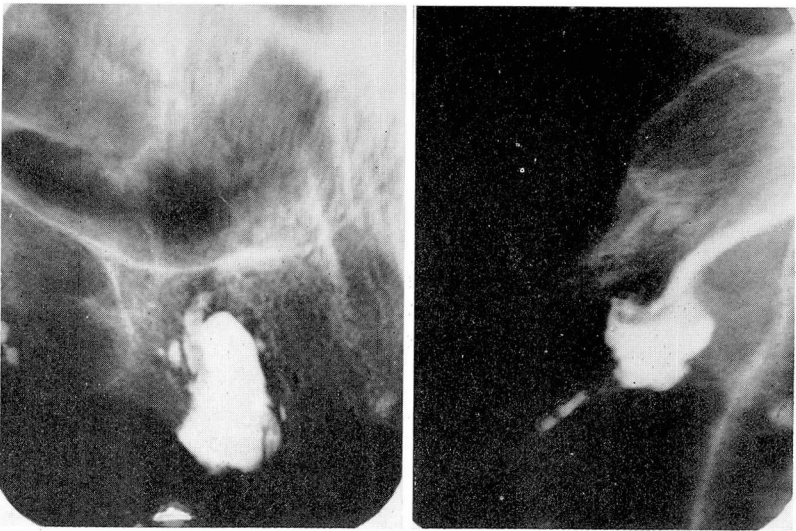
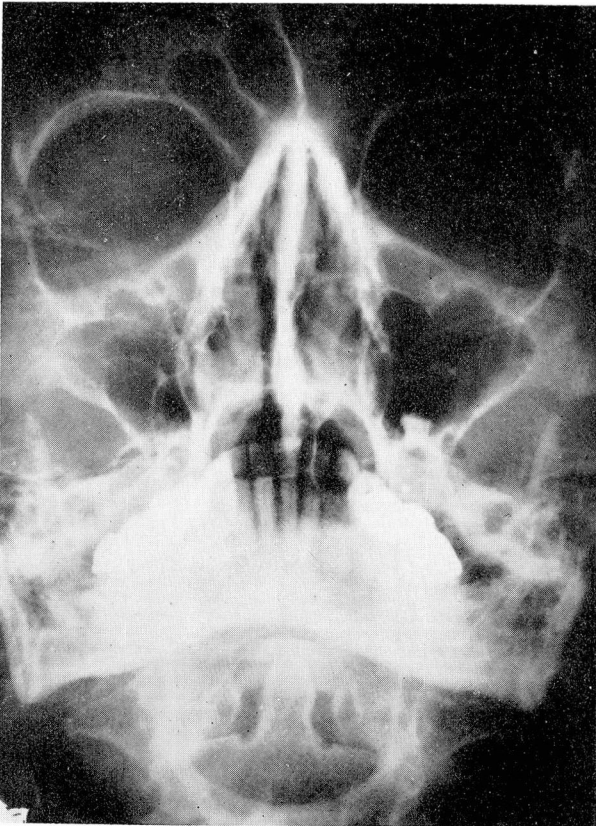


Fig. 1. (A) Waters view and (B) lateral view of sinuses demonstrating foreign bodies in the right antrum and left maxillary cuspid and molar areas. The right antrum is dark.



**Fig. 2.** Dental radiographs showing the alveolar foreign bodies in the left cuspid and molar areas.



**Fig. 3.** Waters view showing clear right antrum after foreign body had passed postnasally. The left maxillary cuspid foreign body had been removed by dental surgery. The foreign body in the left maxillary cuspid area is now projecting into the antrum.



In February 1954, eight months after her first visit, the patient returned stating that she had had an episode of pressure and pain in the right cheek for three or four days, followed by hawking a large stony object postnasally. The symptoms were immediately relieved.

Examination at this time revealed a clean nose, clear transillumination, and clear irrigations bilaterally. Radiographs revealed that the foreign body in the right antrum was missing (expectorated), the one in the left cuspid area was gone (surgically removed), and the one formerly in the left molar area was now in the left antrum (Fig. 3). The expectorated object measured 1 by  $\frac{1}{2}$  by  $\frac{1}{2}$  cm. (Fig. 4).



Fig. 4. The foreign body that was hawked postnasally.

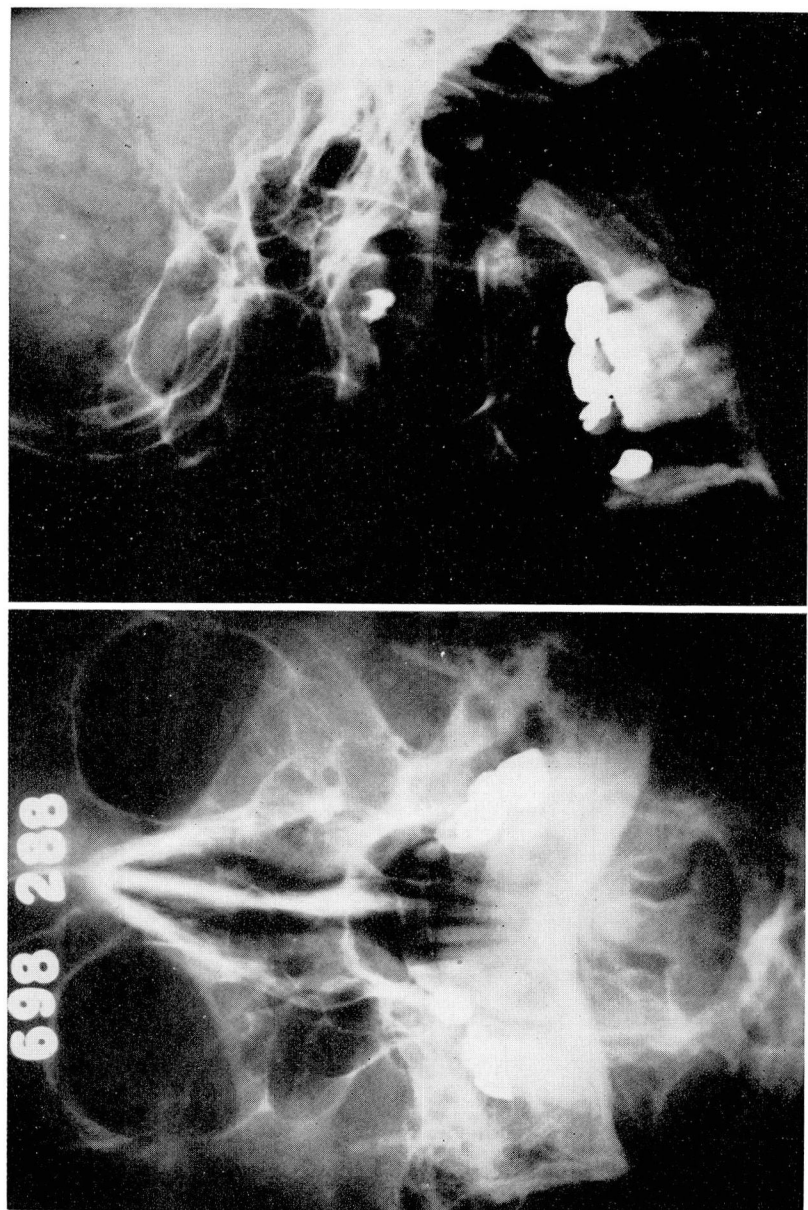
In March 1954, maxillary alveoloplasty was performed under general anesthesia, with immediate rebasing of the upper denture. Three weeks later an examination revealed complete and firm healing and no evidence of irritation or ulceration from the rebased denture. Operation for removal of the remaining foreign body was deferred by the patient.

Five months later, September 1954, the patient again returned, this time with a history of pain over the left cheek, purulent postnasal discharge, and an ulcer on the gum. Examination demonstrated pus in the left middle meatus and a large oral antral fistula in the region of the left maxillary first molar area about  $\frac{1}{2}$  cm. in diameter through which thick pus was exuding. A probe was easily passed into the antrum. Radiographs showed a cloudy left antrum with the foreign body now in the region of the natural ostium (Fig. 5). Dental radiographs taken of the first molar region demonstrated no evidence of residual alveolar foreign body. A left nasooantral window was made in the inferior meatus and the fistula closed with a flap from the buccal aspect of the alveolus and cheek.

**Case 2.** The patient, a 20-year-old man, was first seen in December 1954 with the following history. The upper left first molar had been extracted in June 1951. He was told by his dentist that he had a retained root fragment and was advised to consult an oral surgeon for its removal (Fig. 6). However, healing of the gingival opening was complete and the patient did not follow this advice.

In March 1952 he experienced severe localized pain over the left antrum of several days' duration. The pain was completely relieved by a bout of sneezing during which the fragment was expelled into his handkerchief (Fig. 7). Following this a fetid discharge was noted postnasally and from an ulcer at the site of the previously healed tooth socket.

Examination revealed a left middle meatus full of pus and inflammatory granulations. There was a large opening in the region of the left maxillary first molar which also was full of pus and granulations. A probe passed readily into the antrum. Treatment consisted of a left Caldwell-Luc procedure. The incision was made in such a way as to create a tongue-shaped flap that was mobilized and sutured over the fistulous opening.



**Fig. 5.** (A) Waters view and (B) lateral view demonstrating cloudy left antrum with foreign body in the region of the natural ostium.

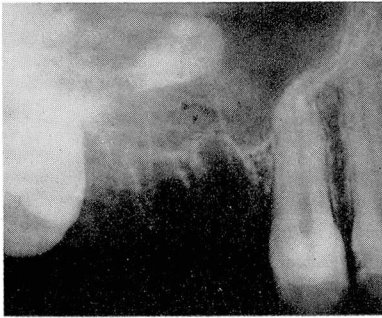


Fig. 6

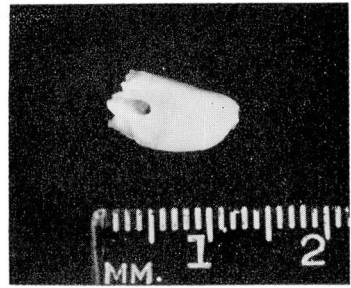


Fig. 7

**Fig. 6.** Dental radiograph showing root fragment in the antrum.

**Fig. 7.** Tooth fragment that was expelled by sneezing.

### DISCUSSION

The interesting aspect of Case 1 is the pathway of the foreign bodies and the associated complications.

It seems likely that the pressure exerted upward by the denture during the act of chewing, would cause pressure atrophy of the tissue between the foreign body and the antral cavity. The presence of infection around the foreign body would aid this process. Thus a pathway would be slowly created through which the foreign body and infection were introduced into the antrum. Since the foreign body was relatively light (specific gravity 1.50), it would tend to move within the medium of pus (specific gravity 1.05) more easily than would a heavy metallic object. If, during sleep, the patient were lying in such a position that the medial wall of the antrum were down and the foreign body were in the region of the natural ostium, it is quite conceivable that the ciliary action would move the object into the ostium. According to Bowditch,<sup>1</sup> ciliated epithelium is capable of 7 Gm.-mm. per minute per sq. cm. of work. Movement of the above object would be well within these limits.

Once in the ostium, the partial or complete obstruction produced would cause a rising intra-sinus pressure that in turn would hold the foreign body in place. Pressure atrophy would allow it to proceed gradually into the nose and thence be expelled as occurred in the first episode in the first patient. In the second episode the increased intra-sinus pressure caused reopening of the original tooth socket, producing a fistula and relief of the pressure.

In Case 2, it is probable that the same mechanism caused the root fragment to be extruded into the nose and the tooth socket to be reopened as a fistula.

### REFERENCES

1. Bowditch, H. P.: Force of ciliary motion. *Boston Med. & Surg. Jour.* 15: 157, 1896.
2. Proetz, A. W.: *Essays on Applied Physiology of Nose*. St. Louis, Annals Pub. Co., 1941, pp. 395.