

WHIPPLE'S DISEASE: REPORT OF CASE APPARENTLY CURED AND DISCUSSION OF THE HISTOCHEMICAL FEATURES

EDWIN R. FISHER, M.D.*

and

JOHN WHITMAN, M.D.

Department of Cardiovascular Disease

INTESTINAL lipodystrophy, first described by Whipple,¹ is a rare disorder, the clinical manifestations of which are less well defined than are the pathologic features. Review articles^{2,3,4,5} indicate that the onset of the disease is insidious, marked by periodic polyarthritides or arthralgia and, at times, chills and fever. Bowel symptoms vary and, although diarrhea usually appears at some time during the course of the disease, it often is not a prominent complaint or may not occur until late; frequently, constipation may be present. Loss of weight, weakness, fatigability, and general debility are common manifestations. Physical findings may include pigmentation of exposed areas of skin, hypotension, evidence of loss of weight and, frequently, peripheral lymphadenopathy. A palpable, abdominal mass may be present, and there may be a small amount of ascitic fluid. Laboratory examination of the blood frequently reveals a hypochromic or a microcytic anemia and a normal leukocyte count. The roentgenographic findings are not pathognomonic, although disturbances of intestinal motility and alteration of the usual mucosal pattern of the small intestine are not uncommon.

Because of these clinical and laboratory manifestations, differentiation from the sprue syndrome, Addison's disease, or rheumatoid arthritis is often difficult; in fact, few examples of a correct antemortem diagnosis of Whipple's disease are recorded.

Histologically, the lesions of the disease are characteristic. They consist of a marked infiltration of the lamina propria of the small intestine by histiocytes that frequently line cystic spaces of varying size. Although these latter are sudanophilic, the histiocytes fail to stain with Sudan dyes. Their cytoplasm reacts strongly to the periodic acid-Schiff stain. Occasionally, multinucleated giant cells of the foreign-body type are present within the infiltrated mucosal zone. Similar histiocytic infiltration and varying degrees of fibrosis obliterate the usual architecture of the mesenteric lymph nodes. In addition, evidence of serositis may be present in the capsule of the liver and the spleen. Chylous obstruction has not been present in those instances in which the cisterna chyli and its tributaries have been examined.

* Formerly of the Department of Pathology; present address, Department of Pathology, The University of Pittsburgh School of Medicine, and V. A. Hospital, Pittsburgh, Pa.

During the past four years, we have observed a patient in whom the diagnosis of Whipple's disease had been made after excision biopsy of a mesenteric lymph node. The results of the histochemical investigation of the excised tissues and the satisfactory clinical course following roentgen and nitrogen-mustard therapy are of particular interest.

CASE REPORT

Clinical Findings

A 27 year old white housewife was examined on July 14, 1950, because of primary complaints referable to a recurrent, migratory polyarthritis and arthralgia that had occurred during the preceding two years. On previous occasions, her symptoms had been diagnosed elsewhere as the result of rheumatic fever and rheumatoid arthritis. She herself had noted having intermittent enlargement and tenderness of lymph nodes (particularly in the cervical chain), recurrent bilateral pleuritic pain, sporadic febrile elevations associated with chills or chilly sensations, fatigue, and weakness. Gastrointestinal symptoms had been sporadic and included vague postprandial epigastric distress, pyrosis, nausea, and occasional vomiting. She had lost 17 pounds in weight during the previous year. The past history was not otherwise significant except that, at the age of 17 years, she had had what her physician referred to as a "butterfly rash" over the nose and malar areas.

The patient was thin and pale. The temperature was 99 degrees F., and the blood pressure was 100/60 mm. Hg. Patches of light-brownish pigmentation were noted on the left forearm and in the left temporal area, and there was slight hyperpigmentation at the borders of the malar erythema. The mucous membranes were pale, and there were discretely enlarged and tender lymph nodes in the cervical chains and in the left supraclavicular area. Findings from the examination of the heart and the lungs were normal, except for the presence of a grade II systolic murmur at the cardiac apex. The remainder of the physical examination revealed no clinically significant findings.

Laboratory studies showed the hemoglobin value to be 8.0 Gm./100 ml.; the blood count to be 3,630,000 erythrocytes and 7600 leukocytes per cu. mm.; and the erythrocyte sedimentation rate 0.87 mm./min. (corrected reading by the Rourke-Ernstene method). Subsequent laboratory studies included: urinalyses; Wassermann and Kahn reactions; blood sugar, cholesterol, urea and urea-clearance determinations; all febrile agglutination tests; cultures of urine, blood, and bone marrow; plasma lupus erythematosus test; serum determinations for calcium, phosphorus, sodium, potassium, and chloride; and routine stool examination; all of which were within normal limits. The examination of the bone marrow revealed hyperplasia of the myeloid series, but there were no diagnostically significant changes. There were no significant abnormalities in the plasma-protein fractions, as determined by electrophoresis.

Roentgenographic examinations of the chest, the gallbladder, the esophagus, the stomach, the duodenum, and the colon, and an intravenous urogram were normal. Interval roentgenographic studies of the small intestines demonstrated that barium had reached the colon at the end of four hours. The barium tended to adhere to the mucosa and there was definite fragmentation and segmentation of the barium pattern.

The frequency and severity of febrile elevations increased. Eventually, the temperature reached 102 to 103 degrees F. daily; the pattern included normal temperatures in the forenoon, with spiked elevations in the afternoon or evening. Therapeutic trials

on penicillin and aureomycin did not alter the clinical picture. The patient's unfavorable clinical course continued until October 20, 1950, approximately three months after initial examination, at which time administration of cortisone was begun and there immediately followed a dramatic subsidence of fever and symptoms. She was afebrile and asymptomatic for six weeks, during which time steroid therapy gradually was withdrawn. There was then a correspondingly gradual return of the clinical signs and symptoms previously described. On January 11, 1951, approximately six months after initial examination, an enlarged lymph node was removed from the left posterior cervical area.

Microscopic Examination

Lymph Node. Sections of this node stained with hematoxylin and eosin revealed preservation of the usual architecture of the lymph node. However, the centers of many of the lymph follicles were occupied by epithelioid cells and an occasional multinucleated giant cell of the foreign-body type (fig. 1). Caseation necrosis was not present. Although

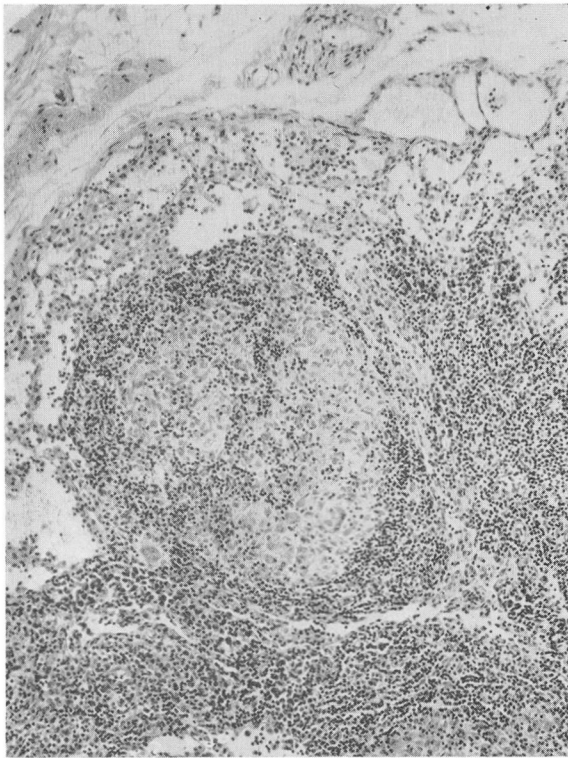


Fig. 1. Section from peripheral portion of cervical lymph node demonstrating epithelioid reaction. Hematoxylin and eosin. X 90.

the cytoplasm of the epithelioid cells reacted faintly with the periodic acid-Schiff stain, the intensity of this reaction was obviously less than that noted in the histiocytes of the mesenteric lymph nodes subsequently removed, and was similar to that observed by one of us (E.R.F.) as occurring in epithelioid cells in other pathologic states.

About six weeks after removal of the lymph node, a mass was palpated in the left upper abdominal quadrant, and a week later an exploratory laparotomy was performed. In the mesentery of the jejunum, there were a number of very firm lymph nodes measuring 3 to 4 cm. in diameter. The liver was covered with mottled, pale, pinkish-white areas and there were multiple perisplenic adhesions, the result of serosal involvement.

Mesenteric Lymph Nodes. Sections of the mesenteric lymph nodes stained with hematoxylin and eosin revealed obliteration of the usual lymph-node architecture except for the persistence of portions of the peripheral sinus. This alteration was due to the presence of numerous histiocytes having abundant finely granular cytoplasm and round-to-ovoid vesicular nuclei. These cells were arranged in aggregates in addition to lining cystic spaces of varying size, which appeared in paraffin sections to be optically clear (fig. 2). Fibrosis and an inflammatory infiltrate comprised of plasma cells, occasional

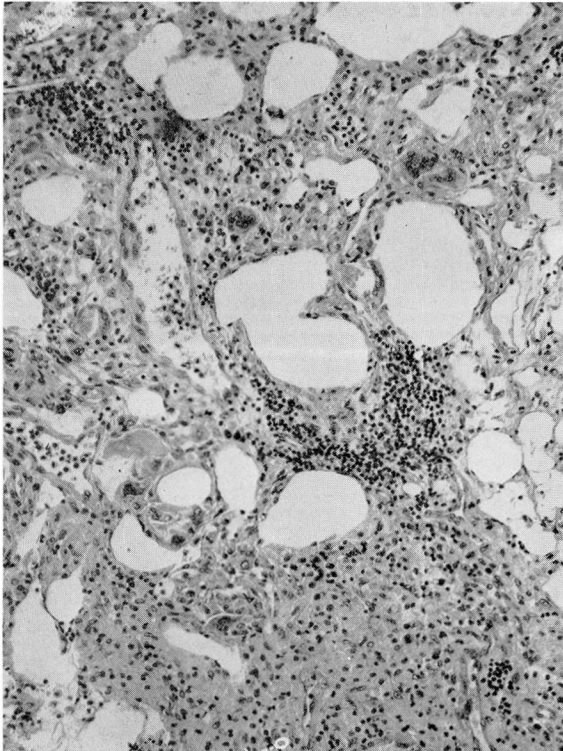


Fig. 2. Section from mesenteric lymph node stained by hematoxylin and eosin. Large cystic spaces are present with aggregates of histiocytes as well as lymphocytic infiltration and an occasional multinucleated giant cell. X 120.

neutrophils and lymphocytes that were arranged in a nodular manner, as well as foreign-body giant cells, were conspicuous within the intercystic tissue. The capsule of the lymph node was markedly thickened and appeared to be comprised of an inner zone of dense, relatively acellular, connective tissue; and an outer zone of more loosely arranged fibrous tissue with areas of fibroblastic and capillary proliferation and numerous histiocytes and giant cells as noted in the main substance of the nodule. The results of the histochemical reactions, performed on the mesenteric lymph node, with reference to the reactions in the histiocytes and cystic spaces are presented in the table.

Liver. A section of liver revealed an increase in the amount of connective tissue of the capsule, with fibroblastic proliferation and lymphocytic infiltration. Fibrin masses were also apparent on the capsular surface. The liver cells contained small cytoplasmic vacuoles that stained with Sudan IV. In addition, moderate glycogen deposition was present within the hepatic cells, as evidenced by the comparison of diastase-digested and diastase-undigested sections stained by the periodic acid-Schiff procedure.

Subsequent to the surgery, roentgenologic therapy to the abdomen was administered. The patient improved, but continued to have intermittent fever to 100 degrees F. and frequent, cramping, abdominal pain. Four months after the roentgen therapy, she was given a course of four intravenously administered doses of nitrogen mustard.

The patient was last examined on June 2, 1954, approximately four years after initial examination, at which time she had no complaints. She had obtained full-time employment and was working regularly in addition to doing her household tasks. There had been rare and short-lived recurrences of arthralgia involving the ankles, with no elevation of temperature. Her appetite was excellent and she had gained 25 pounds since her initial examination, and 40 pounds since hospitalization in October of 1950. There were no abnormal physical findings; the temperature was 99.6 degrees F. (rectally) and the blood pressure 130/78 mm. Hg. She had received no medication since administration of the nitrogen mustard. Laboratory observations demonstrated a hemoglobin content of 13.4 Gm./100 ml.; a blood count of 4,960,000 erythrocytes and 4050 leukocytes per cu. mm.; and a sedimentation rate of 0.45 mm./min. A routine urinalysis was normal.

COMMENT

The pathogenesis of Whipple's disease has not been established. Although early investigators interpreted the pathologic changes as being the result of a primary lipodystrophy, recent studies have suggested the possibility that the changes may be related to an abnormality of ground substance. Inclusion of this disease in the group of so-called collagen diseases has been suggested, and some aspects of the present case support this contention. The subsidence of symptoms following cortisone therapy with recurrence following withdrawal of this substance, as well as the presence of a facial lesion similar to that observed in lupus erythematosus indicate a relationship to the collagen diseases. The combined symptoms of chills and fever, lymphadenopathy and blood alterations suggest generalized systemic involvement.

Upton⁶ observed an epithelioid reaction within axillary and other extra-abdominal lymph nodes as well as within the endocardium. In our case a sarcoid-like reaction was also noted within the cervical lymph node removed prior to laparotomy. However, in Upton's and in our cases the results of the

histochemical reactions noted within these histiocytes, and the nonspecific morphologic picture present, indicate that biopsies of peripheral lymph nodes cannot be utilized to establish the diagnosis of this disease.

From the histochemical reactions it becomes evident that the material within the histiocytes that reacts positively to the periodic acid-Schiff stain represents mucopolysaccharide. Since we have been unable to demonstrate a protein or lipid moiety, it is most unlikely that the periodic acid-Schiff reaction is due to glycolipid or glycoprotein as proposed by Black-Schaffer⁷ and Upton.⁶ The absence of metachromasia within the cytoplasm of these cells indicates that the material is neutral mucopolysaccharide. Although Upton⁶ reported positive metachromatic reactions in these cells, our results in failing to elicit metachromasia conform to those noted by Christie and Galton⁸ as well as by Casselman.⁹

TABLE
Nature of the Reactions in the Histiocytes and Cystic Spaces
of the
Mesenteric Lymph Node

(The methods performed are those utilized by Lillie¹⁰ except where indicated.)

METHODS	RESULTS	
	Cystic Spaces	Histiocytes
Sudan Black B, Sudan IV and oil red O (frozen sections)	Positive *	Rarely positive
Sudan Black B on paraffin sections at 25° and 60° C.	Negative	Negative
Periodic acid-Schiff method	Negative	Positive **
Diastase digestion followed by periodic acid-Schiff	—	No change
Hyaluronidase (Wyeth) 1500 TRU/mg. 150/U/cc. in 5.5 sodium acetate-acetic acid buffer for 1 hr. at 37° C. followed by periodic acid-Schiff and Rinehart—Abul- Haj methods	—	No change
Thionine (pH4, 1:10,000) for ½ hour (frozen and paraffin sections)	Negative	No metachromasia
Rinehart—Abul-Haj method	Negative	Positive
Schultz method for cholesterol and esters	Positive	Negative
Fischler's method for fatty acids and soaps.	Positive	Negative
Feulgen plasmal for acetal phosphatids	Negative	Negative
Peracetic acid-Schiff reaction for unsaturated compounds	Negative	Negative
Millon reaction for tyrosine-containing protein ¹¹	Negative	Negative
Diazonium coupling reaction	Negative	Negative
Ferric ferricyanide reduction test.	Negative	Negative
Polarization.	Positive for birefringent crystals	Negative

* See figure 3.

** See figure 4.

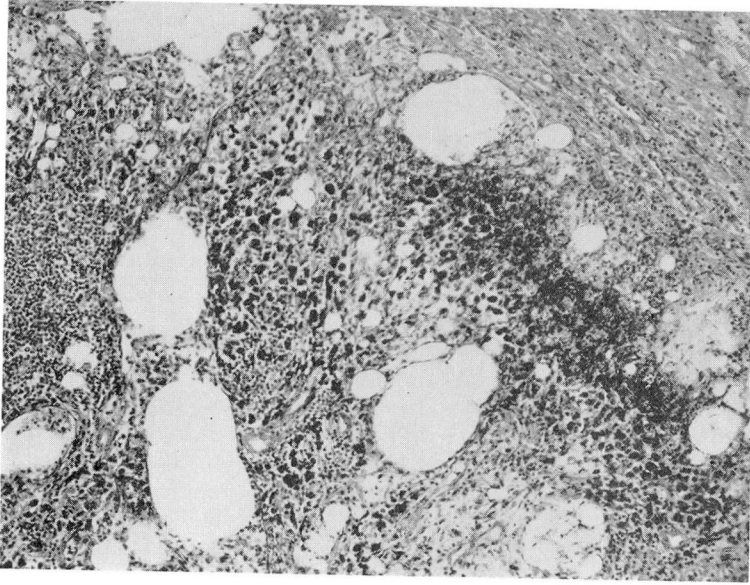


Fig. 4
Section from mesenteric lymph node stained with Sudan IV. The cystic spaces are positively stained (appear black). X 90.

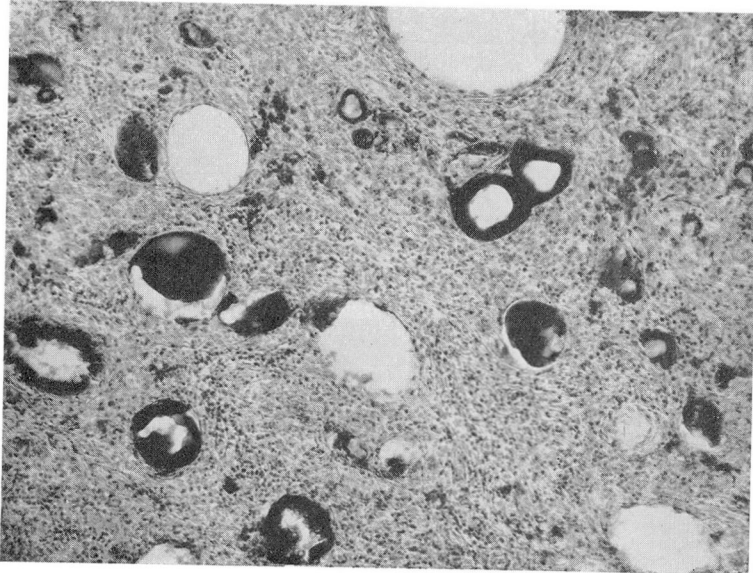


Fig. 3
Section from mesenteric lymph node stained by the periodic acid-Schiff method. The cytoplasm of the histiocytes are intensely colored (appear black). X 90.

Whether the differences observed in the metachromasia represent significant variations in the mucopolysaccharide complex encountered in this disease awaits further investigations.

The occurrence of neutral fats, free fatty acids, soaps, cholesterol and its esters, as well as phospholipids and unsaturated lipids within the cystic spaces has been reported. We have confirmed the presence of these lipids except for the latter two. The question of whether this difference in findings is of the same significance as that noted in the carbohydrate substances observed within the histiocytes, similarly cannot be answered at this time.

The histochemical observations do not elucidate the fundamental derangement responsible for this disease. However, altered lipid metabolism does not appear to be as significant in the etiology of the disease as alterations in mucopolysaccharide: The latter is consistently found in the ubiquitous histiocytes observed in this disease. The possible source for mucopolysaccharide, as Upton⁶ has suggested, may be degenerated ground substance, phagocytized epithelial mucin or the reflection of elevated blood hexosamine levels. Although histochemically the carbohydrate substance differs from epithelial mucin, in this case and those reported by Cassellman⁹ and Christie and Galton,⁸ lacking metachromasia, the possibility of alteration of epithelial mucin cannot be overlooked. Similarly, although the nature of ground substance has not been specifically defined from a histochemical standpoint, at least in some instances such material has been digested from tissue sections by hyaluronidase. This phenomenon did not occur in our case. Yet, alteration of this material either before phagocytosis or following such action could explain the failure of this reaction. Whether such periodic acid-Schiff reactive substance reflects the presence of elevated hexosamine values awaits the determination of this substance in the blood of patients suffering from Whipple's disease.

Although the histochemical studies do not elucidate the pathogenesis of this disease, they are of diagnostic value. According to Hendrix and his associates,² certain cases, although considered on cursory examination to be examples of Whipple's disease, on careful scrutiny do not present the characteristics of this disease entity but, instead, are variously examples of chylous obstruction, exogenous lipogranulomatosis, or *tabes mesenterica*. The marked staining reaction observed with the periodic acid-Schiff in the cytoplasm of the histiocytes is unlike that noted by one of us (E.R.F.) in two examples of chylous obstruction.

The apparently favorable response to irradiation and roentgen and nitrogen-mustard therapy suggests consideration of the application of this type of therapy in other cases of Whipple's disease.

SUMMARY

A case of Whipple's disease, or so-called "intestinal lipodystrophy," is presented in which a satisfactory clinical response has been noted following

roentgen and nitrogen-mustard therapy. The patient has been free of symptoms for four years following diagnosis, and a recent follow-up physical examination and laboratory studies did not reveal any abnormalities.

The histochemical study of the excised mesenteric lymph nodes reaffirms the mucopolysaccharide nature of the cytoplasmic granules observed within the histiocytes found in lesions of this disease. Although the clinical features in this case suggest the possibility that this malady represents a variant of the collagen diseases, the histochemical studies fail to establish such a relationship or the true nature of the disease. However, the histochemical results suggest the need for further biochemical investigation of carbohydrate substances in patients with the disease. The diagnostic significance of the periodic acid-Schiff reaction is emphasized.

References

1. Whipple, G. H.: A hitherto undescribed disease characterized anatomically by deposits of fat and fatty acids in the intestinal and mesenteric lymphatic tissues. *Bull. Johns Hopkins Hosp.* **18**:383-391 (Sept.) 1907.
2. Hendrix, J. P., Black-Schaffer, B., Withers, R. W. and Handler, P.: Whipple's intestinal lipodystrophy; report of 4 cases and discussion of possible pathogenic factors. *Arch. Int. Med.* **85**: 91-131 (Jan.) 1950.
3. Russo, R. R.: Whipple's disease: review of literature and report of 2 cases. *A.M.A. Arch. Int. Med.* **89**: 600-614 (April) 1952.
4. Peterson, J. C. and Kampmeier, R. H.: Whipple's intestinal lipodystrophy: its relationship to the rheumatic state. *Am. J. M. Sc.* **221**: 543-560 (May) 1951.
5. Plummer, K., Russi, S., Harris, W. H. and Caravati, C. M.: Lipophagic intestinal granulomatosis (Whipple's disease); clinical and pathologic study of thirty-four cases, with special reference to clinical diagnosis and pathogenesis. *Arch. Int. Med.* **86**: 280-310 (Aug.) 1950.
6. Upton, A. C.: Histochemical investigation of the mesenchymal lesions in Whipple's disease. *Am. J. Clin. Path.* **22**: 755-764 (Aug.) 1952.
7. Black-Schaffer, B.: The tinctorial demonstration of glycoprotein in Whipple's disease. *Proc. Soc. Exper. Biol. & Med.* **72**: 225-227 (Oct.) 1949.
8. Christie, A. C. (London) and Galton, D. A. G.: A fatal case of intestinal lipodystrophy of Whipple investigated during life. *J. Path. & Bact.* **64**: 351-366 (April) 1952.
9. Casselman, W. G. B.: Pathologic histochemistry of Whipple's disease (with a consideration of certain relevant aspects of methods for carbohydrates and lipids). *Proceedings of the Histochemical Society in J. Histochem. & Cytochem.* **1**: 391, 1953.
10. Lillie, R. D.: *Histopathologic technic*, Ed. 2. New York, The Blakiston Co., 1954.
11. Pearse, A. G. E.: *Histochemistry*. Boston, Little, Brown & Co., 1953.