

REPAIR OF THE CLEFT LIP

ROBIN ANDERSON, M.D.

Department of Plastic Surgery

ONE out of every eight hundred children in the United States is born with a cleft lip, a cleft palate, or both. Within this group of congenitally deformed infants, 25 per cent will have only a cleft lip, 50 per cent a cleft lip associated with cleft palate, and the remaining 25 per cent a cleft palate alone.¹ The cosmetic deformity of the cleft lip, often mistakenly called "harelip," even today carries with it a social stigma of major proportions. During recent years, improved surgical technics and their widespread use by well-trained plastic surgeons have succeeded in reducing the degree of deformity to the point where in most cases it should not be a serious problem to the patient.

The mechanism by which the defect is produced may be explained as the failure of the median nasal and maxillary processes to fuse during the second fetal month. While objection can be raised to this theory, no more reasonable explanation has been offered. The cause of this noncoalescence remains obscure, though experiments with animals have shown that many congenital anomalies may be reproduced by modifying the chemical environment of an embryo during specific periods of its growth. The concept that inheritance is a major factor in the appearance of the defect is increasingly accepted, since 30 to 40 per cent of these patients present a family history of the same deformity.¹

It is important to understand that a congenital deformity involving the mouth and face is a problem requiring integrated medical supervision. Not only the services of the surgeon, but those of the pediatrician, the dentist, the otolaryngologist, and the speech therapist will in all probability be essential to proper care of the patient. In some cases the assistance of the psychiatrist may be required. It is not enough for the surgeon to repair a cleft lip or palate and then to divest himself of the responsibility associated with producing a socially adjusted adolescent or adult.

From the surgical standpoint, one attempts to accomplish four specific ends in the repair of a cleft lip. First, the cleft must be closed. Secondly, an effort is made to reconstruct normal cosmetic features, such as nostril symmetry, fullness of the vermilion, a smooth vermilion border and normal eversion of the lower third of the lip. Thirdly, the scar of the repair should be minimal and not deforming. Finally, damage to blood supply and growth centers must be avoided by meticulous planning and careful handling of tissues. It has been shown that surgical damage contributes prominently to the secondary growth difficulties so common in persons with this defect.²

Preoperative Management

Much has been published in recent years concerning the proper age at which to repair the cleft lip. While it is obvious that increased size of the in-

volved structures makes possible a slightly more precise operative procedure, it is equally evident that if one carries this theme to its logical conclusion, no congenital defect should be repaired prior to adulthood. The latter course is patently impractical if one considers its social implications. One likewise must recognize the concern of the horror-struck parents of an infant newly born with a deformity of this magnitude. With these factors in mind and with much accumulated evidence that the mortality rate of the surgical procedure remains negligible, we elect to repair the lip as soon as possible after birth. Surgery during this immediate postnatal period is well tolerated by the infant. Jaundice, marked loss of weight, weight less than six pounds, or evidence of other congenital or acquired disease are contraindications to immediate surgery.

In preparing the baby for surgery, a single feeding is withheld if feedings have already been started. No preoperative medication is used. The baby should be securely wrapped at the start of the procedure to avoid his manually contaminating the surgical field. A moderate Trendelenburg position with the operator sitting at the infant's head, is utilized. The anesthetic agent of choice is ether, preferably administered into the pharynx through a soft rubber catheter sutured to the tongue. It is unwise to undertake ether anesthesia with other than an experienced anesthetist in attendance, since it may be difficult to maintain the infant within the narrow limits between dangerously deep anesthesia and anesthesia so light that precise surgical manipulation is impossible. The amount of anesthetic agent required and of incidental loss of blood may be reduced if 1 per cent procaine containing 5 to 10 drops of 1 to 1000 epinephrine per ounce is infiltrated locally following marking of the lip.

Operation

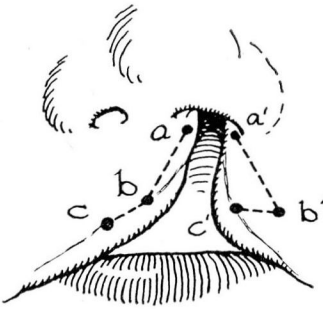
The plan of repair of the cleft lip depends in considerable degree on the type of defect to be closed. Briefly, cleft lips may be classified as complete, single or double, and with or without associated alveolar defect and/or cleft palate.

Two plans are in common use for closure of the single lip, with comparable results. In the first, outlined by Brown and McDowell,³ a small triangular flap is constructed on the lateral side of the defect, to supply both fullness and eversion of the lower segment of lip and to break the straight line of scar (fig. 1). The second method, originally presented by Hagedorn in 1892 and recently revised by LeMesurier,⁴ utilizes a small square or rectangular flap for the same purpose (fig. 2). The surgeon's personal preference will be the significant determining factor in his choice of methods. In the complete cleft lip markedly deficient in soft tissue, the former plan may offer some advantage.

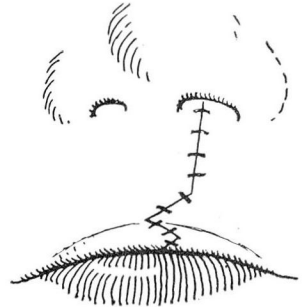
The lip is marked with methylene blue according to either of these plans (figs. 1 and 2). In these figures, ab must equal $a'b'$; bc must equal $b'c'$; and cd must be of the same length as $c'd'$. The points c and c' in figure 1 and d and d' in figure 2 are on the vermilion border at levels where vermilion is sufficiently full to permit adequate repair.

Incisions are made as shown, using thumb and index fingers across the

BROWN-McDOWELL



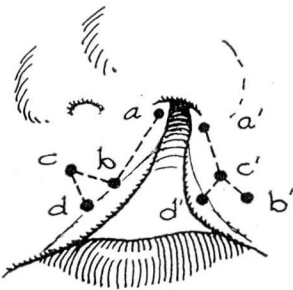
A.



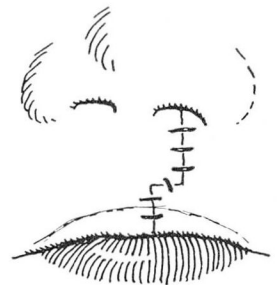
B.

Fig. 1. Repair of unilateral cleft lip using a small triangular flap at the vermillion border.³
(A) Plan of incisions. (B) Result following closure.

L e M E S U R I E R



A.



B.

Fig. 2. Repair of unilateral cleft lip by means of a rectangular flap.⁴ (A) Plan of incisions.
(B) Result following closure.

lateral aspect of the lip as an atraumatic clamp to control bleeding. The buccal fornix is incised and the lip freed from the alveolar ridge as necessary. Minimal lateral mobilization by blunt dissection is carried out only if there is insufficient relaxation to permit closure without it. The nasal cartilages are left undisturbed unless there is severe distortion of the superior aspect of the nostril, in which case the overlying skin may be dissected from the cartilage with fine-pointed scissors to permit realignment of these tissues. The vermilion is incised either to interdigitate or to close vertically, depending on the amount of tissue available.

The lip margins are accurately approximated, using two or three 4-0 chromic catgut sutures in the muscle layer, and 7-0 black silk in the skin. Vermilion and all mucosal edges are closed with slightly heavier black silk. A single mattress stay suture is usually placed from the posterior aspect of the lip at the base of the nostril.

No dressing is applied. A small, vaseline-gauze plug in the newly constructed nostril may be useful for 24 hours to prevent swelling if dissection of the cartilage has been carried out. A Logan clamp prevents accidental trauma to the lip following operation.

The planning of the repair of a double cleft is similar, though with less satisfactory end results. Either a square or a triangular flap is outlined on each side, depending on the size and shape of the premaxilla and the desired vertical height of the lip (fig. 3). If there is any question as to the proper length, one is advised to err on the side of shortness. Not only is the normal infant lip a short one, but if future revision is to be carried out, the lip can be lengthened with ease, while the reverse procedure of shortening may be difficult and yield unsatisfactory results.

DOUBLE CLEFT LIP

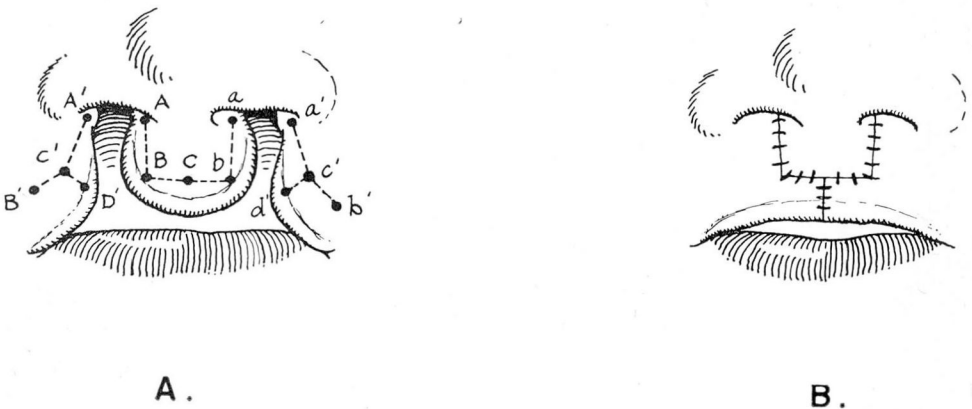


Fig. 3. Repair of bilateral complete cleft lip, showing the use of a rectangular flap on each side of the cleft. The shape and size of the premaxillary tab as well as the desired lip length will determine the type and dimensions of these flaps. (A) Plan of incisions. (B) Result following closure.

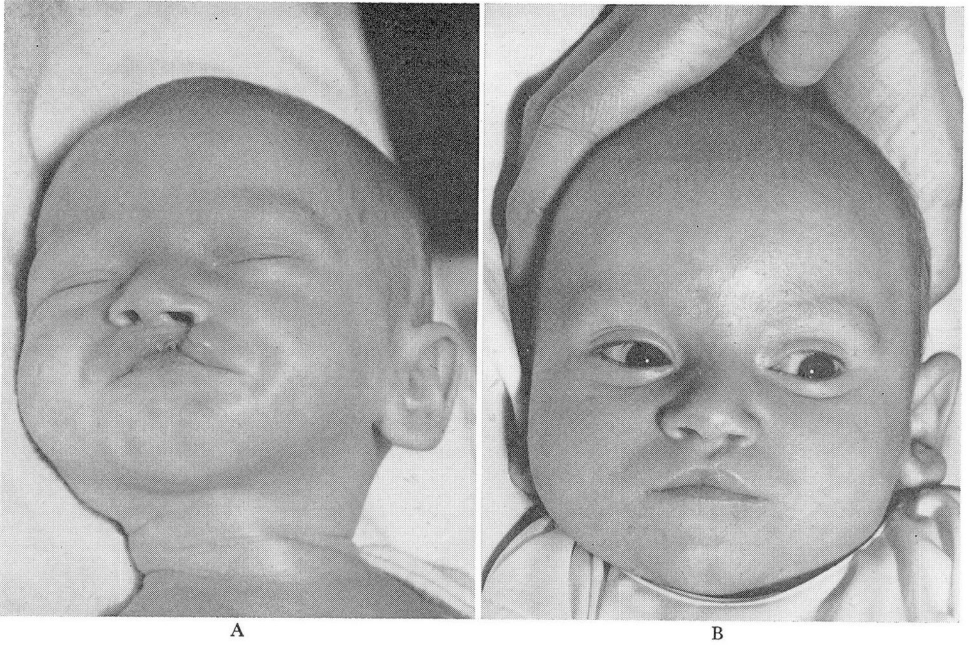


Fig. 4. Incomplete unilateral cleft lip. (A) Preoperative. (B) Postoperative.

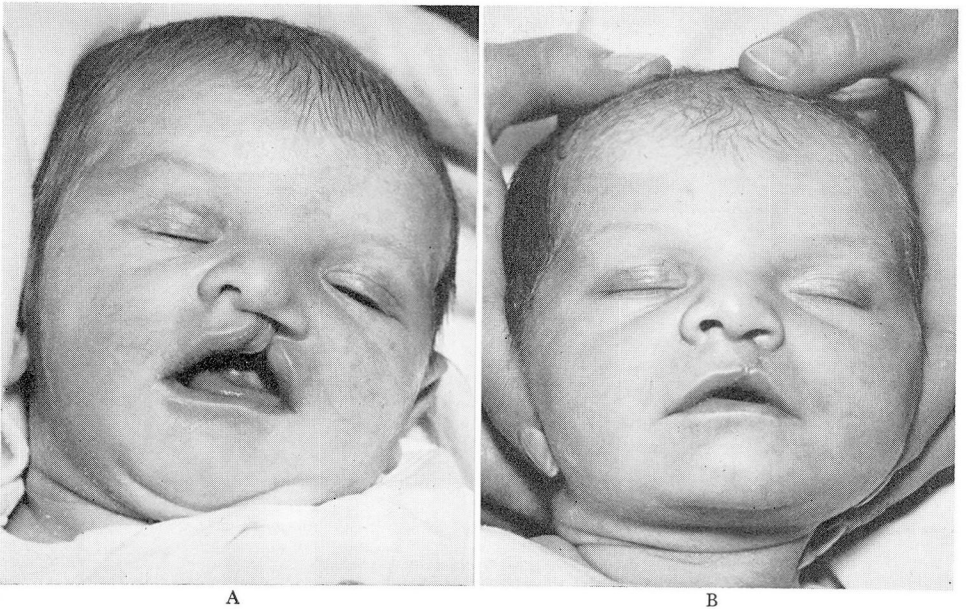


Fig. 5. Complete unilateral cleft lip. (A) Preoperative. (B) Postoperative.

If possible, the lip is closed without manipulation of the bony portion of the premaxilla, even if a two-stage closure is required. Occasionally, the premaxillary tab is so displaced that it must be set back toward the alveolar ridges. This is accomplished by removal of a small wedge of septum, followed by fixation by means of a straight needle passed through the premaxilla into septum and vomer. Lip repair is done at the same time.

Once again, it should be emphasized that minimal tissue damage and minimal disturbance of blood supply and growth centers are essential to the normal development of these facial structures. One cannot urge too strongly the value of precise planning and meticulous technic.

Postoperative Management

The immediate postoperative care is simple and straightforward. The lip is cleansed with saline sponges every hour for the first day and thereafter as necessary, to prevent the formation of crusts around the sutures. Feedings by bulb syringe are started as soon as possible after the infant leaves the operating room. Intravenous fluids are administered only if necessary. Skin and vermilion sutures are removed on the fourth postoperative day; mucosal sutures remain until time of discharge on the ninth or tenth day. When the baby is discharged, a soft nipple may be safely substituted for the feeding syringe.

It is anticipated that the repair of an associated cleft palate will be carried

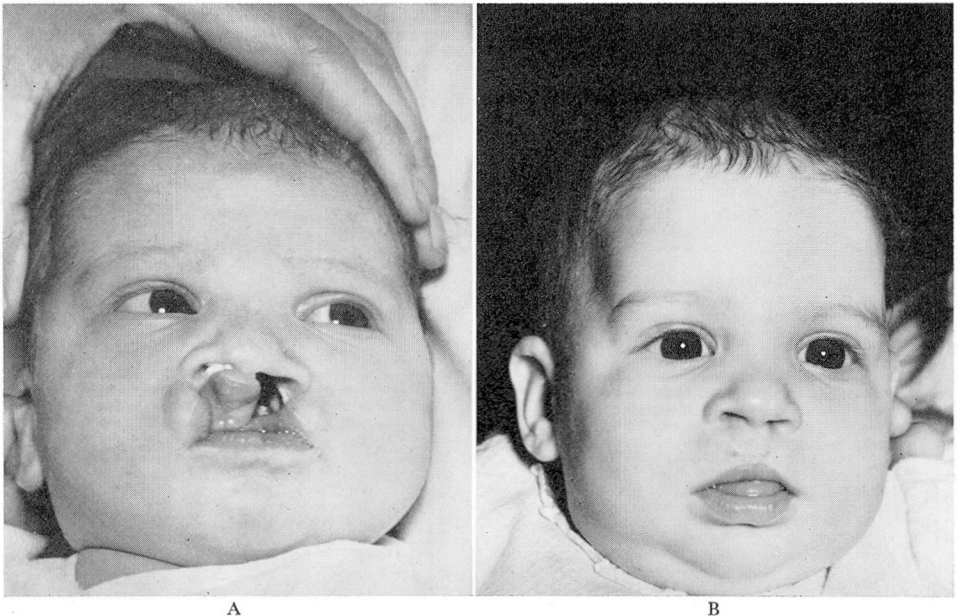


Fig. 6. Bilateral cleft lip: right side incomplete, left side complete. Repair carried out using a small rectangular flap from each side. (A) Preoperative. (B) Postoperative.

out 15 to 18 months later, if the lip has been repaired at birth. At that time the original lip repair is re-evaluated and a program outlined for additional surgery as necessary to reconstruct the nasal columella or revise the nose or lip. In most instances this can be undertaken before the child reaches school age, but often it cannot be completed until middle or late adolescence. During the waiting period the resources of all the allied specialists will be essential to the normal maturation of the patient.

References

1. Andersen, P. F.: Harelip and cleft palate; 1000 patients submitted to operation. *Acta chir. Scandinav.* **94**: 213-242, 1946.
2. Slaughter, W. B. and Brodie, A. G.: Facial clefts and their surgical management in view of recent research. *Plast. & Reconstruct. Surg.* **4**: 311-332 (July) 1949.
3. Brown, J. B. and McDowell, F.: Simplified design for repair of single cleft lips. *Surg., Gynec. & Obst.* **80**: 12-26 (Jan.) 1945.
4. LeMesurier, A. B.: A method of cutting and suturing the lips in the treatment of complete unilateral clefts. *Plast. & Reconstruct. Surg.* **4**: 1-12 (Jan.) 1949.