

CONTROLLED HYPOTENSION IN THE SURGICAL TREATMENT OF CERTAIN CASES OF PATENT DUCTUS ARTERIOSUS

Report of Four Cases

LAURENCE K. GROVES, M.D., DONALD B. EFFLER, M.D.

Department of Thoracic Surgery

and

F. MASON SONES, JR., M.D.

Department of Cardiovascular Disease

THE surgical treatment of patent ductus arteriosus is well established and is indicated in almost every case. Usually it is not technically difficult, particularly in children. However there are certain cases, mostly in adults, in which the operative procedure is fraught with technical difficulty and hazard. These cases are complicated by degenerative vascular disease or unusual anatomic configuration of the ductus and adjoining vessels. The vessel walls about the ductus may have undergone changes caused either by cystic medial necrosis or by subacute endarteritis; calcium deposits may have formed beneath the intima. Large ducti may be associated with hypertension and secondary aneurysmal changes in the pulmonary artery. Occasionally a ductus may be of large caliber and short length, resembling an aortic pulmonary window more than a persistent vessel that communicates between the aorta and pulmonary artery. Whenever one or more of these features are present, the ductus is no longer a pliable plastic vessel that is amenable to safe surgical closure. Furthermore, the danger of uncontrolled hemorrhage increases directly with the degrees of vascular degeneration and pulmonary hypertension.

Controlled hypotension during surgery is an established technic that has proved of considerable value in conditions where frank hemorrhage or troublesome oozing is anticipated.¹⁻³ It has been most widely used by neurosurgeons and those surgeons doing extensive abdominal operations for advanced carcinoma. It not only reduces hemorrhage but shortens operative time. However, it certainly is a procedure not to be undertaken lightly and has definite contraindications including severe anemia, disease of the coronary arteries and renal disease.

Our interest in applying the technic of controlled hypotension to surgery of patent ductus arteriosus was stimulated by the fatality that occurred in the operating room, which is briefly described.

The patient was a 23 year old man in whom the diagnosis of an enormous patent ductus arteriosus with pulmonary hypertension had been established by the usual diagnostic procedure and cardiac catheterization. At operation, a

ductus measuring 3.8 cm. in diameter and only 1 cm. in length was encountered. The pulmonary artery at its bifurcation measured 7 cm. in diameter. The aorta, which had a fusiform dilatation at the ductus, was completely mobilized above and below to increase the degree of control, and a very large Potts-Smith type of clamp, especially devised for this case, was applied to the aortic end of the ductus. Following occlusion of the sclerotic ductus, a rent appeared in the aneurysmal pulmonary artery, and in spite of all efforts to control the hemorrhage, the patient died. Extreme vascular degeneration with notable increase in intraluminal pressure was the major factor in this case.

Since then, we have utilized controlled hypotension in four patients having complicated patent ductus arteriosus. We are in complete agreement with Glenn⁴ that the procedure is an extremely valuable adjunct in this type of operation. In all four cases hypotension was induced by arteriotomy with controlled bleeding. We have not used autonomic blocking agents in these procedures; undoubtedly, as reported by Glenn,⁴ they are equally satisfactory. However, in the younger age group, in which category most of our patients belong, it is not unusual to find that autonomic blockade will not induce sufficient hypotension, whereas arteriotomy never fails to do so.

Most cases of complicated patent ductus arteriosus may be foretold from preoperative examination, including radiographic and catheterization studies. Upon inspection of the ductus at the time of surgery, it is usually apparent that it has undergone degenerative changes: the tense, pulsating vessels have a brittle appearance that is formidable to the surgeon who contemplates the operative division. Following the use of controlled arteriotomy bleeding, which allows induction of precise and variable hypotension, it is extremely gratifying to be able to see that the involved vessels have become soft and pliable. With reduction in intraluminal pressure, a significant decrease in vascular caliber occurs.

We believe that every patent ductus arteriosus should be divided. In the complicated case, one has little choice but to divide the ductus, since ligation of a degenerated or window type of ductus is particularly hazardous. When the patient is hypotensive, the ductus can be much more adequately mobilized and clamps can be applied well back onto the softened parent vessels, thus obtaining adequate cuffs for closure even of the very short ductus.

A brief summary of each of the four cases in which this technic was used follows.

CASE REPORTS

Case 1. A 28 year old white woman had a patent ductus arteriosus and aneurysmal dilatation of the pulmonary artery as shown in figure 2. By cardiac catheterization she was found to have pulmonary hypertension and there was decreased oxygen saturation of the blood in the femoral artery as compared with that in the brachial artery, due to partial shunt reversal through the ductus. At operation the ductus measured 2.5 cm. in diameter and there was marked dilatation of the pulmonary artery. The ductus and adjoining pulmonary artery appeared to have undergone degenerative changes and appeared to be very friable. After exposure of the area, controlled hypotension was

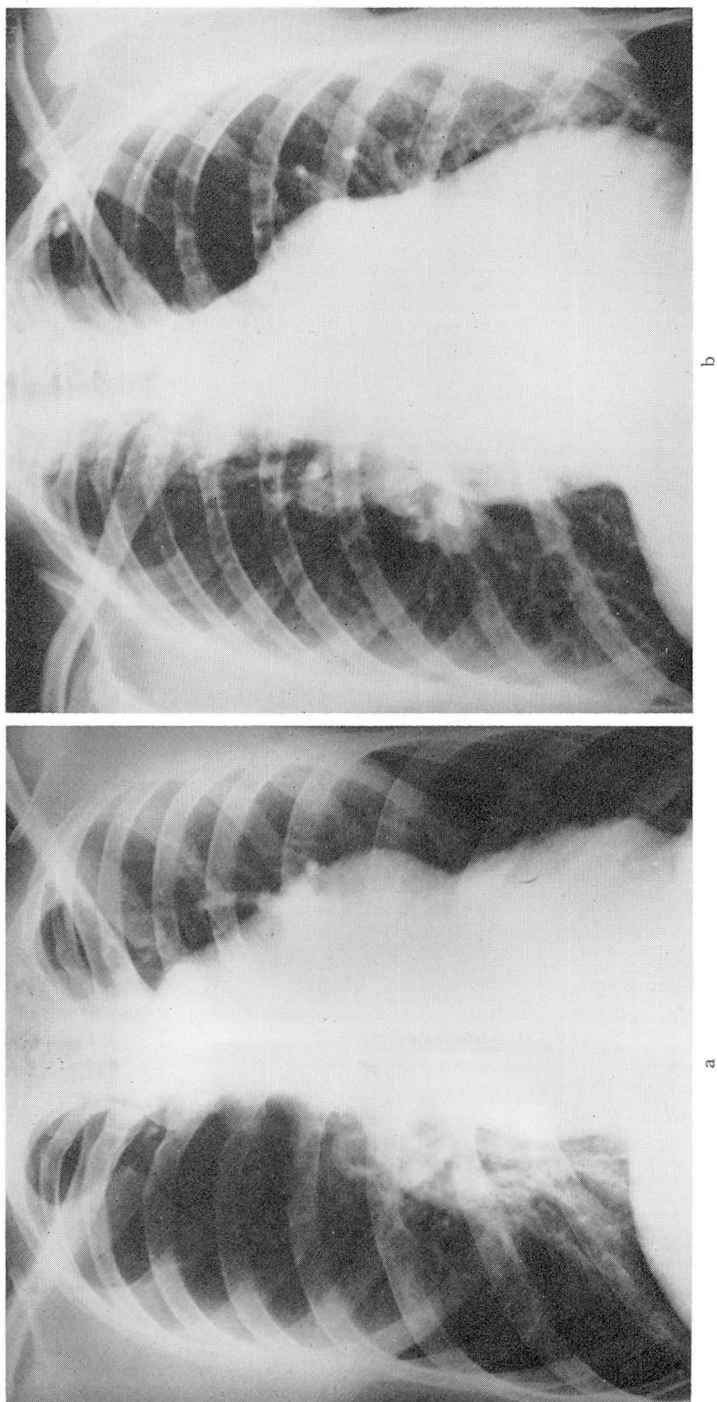


Fig. 1. The two roentgenograms demonstrate the degree of aneurysmal enlargement which can occur in response to pulmonary hypertension. (a) The roentgenogram of the chest of the patient in whom the operation terminated in fatal hemorrhage. (b) The roentgenogram of the chest of the patient in whom hypotension was first utilized. Note the generalized increase in pulmonary vascular markings in addition to the aneurysmal enlargement of the pulmonary artery.

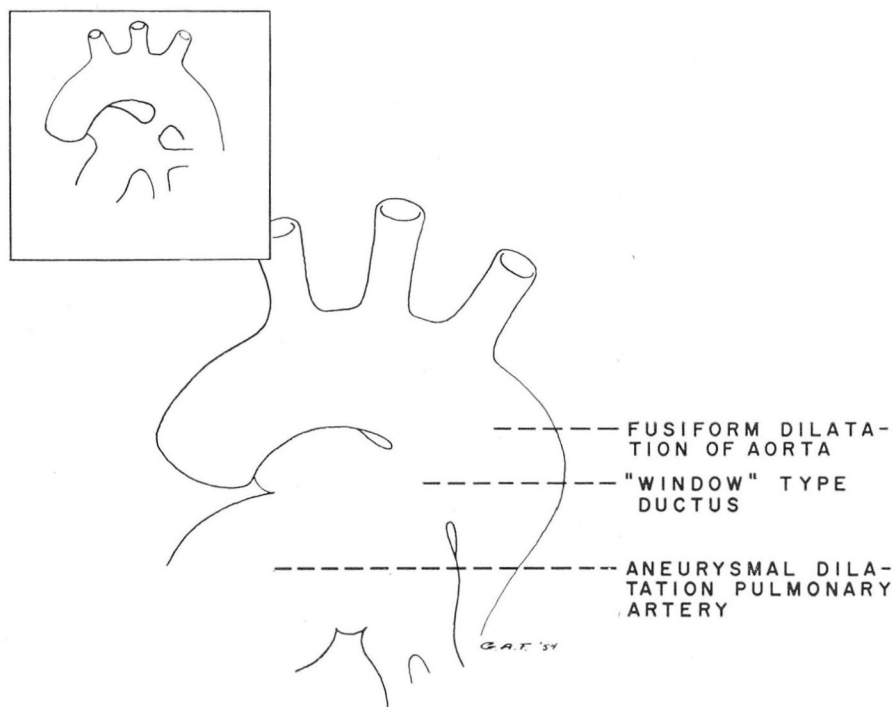


Fig. 2. (Case 1) Diagrammatic representation of the anatomic finding in case 1. Attempting to occlude this type of ductus by ligature obviously would be hazardous. Tying down a ligature about this type of ductus puts undue traction on the parent vessels and is apt to cause a tear. This is in contrast to the usual finding depicted in the inset where ligation or division is relatively simple.

induced. With the removal of 1200 cc. of blood, the pressure was reduced from 100 mm. Hg systolic to 68 mm. Hg. There was no resultant tachycardia and her general condition seemed satisfactory without overt signs of oligemic shock. Considerable softening of the involved vessels was immediately apparent and the pulmonary artery was definitely decreased in size. Mobilization of the ductus was then completed. It was clamped, divided, and closed in the usual manner without difficulty. Following closure of the ductus most of the withdrawn blood was reinfused. At the conclusion of the operative procedure the pressure was stable at 90 mm. Hg systolic. The patient had an uneventful postoperative course.

Case 2. The patient was a 19 year old white woman. Approximately two years previously she had had simple ligation of a patent ductus and within six months there were signs of recanalization. At operation there was marked thickening of the pleura about the great vessels and it was extremely difficult to develop tissue planes in the vicinity of the ductus. The risk of serious hemorrhage seemed greatly increased. Controlled hypotension was induced by withdrawal of 1100 cc. of blood with a fall of systolic pressure from 120 mm. Hg to 70 mm. Hg. There was a prompt softening of the vessels and an apparent increase in pliability. Dissection was then completed without difficulty and the aortic end of the ductus was clamped with a large Potts-Smith type of clamp.

The ductus was divided and the ends were sutured without difficulty. Sufficient blood was reinfused to elevate the systolic pressure to 115 mm. Hg at the close of the procedure, and the patient had an uncomplicated postoperative course.

Case 3. An 18 year old white man was diagnosed as having a large patent ductus. At operation, a window-type ductus, 1.5 cm. in diameter, was encountered. There was some pleural reaction overlying the ductus, and plaques were palpable in its wall. It was also evident that there was increased pressure in the pulmonary artery. For these reasons, the systolic pressure was reduced from 130 mm. Hg to 90 mm. Hg by removal of 400 cc. of blood; subsequently, removal of an additional 250 cc. was necessary to maintain the hypotension. A considerable improvement in the texture and softness of the great vessels resulted, and they were readily mobilized. The ductus was clamped, divided, and the ends were closed without incident. Blood pressure was returned to 110 mm. Hg systolic by reinfusion of blood. The patient had an uneventful postoperative convalescence.

Case 4. A 10 year old white girl was found at operation to have a short ductus, 1 cm. in diameter, with associated fusiform dilatation of the aorta and early aneurysmal changes in the pulmonary artery. During mobilization of the aorta, it was noted that the ductus appeared to have undergone significant degenerative changes. Therefore, 200 cc. of blood was removed from the radial artery causing a fall in blood pressure from 110 mm. Hg systolic to 80 mm. Hg. Subsequently, it was necessary to remove several additional quantities of blood, which totaled 175 cc., to maintain the hypotension between 70 and 80 mm. Hg systolic. Mobilization was then readily completed; however, during the division, the Potts ductus clamp became dislodged from the pulmonary end of the ductus. It proved to be no problem to occlude the opening with Allis clamps and then to suture it. There were no postoperative complications.

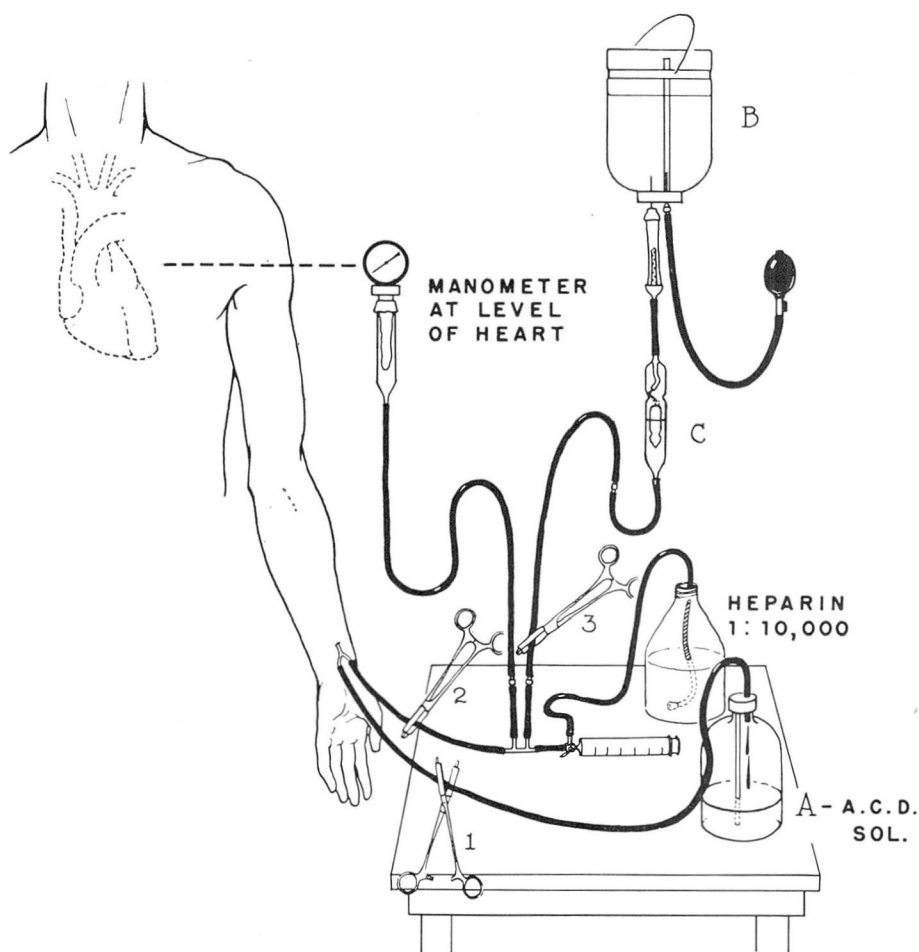
TECHNIC

During operation, hypotension is induced by withdrawal of blood from a radial artery. The cut down and arteriotomy need not be performed until the need for hypotension is ascertained during exposure of the ductus. The necessary equipment is kept in a sterile kit and is immediately available (fig. 3). The blood is collected under aseptic conditions in the usual transfusion bottles containing A.C.D. solution. The blood pressure can be measured directly by an aneroid manometer connected with the system. This permits a continuous check on the blood pressure and additional blood can be withdrawn or reinfused as indicated. Heparin is intermittently infused into the system to prevent clotting. It is important to establish limits of time and degree of hypotension to add to the safety of the procedure. We strive to keep systolic pressure above 70 mm. Hg and to utilize this degree of hypotension for no more than 30 minutes. When the need for hypotension has passed, the appropriate amount of blood to restore a safe blood pressure is reinfused. In each of the cases described above some surplus blood was banked for possible future use.

PHYSIOLOGIC CONSIDERATIONS

Bleeding will not induce hypotension until the discrepancy between the capacity of the vascular system and the blood volume has exceeded the limits

of the various compensatory mechanisms. It is likely that these compensatory mechanisms are depressed by anesthesia so that a drop in blood pressure results from a smaller blood loss in the anesthetized patient. It has been impressive to us that these patients under anesthesia have not developed the marked tachycardia, weak pulse, and sweating, signs ordinarily associated with oligemic shock. It may be thought that arteriotomy induces oligemic shock. Our experience indicates that it does not. Hypotension, if severe and of long duration,



(By permission of SURGERY, GYNECOLOGY AND OBSTETRICS.³)

Fig. 3. Setup for arteriotomy bleeding. Blood is withdrawn by opening clamp 1. When clamp 2 is opened the arterial blood pressure is continually recorded by the manometer. Clamp 3 is opened only when blood is being reinfused from bottle (B). The MacIntosh drip (C) precludes the possibility of air entering the arterial tree. Heparin is added to the system intermittently to preclude clotting.

may be a precursor of shock, but it is not synonymous with it. Shock is prevented during induced hypotension by careful control of the level of the blood pressure and by limiting the length of time that it is depressed. In our group of patients, maximal hypotension has been utilized for only 15 to 30 minutes and then it is rapidly reversed by reinfusion of blood. Also, 70 to 80 mm. Hg systolic has been set as an arbitrary lower limit for blood pressure. Pressure levels below this limit are counteracted by blood replacement. There have been no detectable changes in any body systems following this procedure. We are unprepared to state whether a typical shock syndrome would ensue if the hypotension was prolonged, but it seems reasonable that it would. The patient in shock from hemorrhage of any source will usually manifest hypotension as the only sign for a significant period early in the development of the syndrome.

SUMMARY AND CONCLUSIONS

Hypotension induced by arteriotomy bleeding during surgery has been used in four cases of complicated patent ductus arteriosus. We believe that this technic is of considerable value in simplifying the operative procedure and in reducing the hazard of uncontrolled blood loss. The use of this technic brings about very significant softening and increase in pliability of the involved blood vessels. There were no postoperative complications of any kind in the four cases in which the technic was utilized. It should be stressed that a time limit of 30 minutes and a low pressure limit of 70 mm. Hg systolic are considered to be important safety factors when the technic is used.

References

1. Gardner, W. J.: The control of bleeding during operation by induced hypotension. *J.A.M.A.* **132**: 572-574 (Nov.) 1946.
2. Hale, D. E.: Controlled hypotension by arterial bleeding during operation and anesthesia. *Anesthesiology* **9**: 498-505 (Sept.) 1948.
3. Gardner, W. J. and Ling, A.: Controlled hypotension by the bleeding method in operations for intracranial meningiomas. *Surg., Gynec. & Obst.* **98**: 343-346 (March) 1954.
4. Glenn, W. W. L., Hampton, L. J. and Goodyer, A. V. N.: Use of controlled hypotension in large blood vessel surgery. *A.M.A. Arch. Surg.* **68**: 1-6 (Jan.) 1954.