

# MANAGEMENT OF CONTINUOUS SPINAL ANESTHESIA FOR GERIATRIC SURGERY

CARL E. WASMUTH, M.D. and GAETANO RONCAGLI, M.D.

Department of Anesthesiology

**S**URGERY is considered in aged patients only when pathologic conditions supervene upon the involutionary changes that normally result from advancing years. Aged patients are classified as poor surgical risks because aging narrows the limits of physiologic response and increases the danger of surgery and anesthesia.

In selecting anesthesia for the aged patient, the status of his respiratory and circulatory systems must be carefully evaluated. The heart may be unable to withstand unusual stress, as simple atrophy of the heart and degenerative changes of the coronary vessels often are present.<sup>1</sup> Arteriosclerotic changes in the coronary and cerebral vessels form the groundwork for potentially catastrophic events should the blood pressure be allowed to fall precipitously and should it remain at hypotensive levels for any considerable time.\* Hypotension is predisposed to by loss of elasticity of the peripheral vessels which impairs the rapid compensatory vasoconstrictor response to blood loss.

Spinal anesthesia by the continuous catheter technic provides safe anesthesia for operations in the abdomen, pelvis, and lower extremities of patients who are poor surgical risks. The indwelling catheter permits small and repeated injections of the anesthetic agents, thereby permitting the dosage to be adjusted specifically to each patient. With a segmental type of anesthesia<sup>2</sup> using minimal amounts of anesthetic agent, the surgeon operates under ideal surgical conditions, and little if any hypotensive effect of the anesthetic is noted. The patient is awake and cooperative; therefore, the protective reflexes are not disturbed. The small doses of anesthetic agent injected make it possible to terminate the anesthesia within a brief period simply by withholding further administrations. Severe hypotension, which rarely occurs, is treated with appropriate vasoconstrictor drugs. Continuous spinal anesthesia is therefore an appropriate technic for the poor-risk aged patient.

## Physiology

Injection of 1 cc. of a 1 per cent (10 mg.) procaine solution within the intrathecal space is followed by blocking of all the components of the nerve roots, including sympathetic, somatic and motor, in the immediate vicinity of the tip of the catheter. The concentration decreases as the procaine diffuses up and down the spinal canal. Sensory and sympathetic blocks extend three to four segments, and motor paralysis extends two or three segments in either direction. The sympathetic nerve root block is negated somewhat by the fact

\* A fall in mean pressure greater than 25 per cent should not go uncorrected.

that each ganglion inosculates via the sympathetic chain with two or three ganglia cephalad. Consequently, little if any hypotension is effected in this segmental type of continuous spinal anesthesia, and ideal safe operating conditions are presented.

### Premedication

Premedications for the aged and poor-risk surgical patients are individually prescribed through consideration of each patient's general condition, temperament, age, and weight. Any deficiencies in premedication can be easily corrected in the operating room by the anesthesiologist. In most cases, morphine and atropine are suitable drugs. Demerol is preferred by some anesthesiologists who consider that it has less tendency to suppress respirations than does morphine. Actually, the depressant respiratory qualities of both drugs are about equal, and demerol is deficient in psychic sedation.

Atropine is preferred to hyoscine or scopolamine, as the latter drugs often cause hallucinations and delusions in the aged.

Barbiturates are not used for premedication. Older patients are usually adapted better mentally and they approach surgery with little apprehension. Sedation as a safeguard against possible undue excitement is usually unnecessary and sometimes dangerous.

### Spinal Technic

The spinal catheter is inserted through a Tuohy needle. The patient is placed in the lateral recumbent position with the legs flexed upon the abdomen as acutely as is physically possible. In the aged, the ideal position for spinal puncture is seldom attained. In case of injuries to the bones of the lower extremities, it is frequently impossible to move the patient to any great extent and seldom can he be moved from bed. The skin of the back is prepared with an antiseptic solution. A syringe equipped with a 24-gauge needle and containing 2 cc. of a 1 per cent procaine solution is used to raise a cutaneous wheal at the site of intended puncture. Ephedrine is eliminated from the local skin wheal to prevent a hypertensive state.

A 3½-inch, 16-gauge, Tuohy needle is inserted into the dural sac between L<sub>2</sub> and L<sub>3</sub>. An attempt is made to introduce the needle at an angle of 45 degrees with the plane of the skin (fig. 1); this is frequently impossible in the aged. Bony changes and limited flexion may necessitate the use of the lateral approach for lumbar puncture. If the cerebrospinal fluid does not flow briskly when the stylet is removed, the needle should be turned on its axis through 360 degrees and gently advanced. Such manipulation causes the entire bevel of the needle to enter the subarachnoid space. The needle at this time is at an angle of approximately 25 to 45 degrees from the perpendicular with the skin and the bevel is directed cephalad. The plastic tubing (B-D No. 442T) is inserted. This angle, assisted by the internal curvature of the Huber point of the needle, causes the catheter to seek a cephalad direction in the intrathecal space.

If an obstruction is felt at the tip, the needle is turned 45 degrees in either direction and is then withdrawn a few millimeters until the catheter enters the intrathecal space. When the catheter is correctly placed, spinal fluid can be withdrawn by gentle aspiration with the 2 cc. syringe. Irrespective of site of operation or levels of anesthesia needed, the tubing should be inserted at least 5 cm. within the intrathecal space. For operation in the upper abdomen the catheter is inserted as far as 15 cm. When at the selected level, the needle is removed and the catheter is anchored to the skin at the site of lumbar puncture by adhesive tape. An adapter connects the plastic tube to a syringe (10 cc.) containing the anesthetic agent.

If any paresthesias are elicited while inserting the catheter, turning the needle through 45 degrees or twisting the catheter may carry the tip away from the nerve root and will permit the advance up the subarachnoid space. If paresthesias persist, further advancement must be abandoned and a seg-

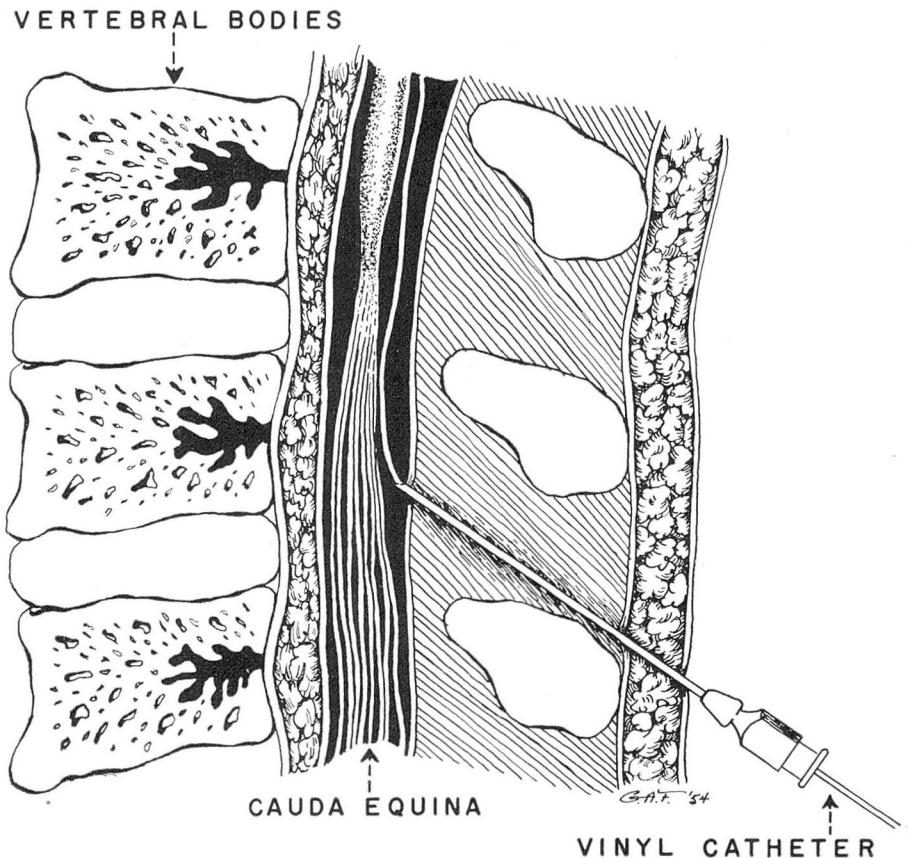


Fig. 1. A  $3\frac{1}{2}$ -inch, 16-gauge, Tuohy needle is inserted into the dural sac between L<sub>2</sub> and L<sub>3</sub>. An attempt is made to introduce the needle at an angle of 45 degrees with the plane of the skin.

mental type of anesthesia sacrificed. After the needle is removed but before the anesthetic agent is injected, slight withdrawal of the catheter prevents deposition of the anesthetic drug within a nerve sheath. The catheter never should be withdrawn through the needle,<sup>3</sup> since the needle's sharp edge may cut it off.

### Intravenous Technic

Venoclysis is begun through an appropriate arm vein after the patient arrives in the operating room. A 15-gauge needle is preferable so that in case of hemorrhage, blood volume can be rapidly restored. The arm is held in the abducted position to be available for inspection and emergencies; however, care should be taken to prevent stretching the brachial plexus.

When a need for intravenous therapy during the postoperative care of the patient is anticipated, a plastic tubing may be substituted for the indwelling needle, since the tubing can be left in place for several days. Polyethylene tubing is nonirritating to the intima of the vein and the flexibility of the tubing allows free motion of the extremity. In the postoperative period the patient can assume many positions that would be denied him by an indwelling intravenous needle (fig. 2).

### Administration of Spinal Anesthetic Solution

Procaine hydrochloride crystals (100 mg.) and pontocaine HCl (10 mg.) are diluted to 10 cc. with normal saline solution. Both of these agents have low coefficients of toxicity. The action of procaine alone is transient. Although pontocaine becomes effective slowly, its effect is prolonged.<sup>4</sup> This solution is considered approximately isobaric and is administered in units of 1 cc. If injection is made as slowly as possible, the jetlike stream that would be caused by forceful injection is avoided and the solution pools at the tip of the catheter. Anesthesia then is limited to a few segments of the spinal cord in either direction and does not diffuse up or down the spinal canal. One cc. (10 mg. procaine and 1 mg. pontocaine) constitutes the initial dose. Additional quantities of agent may be necessary to establish surgical anesthesia. However, for the aged patient the single initial injection frequently is sufficient not only to establish anesthesia but to maintain it for the whole operation.<sup>5</sup> Continuous spinal anesthesia, then, is not only practicable for longer operations, but the fractional-dose technic makes it particularly suitable for the aged and poor-risk patients. The advantage over classic single-injection spinal anesthesia is obvious.

Additional solution is administered only when indicated. The signs of waning anesthesia in a patient are loss of relaxation, restlessness, and finally evidence of discomfort. As these signs appear, an additional cubic centimeter of the anesthetic solution (10 mg. procaine and 1 mg. pontocaine) is injected. Maintenance doses are usually smaller than that dose which was necessary to initiate anesthesia,<sup>6</sup> and their action is usually more prolonged.

**Lower Abdomen.** Continuous spinal anesthesia lends itself well to surgery of the lower abdomen. If the lumbar puncture is made at L<sub>2</sub> to L<sub>3</sub> and the

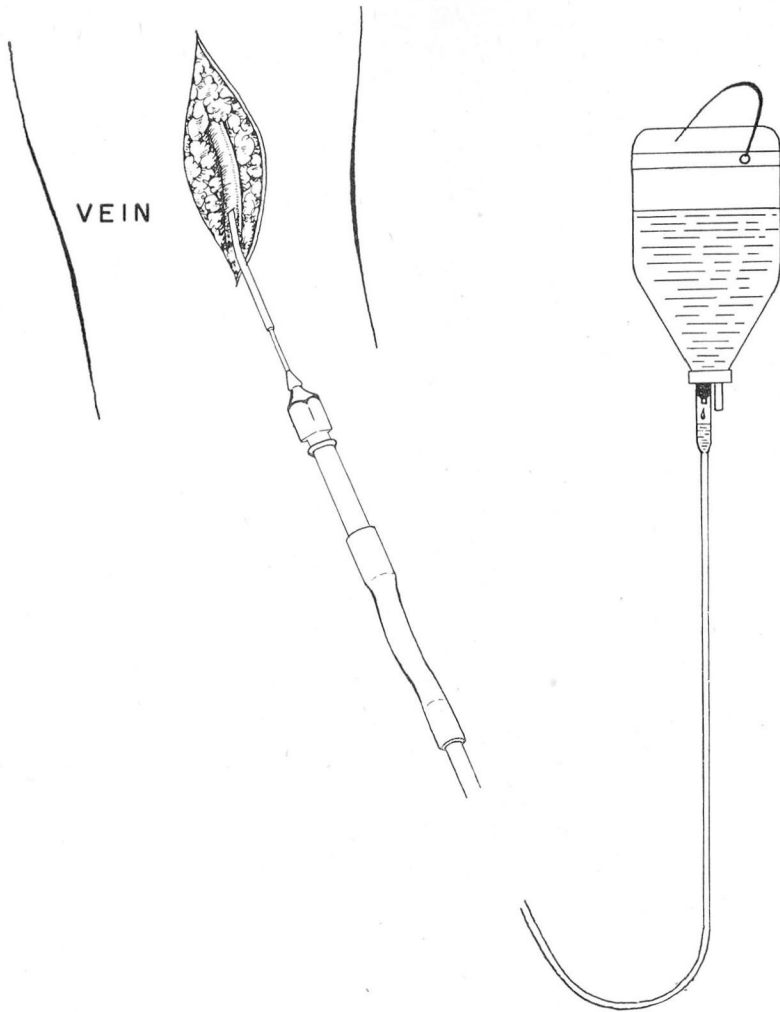


Fig. 2. Short length (5 inches) of polyethylene tubing size No. 190 is introduced into the vein through a cut down. Adaptation of the tubing to the venoclysis set is accomplished by an 18-gauge blunt cannula.

catheter threaded into the subarachnoid space for 5 cm., the area of sensory anesthesia is approximately  $T_8$  to  $L_3$ . This segmental type of anesthesia permits operations in the lower abdomen but avoids loss of motor control of the legs. The hypotension so often seen in classic single-injection spinal anesthesia is absent. Relaxation of the anterior abdominal wall is adequate and analgesia is confined within the segmental limits.

Occasionally when the patient is placed in the lithotomy position as in a combined abdomino-perineal resection, the head of the table is tilted down,

Perineal anesthesia in this instance is obtained by using a hypobaric solution of pontocaine (10 mg.) in distilled water (10 cc.). Such a solution, being lighter than spinal fluid, will flow caudad to anesthetize the cauda equina.

**Upper Abdomen.** For ease of surgical manipulations in the upper abdomen, the catheter is threaded up the intrathecal space from 10 to 15 cm. and the level of anesthesia made to extend from T<sub>5</sub> to T<sub>10</sub>. If care is taken to inject the solution slowly, a pooling of the agent will occur and delineation of the sensory component will be sharp. The sympathetic effect therefore is limited only to a few segments, because of the overlapping of the innervation in the sympathetic ganglia.<sup>7</sup> The hypotension which is usually pronounced in single-injection high spinal anesthesia either does not occur with this technic<sup>4</sup> or is slight and responds readily to vasopressors. The maintenance of tone in the leg muscles by absence of low motor anesthesia also prevents much of the hypotension seen in classic high spinal anesthesia. Nervous control of the skeletal muscles of the leg is lost only when the spinal agent is injected rapidly and in amounts larger than 1 cc. Complete sympathetic denervation is then accomplished and the hypotension which follows may be severe.

### Supplementary Agents

Administration of additional agents is avoided if at all possible. The barbiturates are sometimes used to supplement spinal anesthesia. However, most of the aged patients enter the operating room calmly and peacefully. They seldom need additional narcosis. Pentothal is sometimes administered to control nausea, vomiting, and the discomfort of mesenteric traction. Bantnine (50 to 100 mg.) controls the vomiting caused by intestinal manipulations, but it does not relieve the discomforts resulting from mesenteric traction. Nembutal subdues an excited patient more slowly but its action is much longer than that of pentothal; with either agent, dosages that may cause the patient to lose consciousness should not be administered.

### SERIES

This series of 261 cases includes patients in the age range from 60 to 93 years (table 1). The operations performed ranged from abdominal and kidney

**TABLE 1**  
**Age Distribution of Patients**

Age Range (yr.)	No. of Patients	Per Cent
60—70 . . . . .	180	68
70—80 . . . . .	75	30
80—90+ . . . . .	6	2
<b>TOTAL . . . . .</b>	<b>261</b>	



operations to those on the lower extremities (table 2, a). Many of these patients (39 per cent) were considered poor surgical risks because of the presence of a disease in addition to that requiring surgery (table 2, b). Whenever possible a segmental type of continuous spinal anesthesia was attempted on this group. The results of the use of this type of high spinal anesthesia (71 cases) for surgery of the stomach and biliary system are particularly interesting (table 3). A segmental type of anesthesia from T<sub>5</sub> to T<sub>10</sub> was attempted. Traction upon the stomach and esophagus caused nausea, vomiting, and discomfort that were not relieved by procaine infiltration of the vagus nerves. Banthine (50 to 100 mg. intravenously) allayed the nausea and vomiting that the patients experienced during manipulation in surgery of the biliary tract. In most instances, hypotension, if it appeared, was transitory, and not alarming. In all cases, it was easily corrected by the intravenous injection of neosynephrine in a dilution of

**TABLE 2**  
**Summary of 261 Cases**

a. Site of Operation	No. of Cases	
Upper abdomen . . . . .	71	
Lower abdomen . . . . .	52	
Colon . . . . .	98	
Lower extremity . . . . .	36	
Kidney . . . . .	3	
Hypotensive spinal . . . . .	1	
<b>TOTAL</b> . . . . .	<b>261</b>	
<b>b. Risk</b>	<b>No. of Cases</b>	<b>Per Cent</b>
Good . . . . .	81	31
Increased . . . . .	101	39
Unclassified . . . . .	79	30
<b>TOTAL</b> . . . . .	<b>261</b>	
<b>c. Anesthetic Complications</b>	<b>No. of Cases</b>	
Nausea and vomiting . . . . .	21	
Hypotension . . . . .	6	
Spinal failure . . . . .	6	
<b>TOTAL</b> . . . . .	<b>33</b>	
<b>d. Postanesthetic Complications</b>	<b>No. of Cases</b>	
Pulmonary complication . . . . .	6	
Headache . . . . .	26	
Nausea and vomiting . . . . .	1	
Mesenteric thrombosis . . . . .	1	
Hypotension . . . . .	2	
Cerebral vascular accident . . . . .	1	
Transfusion reaction . . . . .	1	
Death . . . . .	6	
<b>TOTAL</b> . . . . .	<b>44</b>	

**TABLE 3**  
**Upper Abdominal Operations**  
**(Summary of 71 Cases)**

a. Type of Operation	No. of Cases	
Gallbladder and common duct . . . . .	33	
Cholecystojejunostomy . . . . .	3	
Abdominal exploration . . . . .	12	
Gastric resection . . . . .	10	
Gastroenterostomy . . . . .	6	
Subdiaphragmatic abscess . . . . .	1	
Pancreatic resection . . . . .	3	
Duodenal resection . . . . .	1	
Jejunal resection . . . . .	2	
<b>TOTAL</b> . . . . .	<b>71</b>	
<b>b. Postoperative Complications</b>	<b>No. of Cases</b>	<b>Per Cent</b>
Pulmonary . . . . .	2	3
Mental or cerebral . . . . .	1	1.5
Cardiac vascular . . . . .	2	3
Gastrointestinal . . . . .	1	1.5
Death . . . . .	0	0
<b>TOTAL</b> . . . . .	<b>6</b>	
<b>c. Anesthesia—Risk</b>	<b>No. of Cases</b>	<b>Per Cent</b>
Good . . . . .	21	30
Increased . . . . .	36	50
Unclassified . . . . .	14	20
<b>TOTAL</b> . . . . .	<b>71</b>	

0.2 cc. of a 1.0 per cent solution in 500 cc. glucose 5 per cent in water. The solution is permitted to flow rapidly (80 drops/min.).

Operations on lower extremities were most frequently for gangrene or fracture. In either case, the spinal catheter was inserted while the patient was still in bed. He was turned on the affected side for the insertion of the catheter and remained in this position while the initial dose was injected. Ten minutes was allowed to elapse for the spinal anesthesia to become fixed. With this analgesia, the patient was moved to the table and the manipulations of the extremity were painless.

In this series of 261 aged patients, there were no deaths attributable to the anesthesia. Six patients died within the first ten postoperative days (table 2, d).

The incidence of postspinal headache was low (10 per cent) probably because many of the patients classified as poor risks were unable to be ambulated and for that reason did not experience headaches.

The following two case reports are presented to illustrate the use of continuous spinal anesthesia for upper abdominal surgery in patients who are extremely ill.



### Case Reports

**Case 1.** An 80 year old white man was admitted to the hospital on January 16, 1952, with a history of gastric ulcer since 1949. Physical examination revealed extreme cachexia, advanced arteriosclerosis, a blood pressure of 190/88, and a grade II systolic murmur.

On January 21, five days after admission, a gastric resection was performed under continuous spinal anesthesia. Premedication consisted of morphine 1/6 gr., atropine 1/150 gr. A plastic catheter was inserted 12 cm. cephalad from the third lumbar interspace in the subarachnoid space. After the surgical field had been completely draped, 1 cc. of a solution of pontocaine (1 mg.) was injected. Initial blood pressure was 190/88. The lowest pressure level was 156/84. The pulse rate ranged from 80 to 64 per minute.

The level of anesthesia was segmental and extended from T<sub>3</sub> to T<sub>10</sub>. Sensory and motor control of the legs were unaffected. A total of 7 cc. of anesthetic solution was used over a period of three hours. Nembutal (50 mg. intravenously) was the only supplementary agent used.

The patient was discharged 14 days postoperatively after a relatively uneventful course.

**Case 2.** A 66 year old white woman was admitted in May 1952 for exploration of the common duct. Eight weeks previously she had become jaundiced. In 1944 she had been found to be diabetic; in 1943 she was found to have angina pectoris; and in 1950 she suffered a coronary occlusion.

Exploration of the common duct was carried out on May 20, 1952, under continuous spinal anesthesia. An indwelling plastic catheter permitted fractional dose injections of spinal anesthetic agents into the subarachnoid space at approximately 20 to 25 minute intervals. The solution of procaine (100 mg.) and pontocaine (10 mg.) in 10 cc. dextrose (5 per cent) was utilized. The initial injection of 2 cc. (procaine 20 mg. and pontocaine 2 mg.) caused an initial fall in blood pressure from 140/80 to 100/60 which was immediately corrected by neosynephrine drip (2.0 mg. in 500 cc. dextrose 5 per cent). The entire operation lasted 2¼ hours and required 7 cc. of anesthetic solution (70 mg. procaine and 7 mg. pontocaine).

The catheter was inserted 8 cm. from L<sub>2</sub>. The upper level of sensory loss was at T<sub>4</sub> and the lower level was approximately at T<sub>12</sub>. The patient could move her legs throughout the course of surgery.

The postoperative period was uncomplicated and the patient was discharged on the twelfth postoperative day.

### Comment

The advantages of continuous spinal anesthesia are immediately apparent when the physiology and management of the anesthesia are thoroughly examined. Segmental areas of analgesia are produced by placing the tip of the catheter at the proper level and injecting small amounts of anesthetic agents. A narrow band of anesthesia is produced. The sympathetic denervation is minimal because the inosculating fibers in the ganglia reach to unaffected higher levels.

The disadvantages of continuous spinal anesthesia in the aged are: the difficulty of making the lumbar puncture, and possible danger of nerve trauma, and hemorrhage in the subarachnoid space. Not only are the lumbar punctures difficult to make as a result of vertebral bony changes but the patient frequently

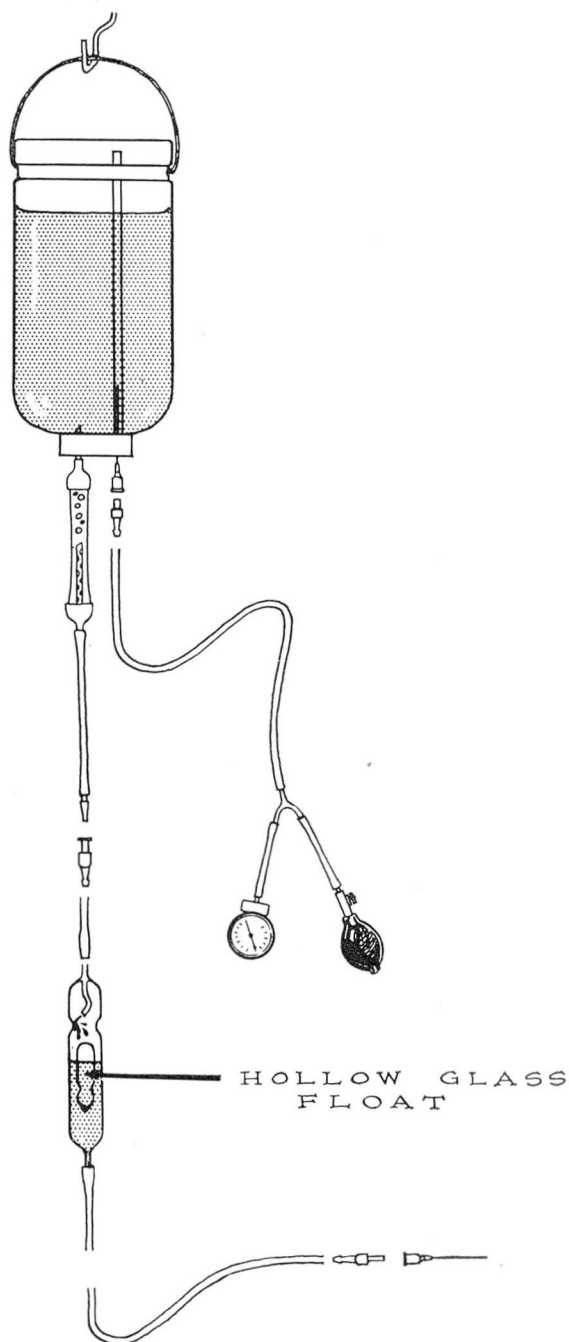


Fig. 3. Pressure infusion setup fitted to the 15-gauge needle to prevent air embolism.

cannot flex his legs upon the abdomen or cannot be removed from bed. The combination of all these factors sometimes forces the anesthesiologist to utilize the lateral approach.

Injury to the nerve roots is avoided by carefully threading the catheter to the desired level. The anesthetic agent must never be injected just after a paresthesia is elicited because the tip of the catheter may lie in the sheath of a nerve root. Spinal anesthetic agents if deposited within this covering may cause additional irritation to an already traumatized nerve.

The maintenance of anesthesia is accomplished by periodic injection of 1 cc. of mixture of the agent. The intervals between injections vary with each patient but not with age, weight, or sex.

The institution of a continuous spinal anesthesia in a patient who is desperately ill and in shock often brings about a noticeable improvement in his condition. Discomfort and pain are relieved and the patient frequently falls asleep from exhaustion. Limbs that were previously cold and clammy become warm and dry. The desperately ill patient appears to be in an improved state even before surgery is performed.

In the event of severe hemorrhage, when the replacement of blood loss is mandatory, pressure within the infusion bottle is sometimes necessary for the rapid transfusion of blood. Rather than risk the chance of air embolism, a pressure infusion setup (fig. 3) is fitted to the 15-gauge indwelling intravenous needle. Pressures (200 to 300 mm. Hg) sufficient to infuse the blood rapidly are applied. When the supply of blood in the bottle becomes exhausted, the air pressure still present is prevented from entering the blood stream by the MacIntosh safety dropper (modified by Hale). The float settles firmly into the ground-glass seat and seals the valve to prevent the passage of air. Such a setup allows the anesthetist confidently to turn his attention to other pressing matters in this critical period.

## CONCLUSIONS

1. For the aged patient who is a poor surgical risk, a segmental type of continuous spinal anesthesia is appropriate because it offers a band of sensory anesthesia at the site of incision, profound relaxation of the musculature, and minimal interference with the sympathetic nerves. The absence of profound blood pressure changes in high continuous spinal anesthesia is attributable to the segmental type of analgesia provided and to the special anatomy of the fibers extending up the sympathetic chain.

2. The plastic-catheter technic is recommended because it allows the anesthetic agent to be deposited at any preselected level of the subarachnoid space.

3. A series of 261 cases is reviewed which includes patients operated upon at ages ranging from 60 to 93 years. Thirty nine per cent of these patients were considered poor surgical risks. Whenever possible a segmental type of continuous spinal anesthesia was attempted in this latter group. Of the six postoperative deaths, none was attributable to the anesthesia.

**References**

1. Steiglitz, E. J., editor: *Geriatric Medicine*, Philadelphia and London, W. B. Saunders Co., 1943.
2. Saklad, M. and others: Intraspinial segmental anesthesia; preliminary report. *Anesthesiology* **8**: 270-287 (May) 1947.
3. Cann, J. E. and Wycoff, C. E.: Continuous spinal anesthesia; modification of ureteral catheter technic. *Anesthesiology* **9**: 288-295 (May) 1948.
4. Ansbro, F. P. and Pico, L. J.: Continuous spinal anesthesia; report of 100 cases in which this method was employed. *Am. J. Surg.* **55**:504-508 (March) 1942.
5. Wasmuth, C. E. and Hale, D. E.: Continuous spinal anesthesia in poor risk and aged surgical patient. *Cleveland Clin. Quart.* **18**:93-97 (April) 1951.
6. Nicholson, M. J., Eversole, U. H. and Hand, L. V.: Fractional spinal anesthesia. *Am. J. Surg.* **53**:403-411 (Sept.) 1941.
7. Kuntz, Albert: *Autonomic Nervous System*, ed. 4, Philadelphia, Lea & Febiger, 1953.