

## ROENTGENOGRAPHIC DIAGNOSIS OF ACOUSTIC NERVE TUMOR

CHARLES M. GREENWALD, M.D.\* and CHARLES C. WHITSETT, M.D.\*\*

Department of Roentgenology

THE diagnosis of acoustic nerve tumor is based primarily upon the results of clinical examination; roentgenographic examination serves as a secondary diagnostic aid. This lesion is not uncommon, constituting approximately 9 per cent of all brain tumors.

The tumor is found attached to the eighth cranial nerve and lies in the angle between the cerebellum and the brain stem. The direction of growth is variable; a tumor may grow quite large without appreciably involving the petrous apex or extending into the acoustic meatus. By contrast, it may weigh only a few grams with most of its mass within the meatus, causing marked erosion. Although initially it was postulated that the tumor arose solely from the vestibular branch,<sup>1</sup> now it is known that either the vestibular or the cochlear branch of the eighth nerve may be the site of origin.<sup>2</sup> Acoustic nerve tumors have been reported in the literature to be of two basic histologic types.<sup>3</sup> Most of them are considered to be neurinomas (neurilemoma, perineural fibroblastoma); in these, the nerve fibers are confined to the capsule of the tumor mass with no fibers present within the lesion. A small percentage are neurofibromas with nerve fibrils coursing through the tumor. The latter are reported as occurring with von Recklinghausen's disease;<sup>4</sup> they tend to be bilateral and familial,<sup>5</sup> and may be associated with a meningioma.<sup>6,7</sup> All of the acoustic tumors in this series were reported as neurilemmomas or neurinomas, including two cases with von Recklinghausen's neurofibromatosis peripherally. It seems definite that there is an increased incidence of acoustic tumor in cases of neurofibromatosis. However, tissue from these central lesions apparently shows no significant histologic differences from that of any other acoustic nerve tumor.<sup>8</sup>

Although there are exceptions, symptoms tend to divide themselves into three phases.<sup>9</sup> These in general reflect the increase in size of the lesion. In the first phase, there is local involvement of the eighth nerve, followed by involvement of the fifth and seventh cranial nerves. In the second phase, with further tumor growth, the cerebellum and the ninth, tenth, and eleventh cranial nerves are also involved. Symptoms of increased intracranial pressure due to blockage of the aqueduct of Sylvius occur late, and represent the final phase.

In a considerable proportion of cases no definite changes are apparent on roentgenographic examination, plain films of the skull being entirely negative

\*Fellow in the Department of Roentgenology.

\*\*Former staff member. Now Radiologist at Robinson Memorial Hospital, Ravenna, Ohio.

or showing such minimal variation in the petrous apices and acoustic meati that they are within the range of normal. In detecting those cases with roentgenographically demonstrable lesions, close scrutiny is required because the changes are usually inconspicuous. Diminished bony density around the meatus caused by local erosion with a sharp line of demarcation between the involved area and normal bone may be the only findings (fig. 2). Extensive bony destruction with a gross defect in the petrous apex occurs in only the minority of cases (fig. 4). The reported accuracy of diagnosis by roentgenographic examination varies considerably. Dyke<sup>10</sup> states that about 50 per cent of cases will have sufficient demineralization and erosion to be visible on roentgenograms; this appears to be a reasonable average. Percentages as high as 84 and 90 have been reported by Hodes, Pendergrass and Young,<sup>11</sup> and by Lysholm.<sup>12</sup>

### SERIES

The purpose of this article is to review the roentgenographic evidence in those surgically proved cases of acoustic nerve tumor which were observed at the Cleveland Clinic from 1946 to 1952. Of 43 such cases during this period, films were available for study in 36. In most of these 36 cases a tentative diagnosis of acoustic neuroma had been made prior to the time of roentgenographic examination. In the remainder, some type of posterior fossa growth was under consideration. Seventy-five per cent of the patients were women (27 women and 9 men). The lesion was located on the right in 19 cases and on the left in 16. The only instance of bilateral acoustic tumor in this series occurred in a 20 year old woman who had had von Recklinghausen's disease since early childhood. She had, in addition, a sphenoid ridge meningioma. The average age on admission was 46 years. Four of the patients, all women, were in their twenties and the oldest patient was 70 years of age. These figures are in general agreement with those reported for other larger series by Cushing<sup>4</sup> and Gonzales Revilla;<sup>8</sup> that is, the tumor is more common in women, and more patients present themselves for surgery in their early forties than at any other age.

A routine series of roentgenograms of the skull which consisted of stereoscopic right laterals, posterior-anterior, and occipital views were obtained of all patients. Of the 36, 24 had in addition a basilar view, and 22 had a Stenver's view. The changes observed on plain films can be divided into two main categories: (1) local changes in the petrous bone in the region of the lesion, and (2) nonspecific changes due to increased intracranial pressure. Since pneumoencephalographic studies of this condition are uncommon and rarely necessary for diagnosis, they will not be discussed.

In attempting to evaluate changes in the petrous bone, three major groups were used. In the *first group* were those cases in which definite erosion and loss of bony substance was demonstrated: these findings were considered positive. In the *second group* were those cases showing changes suggestive of a local lesion. Although these findings were consistent with an acoustic tumor, an

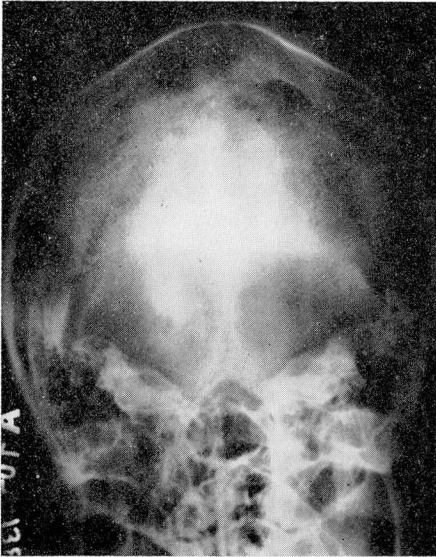


Fig. 1

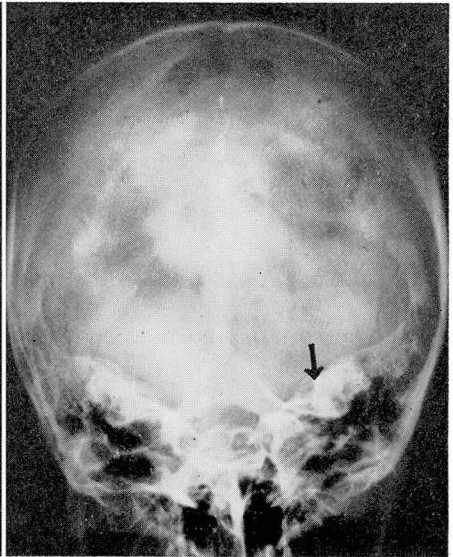


Fig. 2

**Fig. 1.** Normal occipital view. The acoustic meati are clearly visible.

**Fig. 2.** (Woman, 25 years of age) Left acoustic neurilemoma. There is minimal erosion about the acoustic meatus. The arrow points to the sharp line of demarcation between the involved area and normal bone.

unequivocal diagnosis was believed to be unwarranted. Included in this group were those cases in which roentgenograms showed slight density changes that apparently represented bony involvement, but conceivably could have been caused by projection or by normal asymmetry. Also included were suspicious differences in the size of the acoustic meati without definite erosion evident on roentgenograms. Camp and Cilley<sup>13</sup> have shown in a careful study that there is considerable variation in the size and shape of the normal acoustic meati with the normal diameter ranging from 2.5 to 11 mm. Differences up to 2.5 mm. between the two sides of the same patient were seen. The *third group* consisted of those cases with roentgenographic findings considered to be within normal limits.

It is distinguishing between minimal pathologic change and the wide range of normal that affords the greatest difficulty. A point is reached at which one can reasonably justify the presence of a known lesion on the basis of minimal changes; yet almost identical findings can be reproduced in a normal case. This fact we believe explains in large part the wide variation in accuracy of roentgenographic diagnoses reported in the literature. However, another important consideration is the excellence of roentgenographic technic including the use of stereoscopic views in various positions.

In this series, findings were positive (group 1) in 11 cases, suggestive (group 2) in 10, and within normal limits (group 3) in 15. Thus in 21 (58 per cent) of



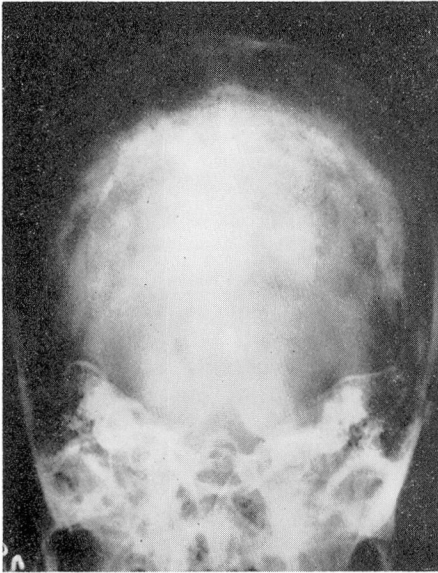


Fig. 3

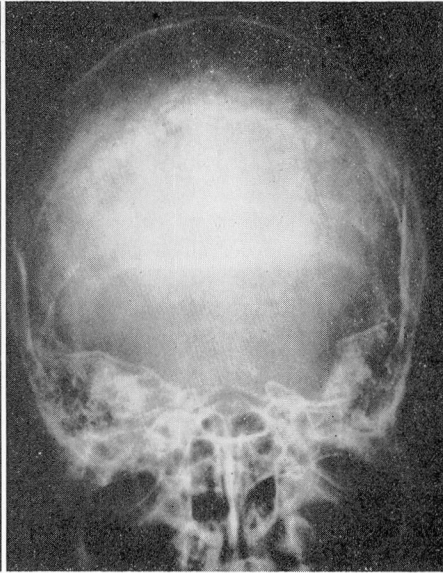

Fig. 4

Fig. 3. (Man, 41 years of age) Left acoustic neurilemoma. Erosion of moderate degree is present in the region of the acoustic meatus.

Fig. 4. (Woman, 59 years of age) Left acoustic neurilemoma. There is unusually marked erosion with destruction of the entire petrous apex.

36 cases, the roentgenologic evidence was adequate to support the diagnosis of acoustic tumor. Evidence obtained from all views has been incorporated into this total impression since, except in the most advanced cases, findings vary according to the projection utilized. By far the most valuable view was the occipital (Towne) view, in which the petrous ridge is thrown free of superimposed structures and its superior-posterior surface visualized. Changes were demonstrated on this view in all of the positive group and in three instances it was the only film to show erosion. Acoustic tumor was suspected on this view in eight of the ten cases in the second group; in one of the two with negative findings, projection was not entirely satisfactory.

Second in value to the Towne view was the basilar view. It showed the clearest evidence of bone destruction in 2 of the 11 cases in group 1. In the second group, the basilar view showed changes on the two occasions when the Towne view was negative. In no case was the Stenver's view most informative and changes could be seen in only a small percentage of cases. The posterior-anterior view was of little or no value in this series since, as routinely made at the Clinic, the petrous ridges are superimposed over the maxillary bones. If special positioning is used with the petrous bone projected through the orbit, this view can be of considerable value. Some investigators, including Camp and Cilley,<sup>13</sup> consider it superior to the Towne.

As mentioned previously, increased intracranial pressure tends to occur late in this disease, and it is most commonly manifested on plain films by changes of the sella turcica. These include straightening of the posterior clinoids with demineralization or actual erosion, and occasionally enlargement of the sella turcica. These findings in contrast to the local changes in the petrous bone are nonspecific, and may result from ventricular obstruction and dilatation of any cause. Of the 21 cases in groups 1 and 2, there were 4 with a definitely abnormal sella that indicated increased intracranial pressure. Of considerable interest was the occurrence of a ballooned sella turcica with definite thinning of the posterior clinoids, observed in one case in group 3. This clearly illustrates that the variation in roentgenographic findings is dependent on the direction of tumor growth. In this case the lesion was apparently able to grow large enough free in the cerebellopontine angle to produce partial obstruction without causing sufficient involvement of the petrous bone to show on roentgenographic examination. In general, however, it would appear that changes in the petrous bone and sella turcica tend to be parallel, since four of the five cases in which change occurred in the sella turcica were all in the first group with definite petrous erosion. No definite abnormality of the sella was seen in the second group. There were several cases of slight demineralization of the posterior clinoids in all three groups which may have represented early increased intracranial pressure but which fell within the range of normal variation.

To correlate the size of the growth with the incidence of change in the petrous ridge is difficult because the actual size of the lesion cannot be determined from its weight at removal, since a variable portion of mass may be cystic and the tumor is usually removed piecemeal. However, as might be expected, there was no particular relationship apparent and of the four largest tumors, all heavier than 20 Gm., only two were in the first group. The duration of symptoms prior to surgery was also considered to determine whether there were a relationship between length of time the lesion was present and the roentgenographic findings. The total number of cases did not allow for any statistical conclusions with the average for the first group 4.1 years, for the second group 2.9 years, and for the third group 3.3 years. However, whereas of the 15 patients in the negative group only 3 had symptoms 5 years or longer, of the 11 in the positive group 5 had symptoms of this duration. These findings suggest that in cases in which the patient's symptoms have been of long duration, there is greater likelihood that changes can be demonstrated on roentgenographic examination.

## SUMMARY

1. The diagnosis of acoustic nerve tumor is chiefly clinical.
2. Changes, when observed on plain roentgenograms, result either from local involvement of the petrous bone, or from nonspecific changes that are due to increased intracranial pressure.

3. In 58 per cent of the cases in this series, there was adequate roentgenologic evidence to support the diagnosis of an acoustic lesion; that is, 21 of the 36 cases showed changes in the petrous bone.

4. The Towne view was found to be the single, most valuable projection.

5. Although cases with abnormality of the sella turcica caused by increased intracranial pressure usually also demonstrate local change, such abnormality can be seen in the presence of a normal petrous apex.

### References

1. Henschen, F.: Zur Histologie und Pathogenes der Kleinhirnbrückenwinkeltumoren. *Arch. f. Psychiat. (Berl.)* 56:20-122, 1915.
2. Hardy, M. and Crowe, S. J.: Early asymptomatic acoustic tumor; report of 6 cases. *Arch. Surg.* 32:292-301 (Feb.) 1936.
3. Penfield, W.: Encapsulated tumors of nervous system; meningeal fibroblastomata, perineural fibroblastomata and neurofibromata of von Recklinghausen. *Surg., Gynec. & Obst.* 45:178-188 (Aug.) 1927.
4. Cushing, H. W.: Tumors of the Nervus Acusticus and the Syndrome of the Cerebellopontile Angle. Philadelphia and London, W. B. Saunders Co., 1917, p. 296.
5. Gardner, W. J. and Frazier, C. H.: Bilateral acoustic neurofibromas; clinical study and field survey of family of 5 generations with bilateral deafness in 38 members. *Arch. Neurol. & Psychiat.* 23:266-302 (Feb.) 1930.
6. Cushing, H. and Eisenhardt, L.: Meningiomas; Their Classification, Regional Behaviour, Life History and Surgical End Results. Springfield, Illinois, Charles C Thomas, 1938, p. 785.
7. Gardner, W. J. and Turner, O. A.: Multiple intracranial tumors; discussion of relation of meningeal to acoustic tumors and report of case. *J.A.M.A.* 113:111-113 (July 8) 1939.
8. Gonzales Revilla, A.: Neurinomas of cerebellopontile recess; clinical study of 160 cases including operative mortality and end results. *Bull. Johns Hopkins Hosp.* 80:254-296 (May) 1947.
9. Grant, F. C. and Spitz, E.: Reported as personal communication by: Hodes, P. J., Pendergrass, E. P. and Young, B. R.: Eighth nerve tumors: their roentgen manifestations. *Radiology* 53:633-665 (Nov.) 1949.
10. Dyke, C. G.: Roentgen Ray Diagnosis of Diseases of the Skull and Intracranial Contents. Chapter in: Golden, Ross (editor): *Diagnostic Roentgenology*. New York, Thomas Nelson & Sons, 1941, pp. 1-134.
11. Hodes, P. J., Pendergrass, E. P. and Young, B. R.: Eighth nerve tumors: their roentgen manifestations. *Radiology* 53:633-665 (Nov.) 1949.
12. Lysholm, E.: Experiences in ventriculography of tumors below tentorium. (Mackenzie Davidson memorial lecture) *Brit. J. Radiol.* 19:437-452 (Nov.) 1946.
13. Camp, J. D. and Cilley, E. I. L.: Significance of asymmetry of pori acustici as aid in diagnosis of eighth nerve tumors. *Am. J. Roentgenol.* 41:713-718 (May) 1939.