

# HYALURONIDASE AS AN AID TO CORRECTION OF PARAPHIMOSIS

## *Report of a Case*

WILLIAM J. ENGEL, M.D.

Department of Urology

**P**ARAPHIMOSIS is a condition in which the prepuce becomes displaced and fixed behind the glans penis. It is often painful. It is almost invariably associated with a tight preputial margin that acts as a constricting ring when it retracts behind the glans; this often occurs during sexual intercourse. The constriction soon creates a "doughnut-like" ring of edema interposed between the constricting band and the glans penis which prevents replacement of the prepuce to its normal position covering the glans.

In those few patients who are seen before the edema becomes too extensive, it is possible to replace the prepuce by manually compressing the edema and then "rolling" the prepuce over the collar of edema. When this is unsuccessful, we have heretofore had to resort to surgical correction by means of a dorsal slit which divides the constricting preputial band.

Williams and Nichols<sup>1</sup> in 1952 reported the use of hyaluronidase in reducing paraphimosis in three patients; more recently my attention was drawn to this useful procedure by Ratliff<sup>2</sup> who reported a case similarly treated. I have recently utilized this method of treatment in one patient and the result was most gratifying. This case is described here in order to disseminate information regarding this useful procedure; it is hoped this may benefit others who may be called upon to treat those afflicted with this benign though painful condition.

## CASE REPORT

A man, 23 years of age, was referred to me because of a painful swelling of the penis. Examination revealed a typical paraphimosis which was stated to be of almost 48 hours' duration. There was some bleeding as a result of earlier vigorous attempts to reduce the paraphimosis. The pain produced by these attempts had made the patient apprehensive.

One hundred and fifty turbidity reducing units of hyaluronidase was dissolved in 2 cc. of a 1 per cent procaine solution and then drawn into a syringe. After the skin of the penis was cleansed, the constricting ring of the prepuce was exposed by gently retracting the edematous collar. Through a No. 23 needle,  $\frac{1}{2}$  cc. of the hyaluronidase-procaine solution was injected into the ring (favoring the distal, edematous side) at the top, at the bottom, and on each side (fig. 1). Distribution of the solution was aided by placing an annular band of gauze and then gently massaging the injected solution into the tissues.

Within 15 minutes the tense, edematous "doughnut" had noticeably softened and,

in 20 minutes, it was possible to express the remaining edema fluid into the adjacent tissues. The prepuce was then painlessly replaced to its normal position with the greatest ease. The patient was advised to return at a later date for circumcision.

### COMMENT

The rationale and success of this method of treatment are based upon a peculiar property of hyaluronidase. This enzyme acts by depolymerizing the long chains of polymerized hyaluronic acid which constitute the bulk of the ground substance of connective tissue. This ground substance normally limits the spread of fluids and other extracellular material. By unmeshing its weave, hyaluronidase permits local accumulations of fluid to spread farther and more

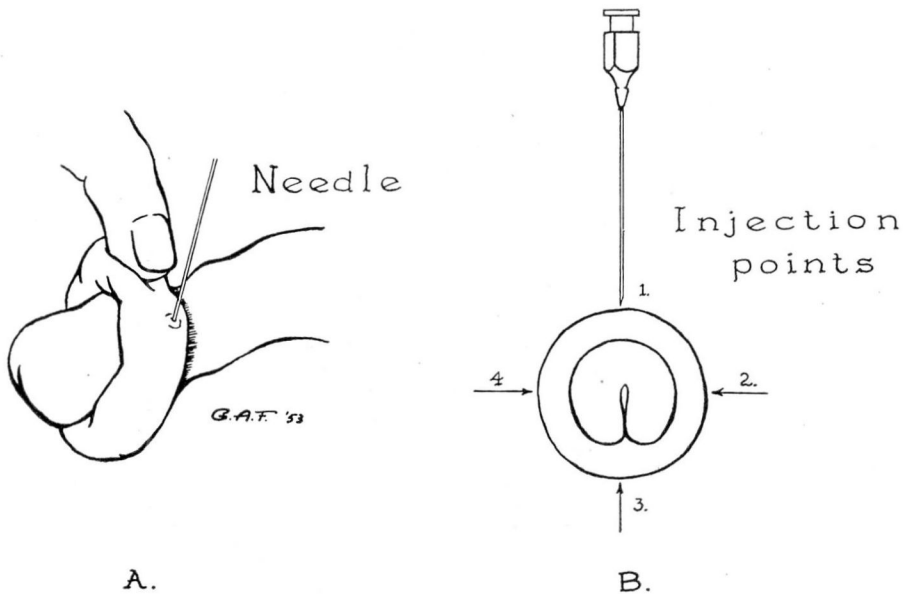


Fig. 1. (A) Drawing showing edematous tissue being rolled forward to expose constricting ring. Injection made just distal to the constricting ring. (B) Diagrammatic representation of points of injection.

rapidly, and thus promotes their absorption. This action was dramatically demonstrated in this case. No doubt this property of the enzyme hyaluronidase can be extended to many other situations in which it is useful to dispel tense edema fluid quickly from the tissue. I believe that the dilution of the hyaluronidase in a procaine solution offers a distinct advantage in that it combines the hydrolyzing effects of the enzyme with the local anesthesia provided by the procaine solution.

### SUMMARY

A case is reported in which a painful paraphimosis of two days' duration was successfully, easily, and painlessly reduced by the use of hyaluronidase dissolved in a 1 per cent procaine solution injected into the edematous and constricting ring.

### References

1. Williams, T. H. and Nichols, R. K.: Method of treating paraphimosis. J.M.A. Alabama 21:233-234 (Feb.) 1952.
2. Ratliff, R. K.: Paper read before the North Central Section of the American Urological Association. Cincinnati, Ohio (Oct.) 1953.