

REOPERATED CONGENITAL MEGACOLON

RUPERT B. TURNBULL, JR., M.D.

Department of Proctology and Colon Surgery

and

LAWRENCE J. McCORMACK, M.D.

Department of Pathology

THE study of the pathology of congenital megacolon by Whitehouse and Kernohan¹ and Swenson's physiologic and surgical studies²⁻⁴ form a logical approach to adequate therapy of the disorder best known as congenital megacolon or Hirschsprung's disease.⁵ We viewed with some misgivings the recent report of State⁶ who advocated retention of the major portion of the rectum as part of the surgical correction of this disorder.

We have recently encountered a case in which the distal sigmoid and rectum containing an aganglionic segment had been retained, and reoperation was required.

CASE REPORT

Clinical Features

The patient, a two year old white boy, was first seen at the Clinic on April 29, 1949. His birth had been uneventful, but on the fourth day following delivery abdominal distention was noted which was relieved by enemas. The child then had six to eight loose watery stools a day for the first six months of life. At about the end of the first year the diarrhea was replaced with obstinate constipation, requiring the aid of high colonic irrigations for evacuation.

Physical examination revealed the boy to be in apparently good health. The abdomen was slightly distended and a putty-like mass filling the right flank was palpable. The rectum was dilated and contained a large fecal impaction. A barium enema revealed a narrowed area in the distal sigmoid which showed little change in the filled colon and evacuation films. The colon proximal to the narrowed area was greatly dilated, particularly in the cecum and ascending colon (fig. 1). A diagnosis of Hirschsprung's disease was made, and on May 13, 1949, 14 days after initial examination, a laparotomy was performed by the late Dr. Thomas E. Jones. The lower descending colon and sigmoid appeared greatly dilated with a transition zone to normal size about 4 inches above the peritoneal reflection. The dilated bowel was resected by the Rankin modification of Mikulicz's technic. The postoperative course was uneventful and on the fifth day a spur clamp was applied. Three months later, the colostomy was closed, and two weeks following this the diarrhea reappeared; the patient had three to six watery stools daily. Five months postoperatively the child became mildly constipated with a spontaneous bowel movement every third day. At this time no fecal impactions were noted and the remainder of the physical examination was normal.

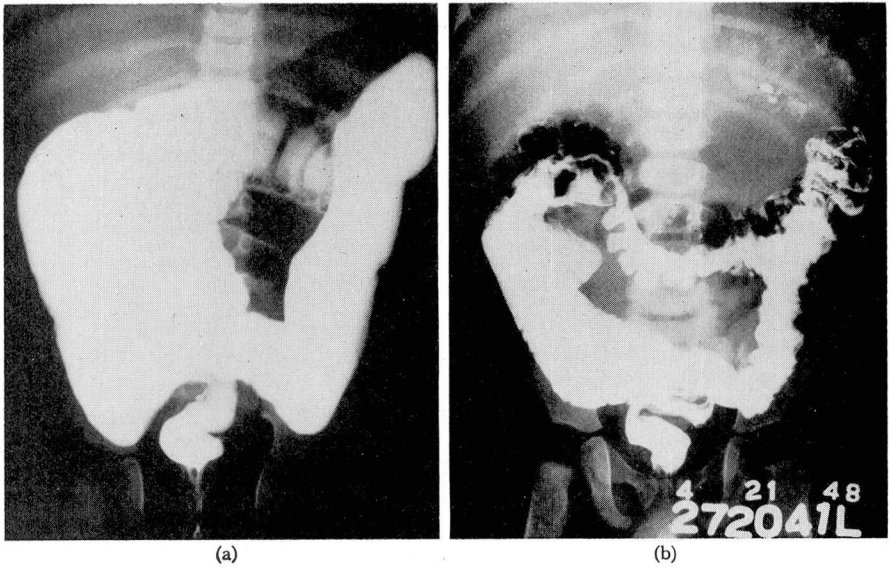


Fig. 1. Barium enemas in 1949. (a) Filled. (b) Evacuated. A constantly narrowed area is present in the distal sigmoid; the colon proximal to this area is greatly dilated, particularly in the cecum and ascending colon.

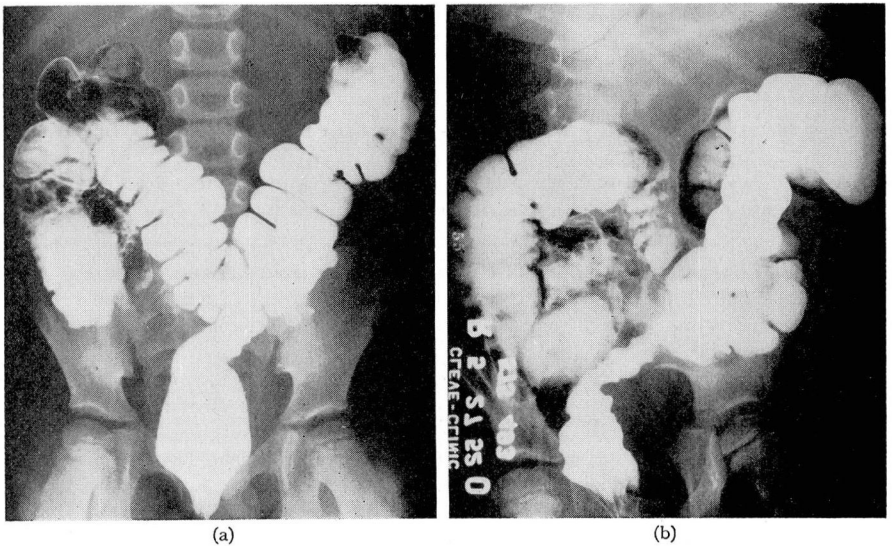


Fig. 2. Barium enemas in 1952. (a) Filled. (b) Evacuated. The rectum is slightly narrowed at the rectosigmoid. Proximal to this area there is a segment of constant narrowing. Proximal to this narrowed area the colon is again dilated. Postevacuation film shows retention of nearly all the injected barium.

Three years following resection, the child returned because of sudden cessation of bowel movements with no natural evacuation for one month. Abdominal distention and cramps had been present during this time and enemas were given daily. His appetite had decreased and there had been some weight loss. The child was readmitted to the hospital, and in April 1952 proctosigmoidoscopic examination to 13 inches revealed a normal rectum and lower sigmoid colon with a widely patent anastomosis in the region of the old colostomy closure. The general physical examination was otherwise normal. No fecal masses could be palpated. A barium enema revealed the rectum to be slightly narrowed at the rectosigmoid, and for approximately 5 cm. proximal to this area there was constant narrowing of the bowel. The colon proximal to this narrowed area was considerably dilated. Postevacuation films showed retention of nearly all the injected barium (fig. 2).

At surgery the closed colostomy was found intraperitoneally located about 5 inches above the pelvic floor. There was minimal dilatation of the colon above this point and the terminal sigmoid below appeared to be normal. A full thickness biopsy of the wall of the colon proximal to the anastomosis, examined by frozen section technic,⁷ revealed the presence of ganglia. The pedicle containing the inferior mesenteric artery and vein was then ligated near the lower border of the third portion of the duodenum, and the rectum was freed from its attachments in the pelvis, keeping the dissection as close to the bowel wall as possible. The resection and pull-through technic with anastomosis was carried out as described by Swenson. The anastomosis was made with single layer of 000 chromic catgut sutures. Watery bowel movements were noted on the third day and at least one bowel movement a day was noted thereafter. On the eighth postoperative day a small pre-sacral abscess drained spontaneously through the anastomosis; the child was discharged on the 21st day.

An attack of high intestinal obstruction, necessitating laparotomy with lysis of an adhesive band occurred in September 1952, five months after operation. Otherwise, the child's progress was satisfactory. A normal bowel habit was established and enemas and cathartics have not been necessary.

Pathologic Features

The original surgical specimen (May 1949) consisted of a flask-shaped segment of large intestine without attached mesentery, 20.0 cm. in length (fig. 3). The serosal surface was smooth, glistening, transparent, and appeared slightly edematous. The opened specimen was dilated to a circumference of 7.0 cm. at the proximal line of resection, gradually increasing to a maximum diameter of 12.0 cm. near the distal line of resection; finally, there was moderately rapid narrowing of the bowel to a circumference of 5.0 cm. at the distal line of resection. The bowel wall was thickened (up to 4 to 5 mm.) especially in the distal half. The mucosa was yellowish-tan in color and revealed no ulceration; in the proximal end of the bowel the mucosal folds were normal, but were thickened in the distal half.

Microscopically, multiple sections through the thickened and dilated portion of the bowel revealed a muscularis externa that was several times its normal thickness but with layers arranged in the usual fashion. The tissues were somewhat loosely arranged, suggesting edema. Myenteric ganglia were present in both the submucosa and between the circular and longitudinal muscle layers. They appeared to be slightly decreased in these areas, but this was relative and only apparent because of the large increase in size of the muscular layers.

The pathologic diagnosis was megacolon, probably of congenital type.

The operative specimen at the second operation (April 1952) consisted of 16 cm. of colon, including approximately 6.0 cm. of rectum and an old, well-healed anastomotic line. The specimen measured 7.5 cm. in circumference. The internal surface revealed a normal appearing mucous membrane. This entire specimen was serially blocked at approximately 0.7 cm. intervals. Sections of the colon adjoining the proximal line of old anastomosis revealed normally distributed ganglia.

The distal 7.0 cm. of the specimen (chiefly rectum) was the most important histologically. It must be divided into a proximal and distal segment. The proximal segment, 4.0 cm. in length, revealed moderate thickening of the muscularis externa, numerous bundles of nerve fibers between muscular layers and in the submucosa, but in no section from this area could myenteric ganglia be identified. It is of note that the muscularis mucosae in the aganglionic area was uniformly hypertrophied to a thickness approximately four times normal (fig. 4, a and b). The distal segment, 3.0 cm. in length, showed thinning of the muscularis mucosae to normal and a reappearance of myenteric ganglia. This change occurred gradually in the most proximal 1 cm. of this portion. The most distal 2.0 cm. portion of this segment then possessed a normal muscularis mucosae and a normal distribution of myenteric ganglia (fig. 4, c and d).

The pathologic diagnosis was congenital megacolon, previously operated.

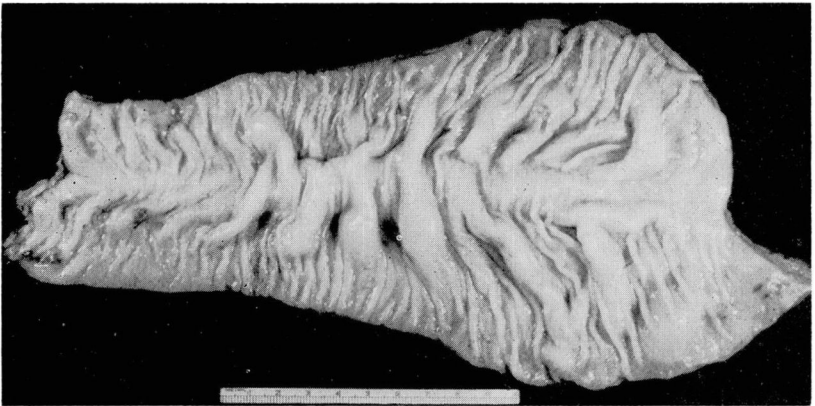


Fig. 3. Specimen of original surgical resection. Note flask shape and hypertrophied mucosal folds.

COMMENT

Congenital megacolon may be defined as the failure of normal bowel and rectal function dating from birth, associated with extreme dilatation of all or part of the colon with retention of feces and gas, and absence of the ganglionic elements over varying areas of the rectum and sigmoid colon. Hirschsprung's classic paper in 1887 aroused considerable interest in this condition but etiology and pathologic physiology remained obscure until recently. In 1948, Whitehouse and Kernohan¹ published a detailed histopathologic study of the rectum

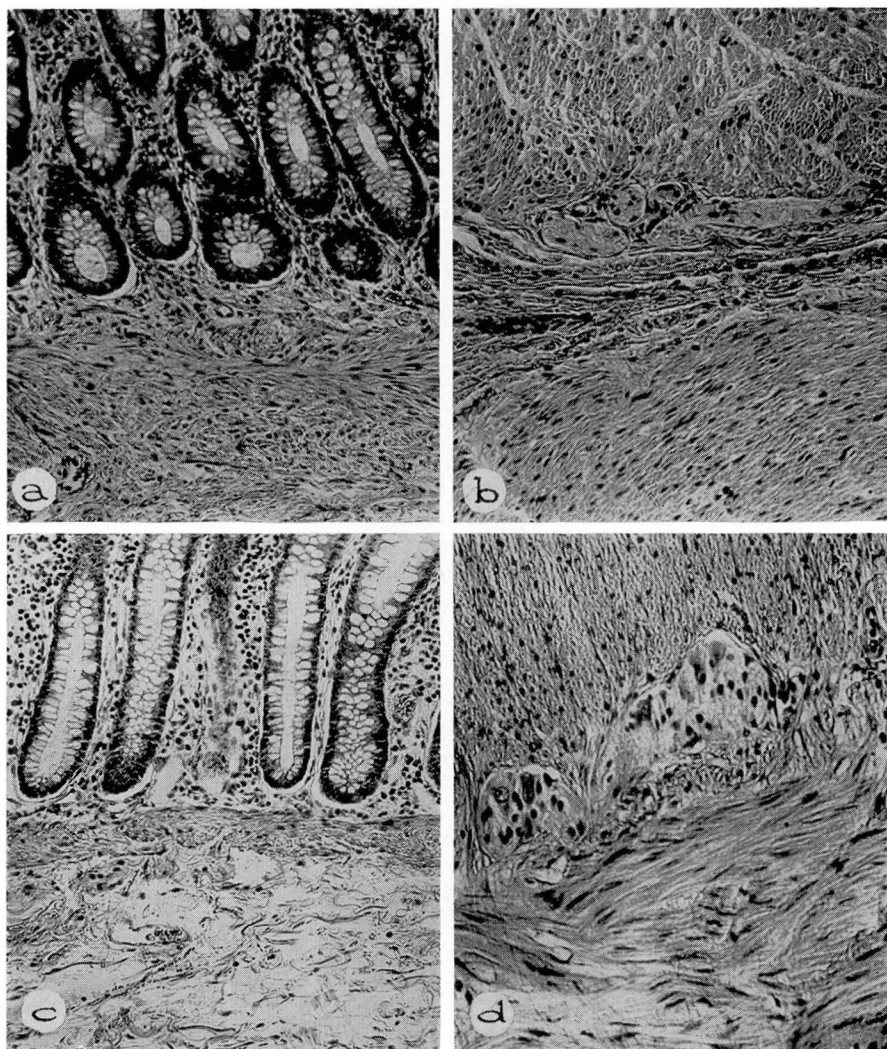


Fig. 4. Histology of portion of rectum removed at last resection. (a) and (b) Aganglionic area. (c) and (d) Ganglia-containing area. (a) Marked hypertrophy of the muscularis mucosae in aganglionic segment. X 130. (b) Representative area between layers of muscularis externa. Note absence of ganglia with presence of large nerve fibers. X 180. (c) Normal muscularis mucosae in distal rectal segment where ganglia were present. X 130. (d) Normal myenteric ganglia in distal rectal segment. X 180. Hematoxylin-eosin-methylene blue stain.

and colon of 11 patients. Their findings were: (1) absence of the myenteric ganglia of the rectum with a transitional zone at the rectosigmoid or extending upward wherein altered numbers of normal ganglia could be found; (2) normal ganglia in the remaining colon; and (3) the presence of closely packed non-myelinated nerve trunks between the longitudinal and circular muscle layers in the aganglionic segment of the bowel. Our case adheres closely to these morphologic features. However, in none of their cases was mention made of the reappearance of ganglia in the most distal portion of the rectal segment. They also made no mention of the marked hypertrophy of the muscularis mucosae in the aganglionic segment, which finding has been a rather constant feature of our surgically treated cases of congenital megacolon.

Many surgical procedures have been described for the treatment of congenital megacolon. None of them were truly satisfactory until Swenson and his co-workers reported their contributions in 1948. Swenson demonstrated disordered peristalsis in the rectosigmoid or rectum at the lower limit of the area of colonic dilatation and believed these parts to be physiologically obstructing. We believe that the hypertrophy of the muscularis mucosae at this level may be interpreted as further evidence of altered muscular activity within this area. By a modification of Maunsell's⁸ operation, Swenson was able to resect the aganglionic rectum and rectosigmoid with preservation of the sphincters. The success of the Swenson operation depends upon total removal of those portions of the rectum or lower colon wherein no myenteric ganglia can be found. We have screened biopsies of these colons by frozen section technic to determine presence of myenteric ganglia.

The less radical procedure recently advocated by State,⁶ *ie.* resection of narrowed sigmoid and upper rectal segments in addition to the proximal dilated colon with anastomosis between normal appearing colon and upper rectum, may be doomed to eventual failure since the aganglionic area may not be completely removed.

SUMMARY

A case of congenital megacolon is reported in which reoperation was performed because of initial retention of the aganglionic upper rectal segment. It is emphasized that single resection of the dilated, hypertrophied colonic segment alone may temporarily restore the patient's bowel function to a normal state even for a period of several years. However, retention of the aganglionic segment can eventually result in physiologic obstruction and recurrent megacolon, necessitating further surgery.

References

1. Whitehouse, F. R. and Kernohan, J. W.: Myenteric plexus in congenital megacolon; study of 11 cases. *Arch. Int. Med.* 82:75-111 (July) 1948.
2. Swenson, O. and Bill, A. H., Jr.: Resection of rectum and rectosigmoid with preservation

REOPERATED CONGENITAL MEGACOLON

of sphincter for benign spastic lesions producing megacolon; experimental study. *Surgery* **24**:212-220 (Aug.) 1948.

3. Swenson, O., Neuhauser, E. B. D. and Pickett, L. K.: New concepts of etiology, diagnosis and treatment of Hirschsprung's disease. *Pediatrics* **4**:201-209 (Aug.) 1949.
4. Swenson, O., Rheinlander, H. F. and Diamond, I.: Hirschsprung's disease; new concept of the etiology. Operative results in 34 patients. *New England J. Med.* **241**:551-556 (Oct. 13) 1949.
5. Hirschsprung: Stuhlträgheit Neugeborener in Folge von Dilatation und Hypertrophie des Colons. *Jahrb. f. Kinderh.* **27**:1-7, 1887.
6. State, David: Surgical treatment for idiopathic congenital megacolon (Hirschsprung's disease). *Surg., Gynec. & Obst.* **95**:201-212 (Aug.) 1952.
7. Hazard, J. B. and Stevenson, G. F.: Frozen section technic. *Am. J. Clin. Path.* **19**:873-879 (Sept.) 1949.
8. Maunsell, H. W.: A new method of excising the two upper portions of the rectum and the lower segment of the sigmoid flexure of the colon. *Lancet* **2**:473-476, 1892.