

THE PEDICLED SKIN FLAP

ROBIN ANDERSON, M.D.
Department of Plastic Surgery

THE pedicled flap, commonly used by the plastic surgeon in the reconstruction of skin and soft tissue defects, differs from the so-called free skin graft in two ways: first, it consists of all of the layers of the skin, with a significant amount of attached fat and subcutaneous tissue; and second, it carries its own blood supply from one or more segments of its periphery.

This type of flap has been used since the earliest recorded days of medicine. As early as 800 B. C. Sushruta, the father of Hindu surgery, described in detail operations for the reconstruction of lost noses and lips by means of flaps from the cheek. Tagliacozzi in 1597 presented a method of reconstructing the nose by means of a pedicled flap from the upper arm; a technic known today as the Italian method and still employed. The use of a forehead flap for nasal reconstruction was developed on the basis of reports of such operations brought to England from India early in the 19th century. Since then, the utilization of such pedicles in reconstructive surgery has become increasingly common, particularly following Gillies' development of the tubed flap within the last 30 years.¹

In general, it can be said that the pedicled flap should be used in preference to some other type of replacement material wherever skin coverage plus additional soft tissue with or without new blood supply are required. For example, defects over bony prominences such as the elbows and tuberosities of the ischium, where the possibility of damage to the covering structure is significant, require soft tissue padding in addition to the superficial skin. This is particularly true of the sole of the foot which is exposed to constant severe trauma in the course of normal activity.

Avascular tissues such as bone and cartilage are usually unable to support a free skin graft. Their coverage is best obtained by means of pedicles carrying

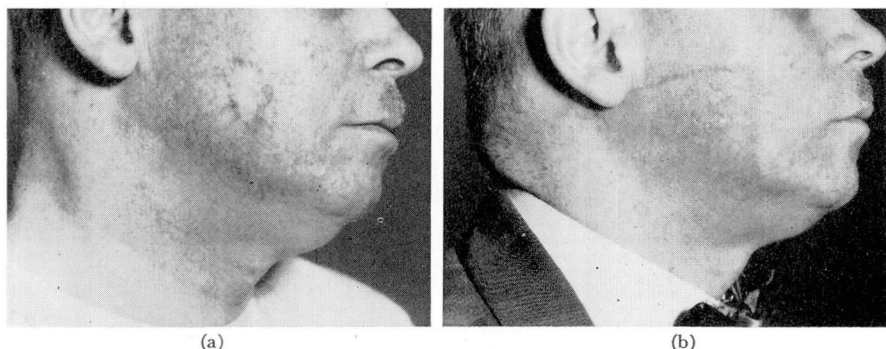


Fig. 1. Typical example of repair by local flap of defect produced by removal of basal cell carcinoma; flap undermined widely and advanced to new position. (a) Preoperative. (b) Postoperative.

their own blood supply. The repair of severe, chronic, radiation lesions in which deep scarring makes total excision impossible, presents the same problem because of severe loss of vascularity.

Particularly during a war, compound injuries occur in which surface defects are associated in continuity with bone, nerve or tendon injuries for which further surgery is necessary. Since the success of any healing process depends upon an adequate blood supply, it is imperative that superficial scar be replaced with pedicled skin and soft tissue before surgical procedures are carried out on the deep structures. The healing of fractures and the vascularization of bone and cartilage grafts demand similar blood-bearing covering material. Finally, the demands of cosmetic restoration may require the presence of soft tissue and new blood supply as well as skin. This becomes obvious when one considers the problems inherent in building a nose, the contour of which depends not only on bony and cartilaginous support, but also upon the rounded contours of the tissue itself.

Considerable thought must go into the preparation of a pedicled flap prior to its manipulation. Careful planning of the flap with particular reference to the blood supply to be carried from its base is essential, with the further consideration that the transfer of this pedicle must not create a second prominent deformity in the course of repairing the original one. A flap may be of any size providing that its length to width ratio is calculated on the basis of available blood supply. In most instances one hesitates to construct a pedicled flap vascularized by a single source, in which the length of the flap is more than three times its width. Deficiencies in potential circulation may be corrected by a procedure known as "delaying," which consists of progressive elimination of blood supply, except at the proposed base of the flap, by means of surgical incisions around most of its periphery. Since maximum compensation in the remaining vessels takes place within about three weeks, a reasonably accurate estimate of the optimum time for utilizing the flap can be made. Any number of individual "delays" can be carried out to assure the viability of the flap at the time of transfer. It is most important that the flap be handled delicately during these procedures to avoid damage to barely viable tissue. Hemostats are used on the flap only to control vigorous bleeding. The pedicle is manipulated with fine hooks in its subcutaneous layer to avoid compromising the circulation more than absolutely necessary. The flap when transferred to a recipient area is sutured in place in such a way as to avoid any tension across the suture line or along the course of the pedicle itself. To assure this absence of tension, flaps are usually constructed somewhat larger than apparently necessary to allow for inevitable shrinkage.

TYPES OF FLAPS

Many types of flaps have been described. In general they fall into two categories: *adjacent* and *distant*.

The *adjacent flap* is prepared in the immediate neighborhood of the area to be covered, and transferred to its new location in such a way that the remain-

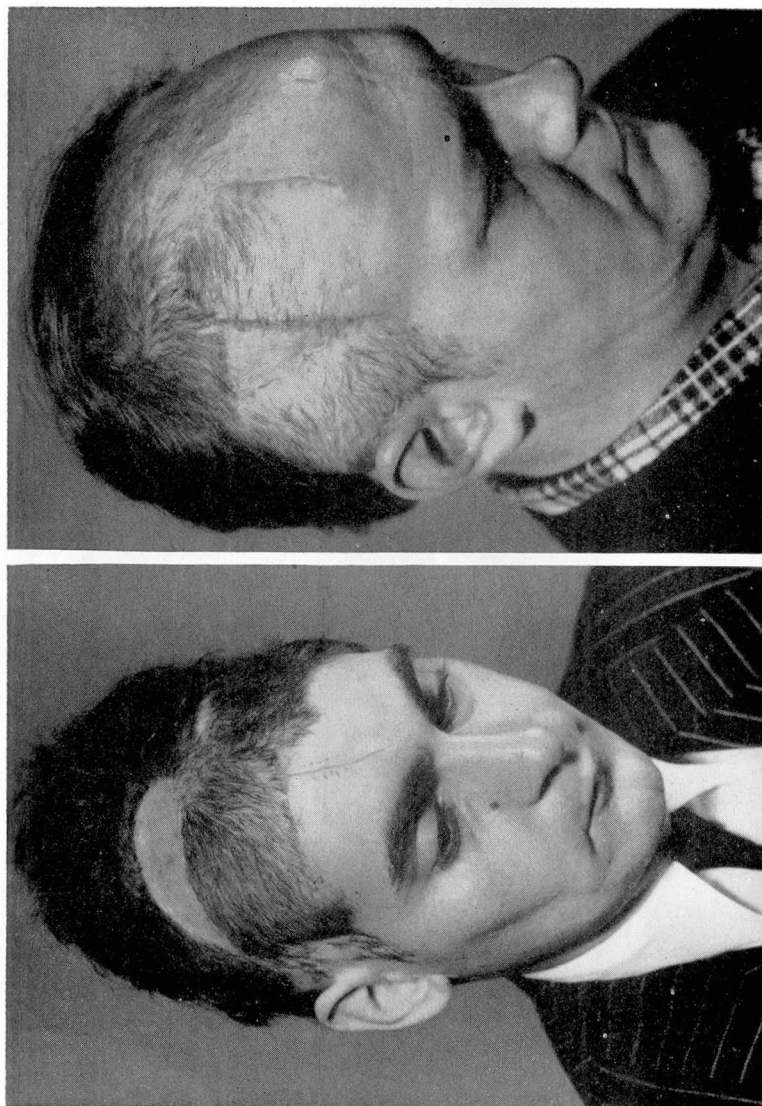


Fig. 2. (a) and (b) are two examples of repair by pedicled flap of full-thickness defects of scalp in which the flap donor site has been covered with split skin.

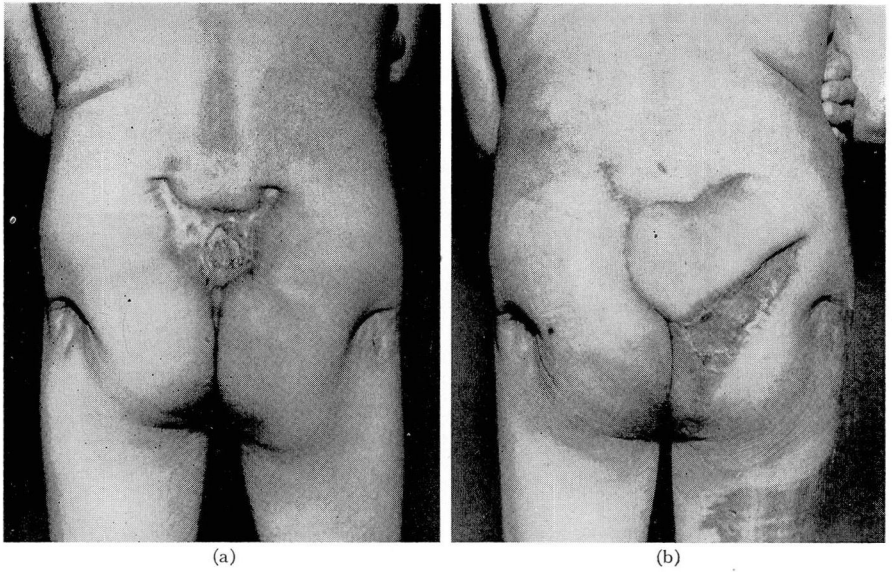


Fig. 3. Sacral decubitus ulcer containing squamous carcinoma treated by excision, and transfer of blood-bearing pedicled flap. (a) Preoperative. (b) Postoperative.

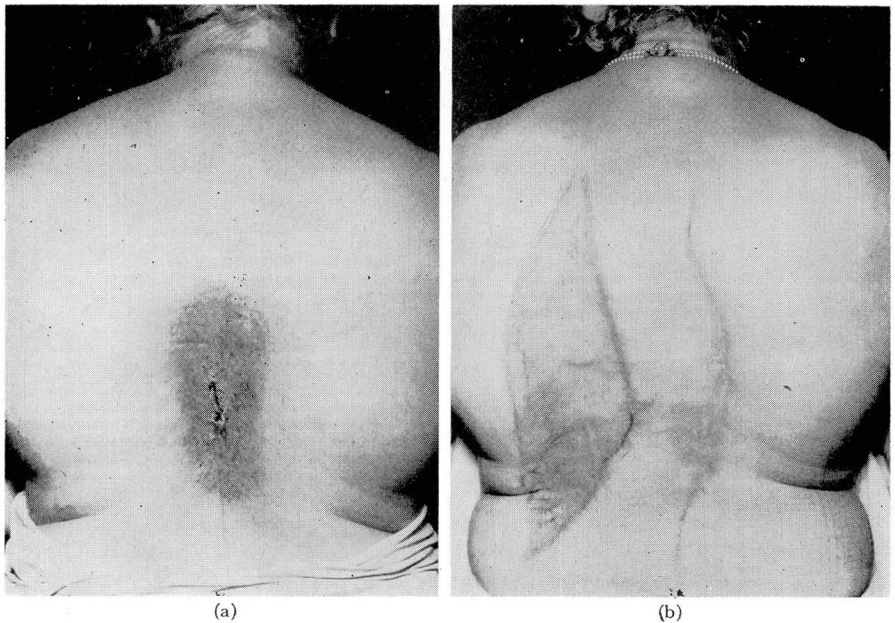


Fig. 4. (a) Severe radiation lesion of back following treatment of vertebral hemangioma. (b) Double-pedicled flap transferred to recipient site; donor defect covered with split skin graft.

ing donor defect produces little cosmetic or functional deformity (fig. 1). If the donor defect cannot be closed primarily, a small skin graft is usually satisfactory (fig. 2 and 3). The terms "advancement," "sliding," and "rotation" as applied to this type of flap merely imply the direction and means of transfer to the recipient site. These flaps may be based on a single or double blood-bearing pedicle, the latter providing additional insurance against inadequate circulation (fig. 4).

The *distant flap* is one in which the donor site is not in the immediate vicinity of the defect to be repaired. Thus, one or more transfers are necessary,

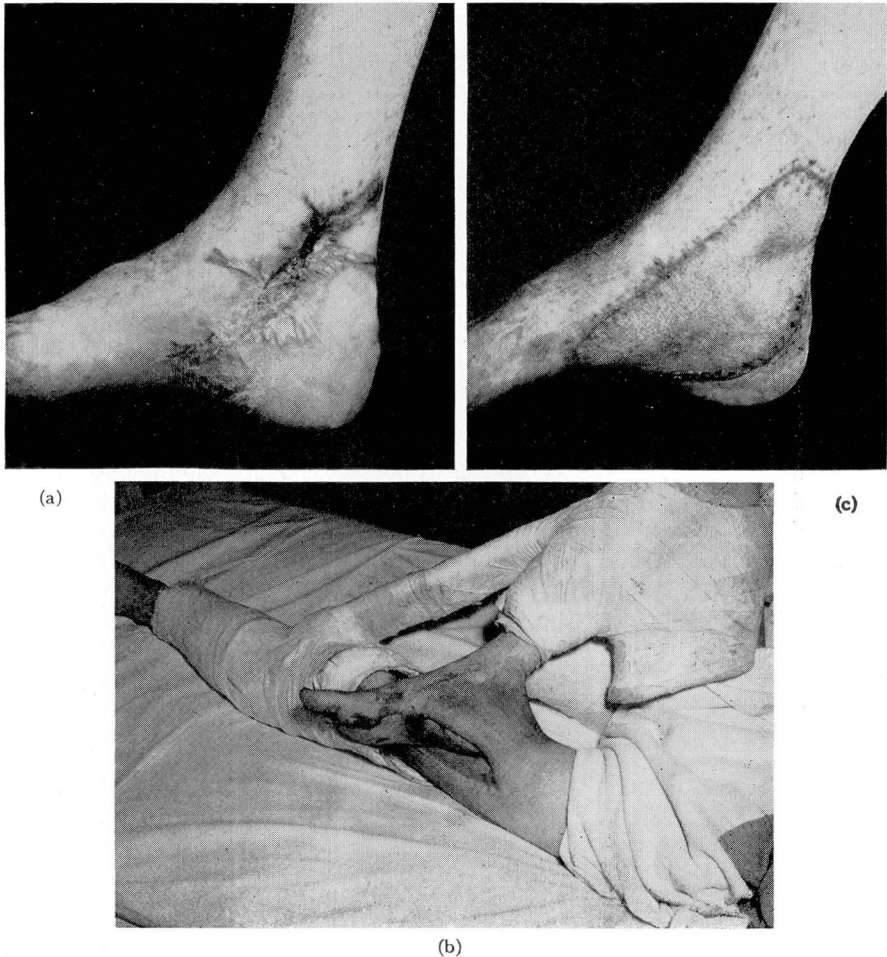


Fig. 5. (a) Scar deformity of ankle following compound fracture with skin and soft tissue avulsion. (b) Flap from opposite thigh in process of being transferred to defect. Two "delays" had been carried out prior to this stage. (c) Final result, showing good coverage which will permit additional bone surgery if necessary.

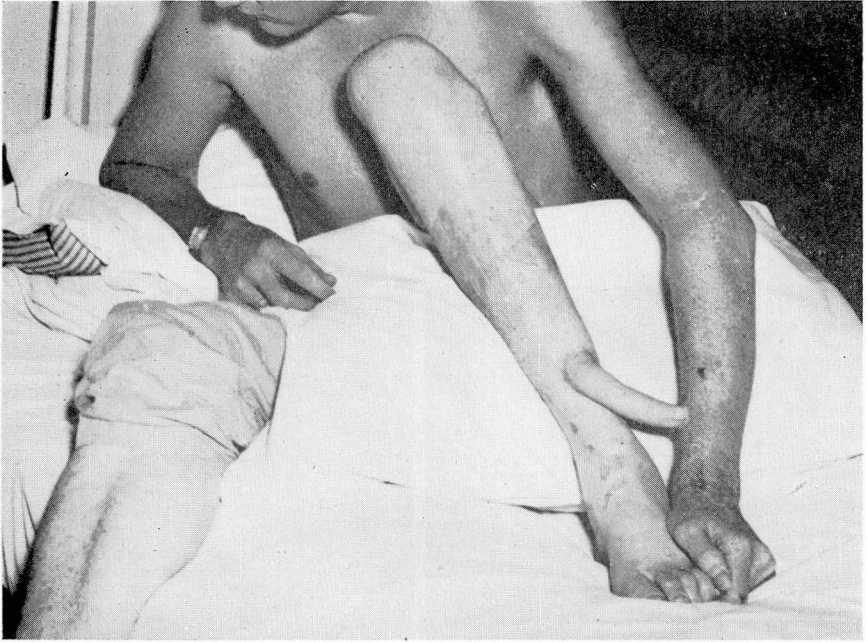


Fig. 6. Tubed pedicle carried on the wrist from abdomen to leg defect.

during each of which new blood supply is acquired, to reach the recipient area. One such transfer may be all that is necessary, as for example, in the use of the thigh flap to cover a defect of the leg or foot (fig. 5). If additional transfers are required, a mobile part of the body, usually the wrist, is used as a carrier to simplify the procedure. In this instance, the flap is often tubed to eliminate drainage and infection always associated with any raw surface (fig. 6). The only disadvantage to the tubing of a flap is the increase in total time required to complete the procedure. Occasionally, when a distant transfer is to be made over a short distance, the flap may be moved caterpillar-fashion. This procedure is impractical when more than two or three transfers are required.

Reference

1. Davis, J. S.: Address of president; story of plastic surgery. *Ann. Surg.* 113:641-656 (May) 1941.