

POPLITEAL ANEURYSM

Treatment by Vein Graft: Case Report

A. W. HUMPHRIES, M.D.

Department of Orthopedic Surgery

F. A. LeFEVRE, M.D. and V. G. deWOLFE, M.D.

Department of Cardiovascular Disease

THE popliteal artery is the second most common site of aneurysm. The treatment of this condition has been reviewed frequently and various methods have been suggested to restore normal anatomy.¹⁻¹³

A patient was recently seen suffering from bilateral popliteal aneurysm. One side was treated by resection and sympathectomy; the other by venous homograft technic. An unusual opportunity has been provided to compare the results of the two procedures in the same patient.

Case Report

The patient, a 59 year old man, was admitted to the Clinic complaining of recurrent attacks of pain in both lower extremities. A review of the history indicated that for two years prior to admission he had been aware of slight leg fatigue following exercise. At no time did he have intermittent claudication. Eight months prior to admission, he experienced a sudden attack of severe knife-like pain in the left calf which occurred while walking. No unusual coldness, numbness, or color change was noted. The attack of severe pain lasted two days and gradually subsided. Three months following this attack, he had a second severe episode of pain in the left calf, lasting several days. One week before admission to the Clinic, he developed a similar attack of pain in the right calf. Following each attack petechiae were observed over the involved extremity. No pain was noted between attacks but leg fatigue continued to occur following exercise. At no time was there evidence of swelling. Local tenderness to pressure was noted at the time of all attacks.

Examination of the lower extremities revealed the feet to be warm and of normal color. A few superficial varicosities were noted. The dorsalis pedis and posterior tibial pulses were of good quality. Examination of the left popliteal fossa revealed a pulsating mass approximately 8 cm. by 4 cm. in size. Examination of the right popliteal fossa disclosed a slightly smaller pulsating mass. The retinal vessels demonstrated no significant changes. No evidence of cardiac enlargement was found and the heart sounds were normal. The blood pressure was 210/130. Laboratory studies including roentgenographic examination of the chest, electrocardiogram, and renal function tests were normal. Our clinical impression was (1) essential hypertension, and (2) bilateral popliteal aneurysms with secondary arterial emboli involving the calf region. Hospitalization was advised and the following procedure carried out.

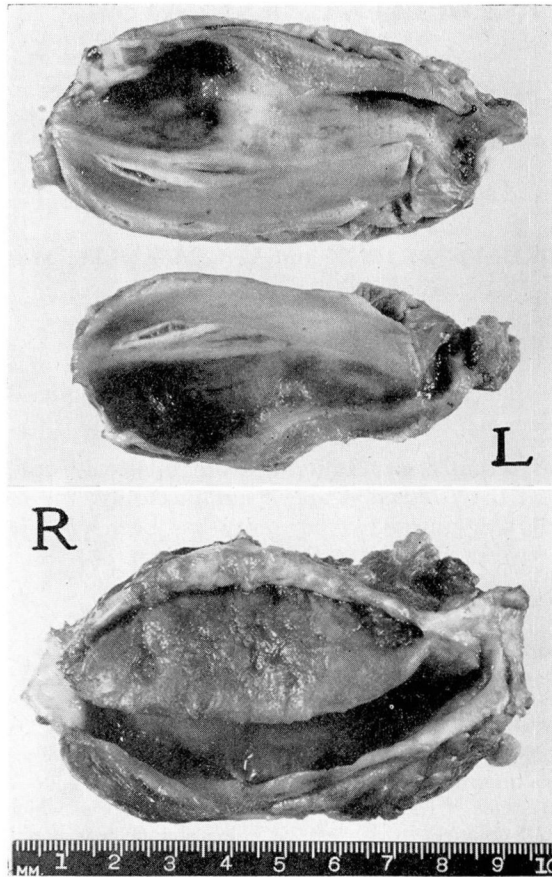


FIG. 4.

The aneurysm on the left side was exposed and found to be 11 by 4 by 5 cm. (fig. 4). The wall of the aneurysm was sclerotic with areas of yellowish degeneration which were soft and it was felt inadvisable to attempt direct repair. The cut ends of the artery were ligated and no major collaterals were sacrificed. A left lumbar sympathectomy (L1-L3) was done immediately following the foregoing procedure. Nine days later, the right popliteal aneurysm was completely excised and found to be 10 by 5 by 5 cm. (fig. 4). A vein graft was introduced to establish continuity of the vessel (fig. 1). The lesser saphenous vein was transected distal from its entrance into the popliteal vein. The end of the vein was swung up and anastomosed to the proximal cut end of the popliteal artery, thus permitting a flow of blood through this artificial arteriovenous fistula. The distal end of the popliteal artery was then prepared for anastomosis. The use of this technic (Julian¹⁵) insures reversal of the vein direction, thus eliminating the problem of the vein valves. The lesser saphenous vein was again transected prior to its entrance into the popliteal vein to give a vein segment slightly shorter than the missing portion

of the popliteal artery. The vein was swung down, and anastomosed to the distal end of the artery. Following this, an emphatic pulsation was noted in the grafted vein and a strong pulsation in both the dorsalis pedis and posterior tibial artery. This area was drained for two days and the postoperative course was uneventful. No anticoagulants were used.

Bed rest was continued for six days and then light activity was permitted. The post-operative right femoral arteriogram is shown in figure 2 and the left in figure 3. The clinical course to date has been satisfactory. The right leg feels normal to the patient. The foot has remained warm and of normal color with good dorsalis pedis and posterior tibial pulsations. Slight edema, noted after prolonged standing, has been controlled with an elastic support. Some distress involving the left side has been experienced. This consists of numbness of the foot, and pain in the distribution of the ilio-inguinal and iliohypogastric nerves. The foot pulses are, of course, absent. The foot is warm and of good color. No intermittent claudication has been noted.

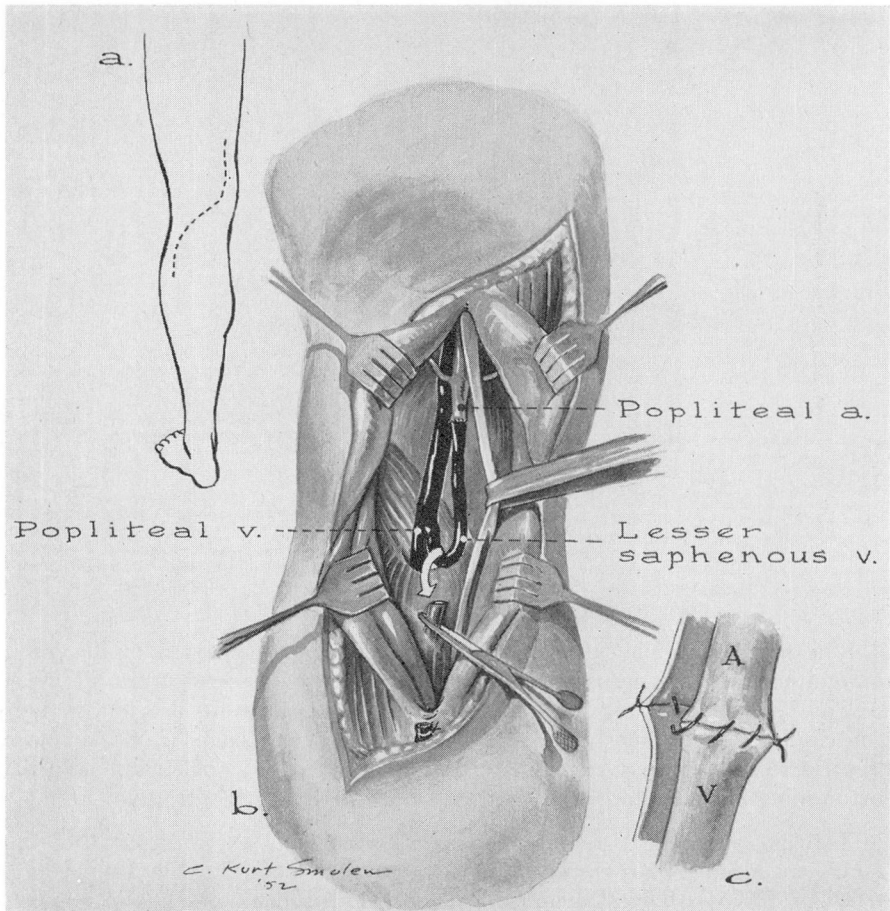


FIG. 1. (a) Incision. (b) Exposure and first anastomosis. (c) Technic of anastomosis.

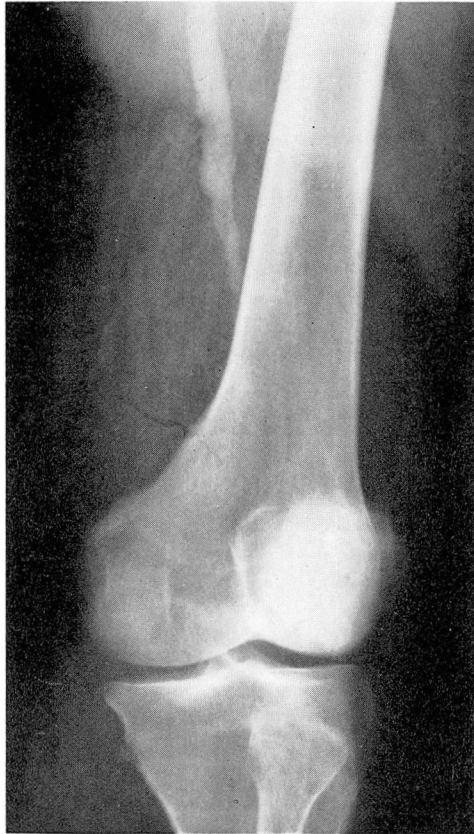

FIG. 2.

Comment

The most common cause of aneurysms of the large vessels of the lower extremities is arteriosclerosis. Syphilis is a rare cause of aneurysm in the lower extremities. The incidence of aneurysm involving the popliteal artery is high. Contributory factors may be: (1) frequent bending of the knee, (2) repeated pressure secondary to sitting and crossing the knees, (3) poor protection by surrounding muscles, and (4) a location frequently subject to trauma.

The diagnosis can generally be made on physical examination, but unusually small aneurysms are not palpable and these may give rise to symptoms. Arteriography is a helpful means of diagnosis in suspected cases.

In all cases excision of the aneurysm is beneficial, not only for elimination

of the disease but for the following reasons: (1) it removes a space-consuming lesion which may compress the collateral circulation; (2) full flexion of the knee may be restricted in the presence of aneurysm; (3) the size of the aneurysm may cause stretching of the artery in the region of the collateral ostea thus reducing the collateral circulation.

In 1947 Blakemore¹⁴ presented a technic of vein graft inlay for the repair of arterial aneurysm using vitallium tubes. Four cases were reported, one a popliteal aneurysm.

The use of venous grafts as suggested by Julian et al.¹⁵ in the treatment of segmental arteriosclerosis obliterans of the lower extremities offers a means of reestablishing the circulation. We believe this method can be applied to the popliteal artery for the treatment of aneurysm.

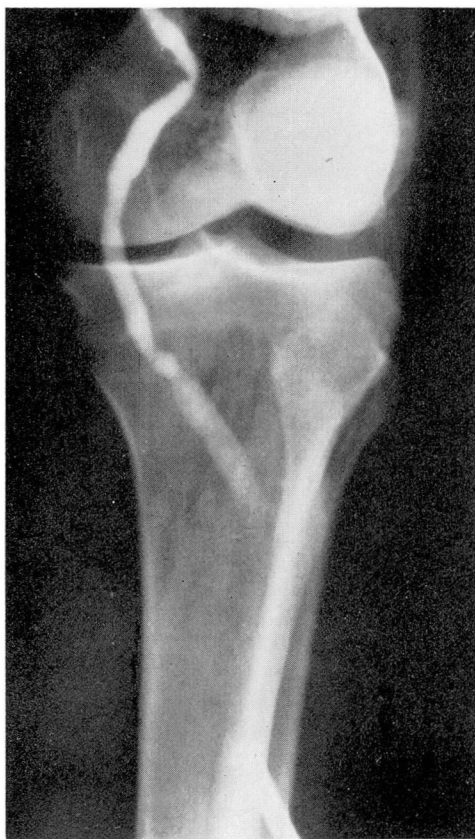

FIG. 3.

Summary

A case of bilateral popliteal aneurysm has been presented.
A venous homograft was successfully employed on one side.

References

1. Hufnagel, C. J.: Popliteal aneurysm: 2 cases. *M. Bull. Vet. Admin.* **20**:86-90 (July) 1943.
2. Theis, F. V.: Popliteal aneurysms as cause of peripheral circulatory disease: with special study of oscillomographs as aid to diagnosis. *Surgery* **2**:327-342 (Sept.) 1937.
3. Theis, F. V.: Peripheral arterial aneurysm: diagnosis, prognosis, and treatment. *Internat. Clin.* **2**:205-216 (June) 1940.
4. Keynes, G. L. and Morel, M. P.: Popliteal aneurysm. *Brit. J. Surg.* **31**:155-157 (Oct.) 1943.
5. Blakemore, A. H.: Amputation for aneurysms. *S. Clin. North America* **18**:409-414 (April) 1938.
6. Wells, A. H., Coburn, C. E. and Walker, M. A.: Popliteal aneurysm, with report of case. *J.A.M.A.* **106**:1264-1266 (April 11) 1936.
7. Flemming, C.: Aneurysm of both popliteal arteries. *Lancet* **1**:322-323 (Feb. 11) 1939.
8. Matas, R.: Endo-aneurysmorrhaphy. *Surg., Gynec. & Obst.* **30**:456 (May) 1920.
9. Bird, C. E.: Sympathectomy as preliminary to obliteration of popliteal aneurysms. *Surg., Gynec. & Obst.* **60**:926-929 (May) 1935.
10. Gage, M.: The development of the collateral circulation in peripheral arterial aneurysms by sympathetic block. *Surgery* **7**:792-795, 1940.
11. Richards, R. L. and Learmonth, J. R.: Lumbar sympathectomy in treatment of popliteal aneurysm. *Lancet* **1**:383-384 (March 28) 1942.
12. Linton, R. R.: Arteriosclerotic popliteal aneurysm; 14 patients treated by preliminary lumbar sympathetic ganglionectomy and aneurysmectomy. *Surgery* **26**:41-58 (July) 1949.
13. Lilly, G. D.: Management of aneurysms of lower extremities. *Ann. Surg.* **123**:601-609 (April) 1946.
14. Blakemore, A. H.: Restorative endo-aneurysmorrhaphy by vein graft inlay. *Ann. Surg.* **126**:841-849 (Dec.) 1947.
15. Julian, O. C., et al.: Direct surgery of arteriosclerosis. *Ann. Surg.* **136**:459 (Sept.) 1952.