

MARGINAL ULCER FOLLOWING GASTRIC RESECTION FOR BENIGN GASTRIC ULCER

A Case Report

CHARLES H. BROWN, M.D.
Department of Gastroenterology

and

STANLEY O. HOERR, M.D.
Department of Surgery

THE development of a marginal ulcer following gastric resection of a *gastric* ulcer is unusual. Balfour, cited by Bockus,¹ reported that marginal ulcer occurred 20 times more frequently after operations for duodenal ulcer than after surgery for gastric ulcer. Kiefer² obtained follow-up studies on 49 patients with gastric ulcers subjected to subtotal gastrectomy, and found no evidence of recurrence in any of the patients. Of 146 patients with duodenal ulcer and 27 patients with jejunal ulcer subjected to gastric resection, 6 or 3.4 per cent developed marginal ulceration as proved at subsequent operations. Bockus¹ reported that marginal ulceration rarely occurred even after a gastrojejunostomy was performed for gastric ulcer. Ranson³ followed 188 patients who underwent gastric resection for gastric ulcer and found that only 4 had developed marginal ulcers. In at least 2 and possibly 3 of the patients the antrum was not removed, a Finsterer operation having been performed. The presence of the antrum, with the continued secretion of the antral hormone as shown by Dregstedt, can predispose to the development of an anastomotic ulcer. In none of the 4 patients with a marginal ulcer was a Bilioth I type of procedure done.

The occurrence of a marginal ulcer is dependent on gastric acidity and the presence of free HCl, just as any peptic ulcer. Klein et al⁴ found that immediate postoperative anacidity was present in 77 per cent of patients with gastric ulcer following resection, and in only 38 per cent of patients with duodenal ulcer who had resections done. Kiefer² measured gastric acidity in 30 patients with gastric ulcer subjected to resection and found a small amount of free HCl in only 3 of the 30 patients.

From the pathologic physiology of peptic ulcer, it is logical that marginal ulceration should occur less frequently after operations for gastric ulcer than following surgery for duodenal ulcer. Levin et al,⁵ and many others, have shown that patients with duodenal ulcer are "hypersecretors," have increased gastric acidity, and continued nocturnal secretion of hydrochloric acid. Conversely, Levin et al⁶ have shown that patients with gastric ulcer have normal or subnormal gastric acidity. One would expect fewer occurrences of marginal ulcer following operations in the group of patients with low acid values (gastric ulcer group) than in the group evidencing high acidity (duodenal ulcer group).

The location of the anastomosis between the stomach and the small bowel is another factor in the development of an anastomosis ulcer. Gastroileostomies,^{7,8} performed mistakenly, show a high incidence of marginal ulcer. The lower the anastomosis is made between the stomach and the small bowel, the greater the likelihood of a marginal ulcer; conversely, the higher in the small intestine the anastomosis is made, the less likely the development of marginal ulcer. The alkaline duodenal contents have the greatest chance to neutralize the acid gastric chyme with the high anastomosis. Consequently, one would not expect an anastomotic ulcer to develop following a Bilroth I procedure done for gastric ulcer.

We are presenting the case of a patient who had an 80 per cent gastric resection with a Bilroth I procedure for a large penetrating gastric ulcer on the posterior wall; he subsequently developed a marginal ulcer that healed promptly on intensive medical treatment.

Report of a Case⁹

A 66 year old man came to the Cleveland Clinic September 11, 1950, with the complaint of epigastric pain relieved only occasionally by food and usually requiring "pain pills" of 10 months' duration. He had lost 12 pounds in weight. Complete examinations elsewhere, including gastrointestinal roentgen examinations, had been entirely negative in February and April.

On general physical examination, his weight was 112 pounds, and his blood pressure 100/60. No masses were present in the abdomen, and general physical examination was noncontributory. Laboratory studies showed the hemoglobin to be 12.5 Gm., white blood cell count 7,450 per cubic mm., and stools negative for blood. Gastric analysis with alcohol as a stimulant showed 12 units of free HCl and 22 units of total acidity. Urinalysis, bromsulphalein liver function test, serum proteins, serology, blood sugar and serum amylase were either normal or negative. Roentgenograms of the chest, sinuses, gallbladder and colon were negative except for left maxillary sinusitis and osteoarthritis of the spine. However, x-ray examination of the stomach revealed a large ulcer measuring 3 cm. in diameter on the posterior aspect of the stomach. There was slight indentation of the margins, suggesting possible meniscus sign. On gastroscopic examination the ulcer was visualized midway between the lesser and greater curvatures; the edges of the ulcer did not appear sharply delineated, and the base was filled with dirty, gray material and some old blood. The gastroscopic appearance suggested possible malignancy (fig. 1a and b).

The location of the ulcer on the posterior wall, the atypical history with relatively recent onset of symptoms, the low gastric acidity, the suggestive meniscus sign on roentgen study, the size and location of the ulcer, and the gastroscopic appearance all indicated the possibility of malignancy. Consequently, the patient was advised to undergo surgery, and was operated upon on September 25, 1950. At operation, a gastric ulcer on the posterior wall midway between the greater and lesser curvatures was found, with penetration into the pancreas. A gastric resection, with a Bilroth I procedure, was done, the ulcer bed being left on the pancreas. Eighty per cent of the stomach, including the antrum and pylorus, was resected, and the duodenum was anastomosed to the resected end of the stomach (fig. 2).

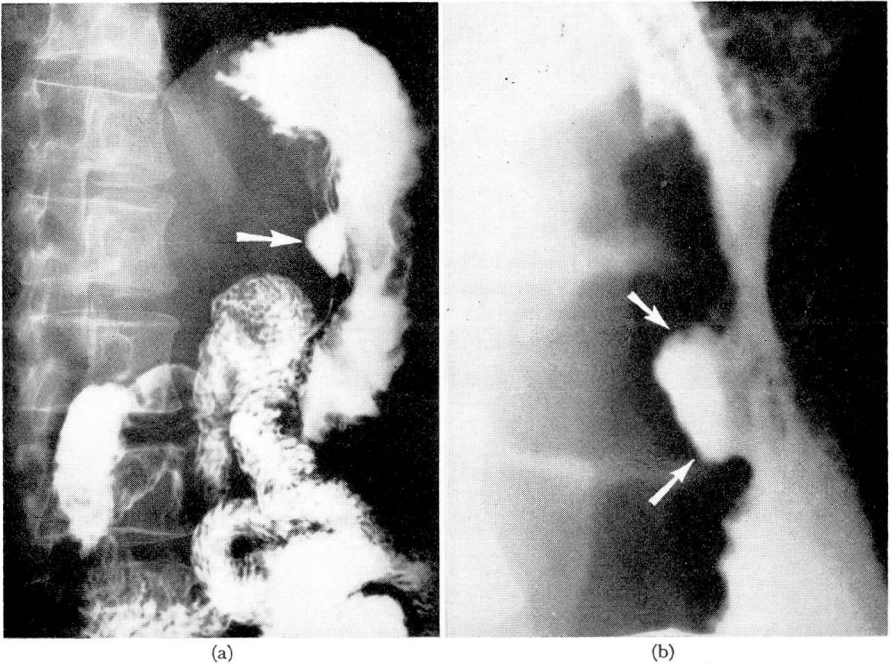


FIG. 1. (a) Large gastric ulcer on lesser curvature and posterior wall; seen on survey film. (b) Spot film of large gastric ulcer. Note some irregularity of the proximal border of the ulcer (2 arrows) and suggestions of overhanging edges at the interior margin (1 arrow) suggesting possibility of malignancy.

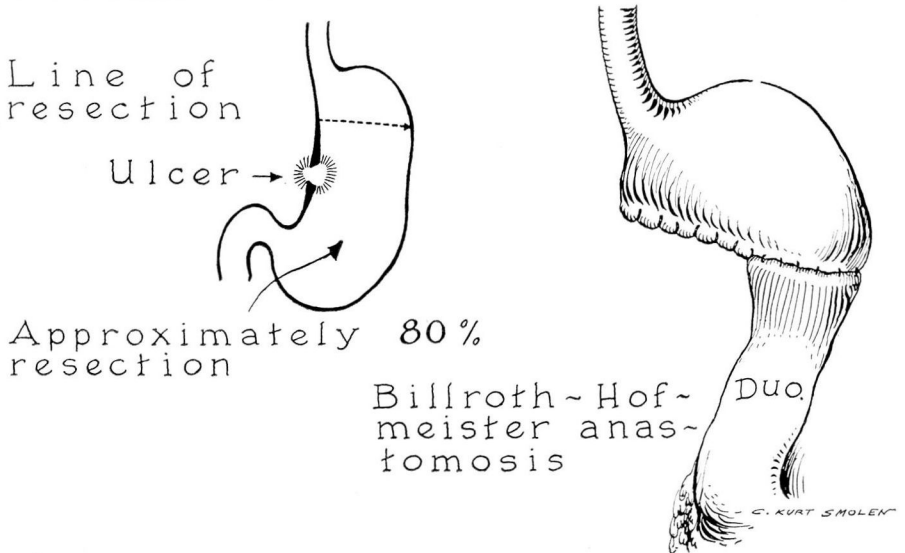


FIG. 2.

Pathologic examination revealed the surgical "perforation" of the stomach 2 cm. in size where the ulcer bed had been left behind. Microscopic sections showed that the ulcer margin had typical zones of peptic digestion. There was no evidence of neoplasm and no atypical cells were seen.

The patient made an uneventful recovery, and was discharged from the hospital October 7, 1950. He returned 5 months later. At that time he had no ulcer distress, but demonstrated mild dumping symptoms with palpitation and nausea 10 to 15 minutes after eating.

He returned again on September 20 and reported that he had experienced ulcer-type distress, commencing before meals and relieved by food, following a sore throat six weeks previously. He had neither vomited nor noted tarry stools. Roentgenograms of the stomach showed the distal two-thirds of the stomach had been resected and the remaining portion anastomosed to the duodenum. Immediately distal to the anastomosis, an ulcer crater approximately 1 cm. in size was visualized and appeared to lie in the duodenum or along the line of the anastomosis (fig. 3a and b).

Because of the unusual occurrence of marginal ulcer following an 80 per cent resection for *gastric* ulcer, particularly a Bilroth I procedure in which the gastric acid is neutralized immediately on entering the duodenum, and because of the low gastric

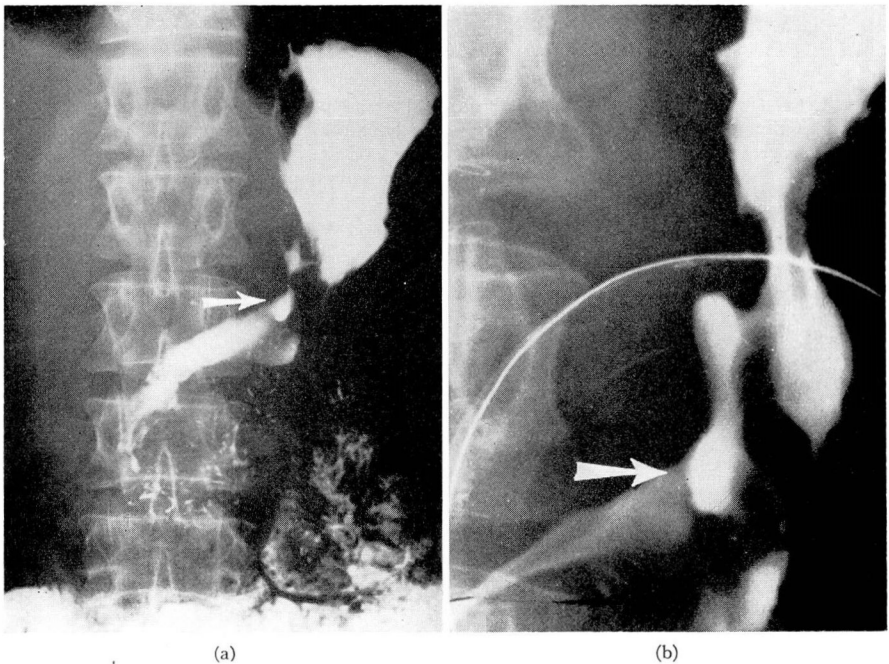


FIG. 3. (a) Survey film showing marginal ulcer (arrow). The collection of barium above the ulcer is probably in a pocket caused by spasm from the ulcer. (b) Spot film showing the marginal ulcer.

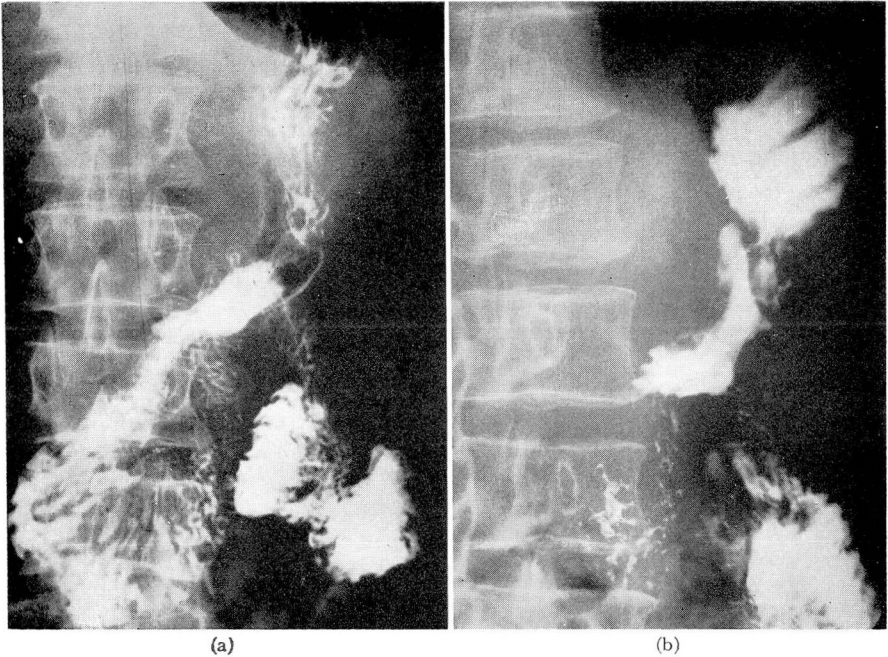


FIG. 4. (a) Large film showing no evidence of marginal ulcer. (b) Another view showing no evidence of marginal ulcer. Repeated films on progress visits failed to demonstrate any sign of previously described ulcer.

acidity of the patient, we elected to treat the marginal ulcer medically. He was given a bland diet, allowing meat, with food or milk every two hours on the even hours, and was asked to take two drams of an aluminum hydroxide preparation every two hours on the odd hours. Coffee, tea and alcohol were forbidden, and an anti-cholinergic (*Prantal-100 mg. qid.) and vitamin B capsules were prescribed.

The patient followed the suggested hourly ulcer schedule and returned 5 weeks later. He reported immediate relief from his ulcer distress on this regimen and subsequent freedom from symptoms. On progress roentgen examination the previously observed ulcer crater could not be visualized. At this time the patient's diet was enlarged to to include fresh fruits and vegetables, but he was kept on the hourly ulcer schedule with food or milk on the even hours and anti-acids on the odd hours.

He returned again two-and-one-half months later and reported continued freedom from ulcer distress. Roentgen examination of the stomach again showed a normal functioning gastroduodenostomy with no evidence of an anastamotic ulcer. At this time he was placed on a modified ulcer program with a liberal diet—milk two hours after meals and anti-acids one hour after meals and at bedtime. He had remained free of ulcer distress when last contacted July 8, 1952 (fig. 4a and b).

*Kindly supplied by Schering Corporation.

Summary

It is rare for a marginal ulcer to develop following a gastric resection for *gastric* ulcer.

The case of a patient with a large posterior wall benign gastric ulcer has been presented. At operation the ulcer was found to have penetrated the pancreas and an 80 per cent gastric resection with a Bilioth I procedure was performed. Pathologic examination showed the ulcer to be benign. Approximately one year later the patient developed typical ulcer symptoms and a large marginal ulcer was demonstrated by roentgen examination. He was placed on intensive medical treatment for the ulcer, and progress examinations five weeks and three-and-three-fourths months later showed the ulcer to have healed completely. This case demonstrates the fact that marginal ulceration may heal with intensive medical treatment.

References

1. Bockus, H. L.: *Gastro-Enterology*. Vol. 1, page 617, W. B. Saunders Co., Philadelphia, 1946.
2. Kiefer, E. D.: Jejunal ulcers and recurrent hemorrhages after partial and subtotal gastrectomy for peptic ulcer. *J.A.M.A.* **120**: 819-824 (Nov. 14) 1942.
3. Ranson, H. K.: Subtotal gastrectomy for gastric ulcer; a study of end results. *Ann. Surg.* **126**:633-654 (Nov.) 1947.
4. Klein, E., Aschner, P. W. and Crohn, B. B.: End-results of partial gastrectomy for primary gastric and duodenal ulcers. *Trans. of the Am. Gastroenterol. Assoc.*, 36th Annual meeting. **197**:205, 1933.
5. Levin, E., Kirsner, J. B., Palmer, W. L. and Butler, C.: Comparison of nocturnal gastric secretion in patients with duodenal ulcer and in normal individuals. *Gastroenterology* **10**:952-964 (June) 1948.
6. Levin, E., Kirsner, J. B., Palmer, W. L. and Butler, C.: Nocturnal gastric secretion: studies on normal subjects and on patients with duodenal ulcer, gastric ulcer and gastric carcinoma. *Arch. Surg.* **56**:345-356 (March) 1948.
7. Brown, C. H., Colvert, J. R. and Brush, B. E.: Gastro-ileostomy, rare surgical error: symptoms and x-ray findings. *Gastroenterology* **8**:71-81 (Jan.) 1947.
8. Michels, A. G., Brown, C. H. and Crile, G. Jr.: Surgical error of gastroileostomy; report of six cases. *Am. J. Surg.* **82**:191-197 (Aug.) 1951.
9. Hoerr, S. O.: Discussion, *Surgery* **32**:435, 1952.