

THE SPLIT SKIN GRAFT

ROBIN ANDERSON, M.D.

Department of Plastic Surgery

EIGHTY-THREE years have passed since Reverdin described the first practical approach to the autogenous free grafting of human skin. He proposed the use of small thin bits of skin later known as "pinch grafts." Ollier and Thiersch, in 1872 and 1874 respectively, grafted larger pieces of very thin split skin, thus enlarging somewhat the scope of the graft's usefulness. There is little in the literature to suggest that skin grafts were especially popular from a surgical standpoint during the next 50 years. However, in 1929, Blair and Brown¹ introduced the thick split graft, and demonstrated vast possibilities for its use. Since then, the split skin graft has become increasingly valuable, not only to the plastic surgeon, but to the general surgeon as well. Developments in recent years have consisted mainly of ingenious machines to cut skin of uniform thickness, and at the same time eliminate much of the need for skill required in free-hand cutting of skin. The most notable of these is the Padgett dermatome,² which was first used in 1938 and has remained to date as the most generally useful of these instruments.

There has been a tendency in some circles to surround the grafting of skin with considerable mystery, and to suggest that grafts will "take" only for specially endowed surgeons. At the same time, surgeons are often perfectly satisfied with the survival of half or two-thirds of a graft. Both of these attitudes are regrettable. A skin graft of suitable thickness, placed on a properly prepared bed and held there by means of an adequate dressing, should survive in its entirety. Partial or complete failure of "take" is almost always due to surgical error.

Technic

The skin is an organ of characteristic structure, consisting of an actively proliferating epidermis lying superficial to a tough, fibrous layer known as the dermis. The variation of skin thickness in different areas of the body is due mainly to the amount of dermis present. Actual measurements of skin thickness are misleading since individual variation is great. The essential point to be kept in mind by the surgeon cutting a skin graft is that he is limited as to the thickness of the graft he can take by the skin thickness of his donor site. The most common donor sites are lateral and posterior thigh, and buttock, where the skin is only slightly thinner than that of the back. Next in thickness are the skin of chest and abdominal wall, and finally the medial aspect of the thigh. When the necessity arises, there is, of course, no area which cannot be used as a donor site.

The question is frequently asked as to whether a thick or thin graft should be used. This is best answered as follows. It is generally true that the thinner

the graft, the better the chance of perfect take, particularly in the presence of contamination or poor vascularity. Conversely, the thicker the graft, the better the ultimate result in terms of minimum contracture, skin flexibility, minimum pigmentation, and durability. Therefore the thick graft, if it will take, is the graft of choice. Needless to say, if in doubt, one should err on the thin side.

1. Preparation of the recipient site

The clean, relatively aseptic bed produced by removing a scar or tumor, or following an avulsive injury, is ready for application of the graft. Hemostasis must be perfect; a weak adrenalin sponge may be useful in drying up annoying capillary oozing. The bed must be well vascularized, without scar, cortical bone or other material which will not nourish the graft.

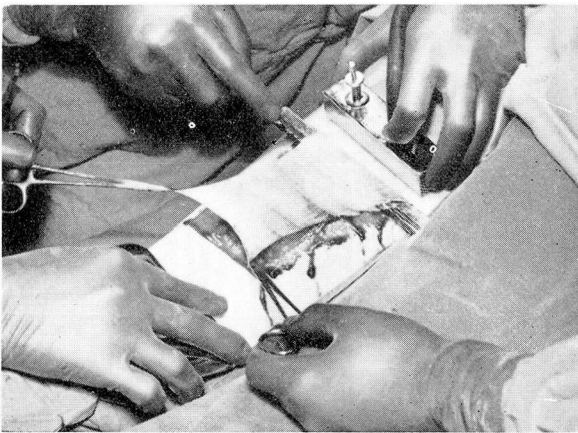


FIG. 1. In actual practice the graft is allowed to lie free; it is stretched above to show its relationship to the donor site.

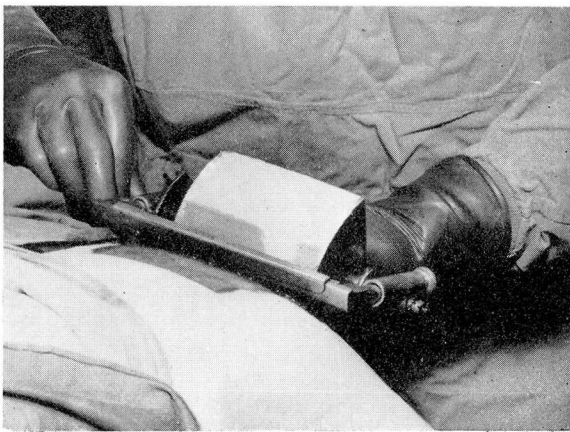


FIG. 2. The drum is rotated upward to maintain correct cutting plane.

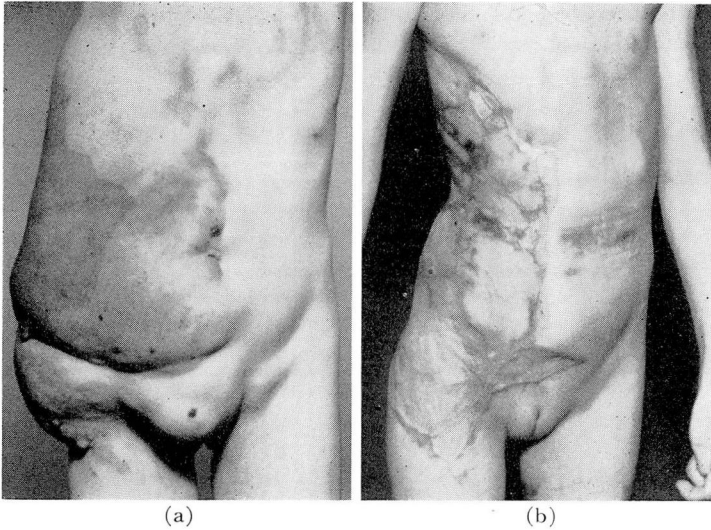


FIG. 3. (a) Preoperative view. (b) Postoperative view.

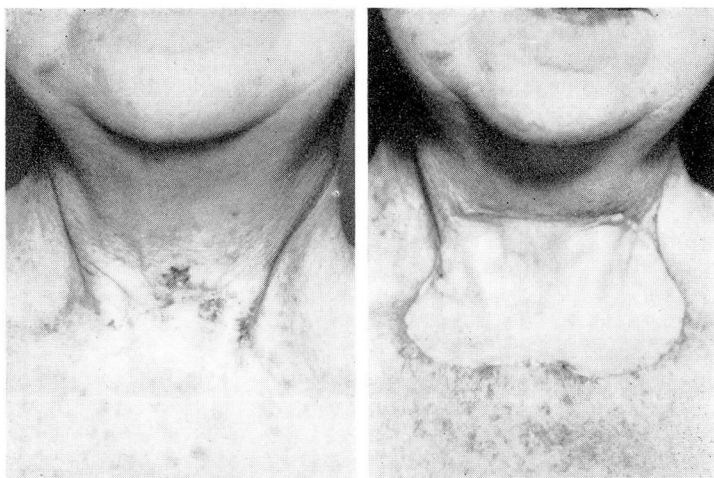The dirty wound requires considerable preparation. Infection is combated by antibiotics administered parenterally or orally. The local wound is debrided frequently and dressed at least daily with saline dressings over nongreased fine-mesh gauze. Moderate pressure over mechanics' waste or other padding will flatten granulations and reduce local edema. Grafting should not be carried out until drainage is minimum, necrotic tissue is absent and granulations are pink and flat. These granulations may be left untouched or may be shaved off with a sharp knife just prior to application of the graft. In the case of a chronic ulcer with underlying fibrosis, the debridement is completed in the operating room with removal of all avascular tissue.

It should not have to be mentioned that the patient's general health and nutritional state are most important in obtaining a good result. These are carefully investigated at the onset of treatment. Any deficiencies in either are corrected.

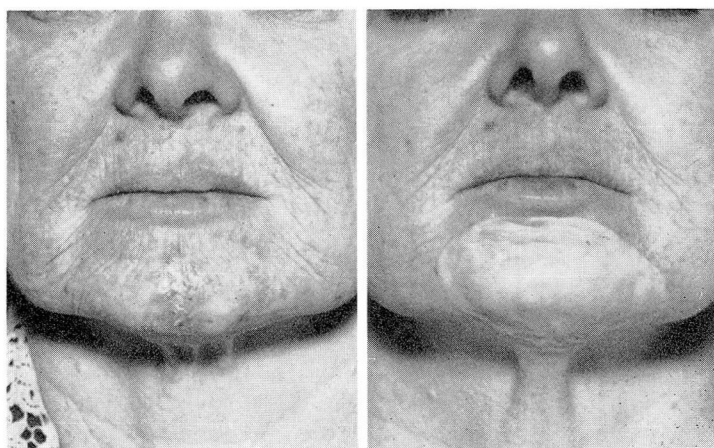2. Cutting the graft

While many instruments are available for cutting a split skin graft, the two most common are the free-hand knife and the Padgett dermatome. The free-hand knife has the advantages of being inexpensive, readily available, mechanically foolproof, and permitting the rapid cutting of skin. However, it is difficult to cut a perfectly uniform graft by hand, particularly if it must be thick. The dermatome, which is calibrated and set to cut skin of precise dimensions, eliminates this disadvantage.

For satisfactory free-hand cutting, two requirements must be met. First, the skin must be held taut in such a manner as to present a firm surface to the knife edge, and, second, the knife must be razor-sharp. The suction box shown in figure 1 provides an excellent means of meeting the first of these, although



(a) (b)
FIG. 4. (a) Preoperative view. (b) Postoperative view.



(a) (b)
FIG. 5. (a) Preoperative view. (b) Postoperative view.

a straight edge with counter traction by a second straight edge will do almost as well. The Ferris Smith knife with inexpensive replaceable blades is a satisfactory answer to the second requirement. These blades can be sharpened, but should be discarded if the cutting edge is not perfect. It will be immediately obvious to the surgeon taking the graft if the blade is not razor-sharp. No one can cut a good graft with a dull knife.

The skin is greased with a thin layer of vaseline to provide a seal between skin and suction box. The knife is held flat against the skin half an inch or so

away from the box, and moved in a constant plane, following the box. A little practice makes this a simple maneuver. The thickness of the graft is obvious as it is being cut; its size and shape are limited only by the donor site and the skill of the operator. As the graft is cut, the portion already free should be allowed to lie loosely behind the knife, or supported with forceps only enough to keep the cutting edge visible. Any tension at this point will result in the loss of the correct cutting plane.

When using the dermatome, a good knife blade is equally necessary. The arm is adjusted to the desired thickness, usually .015 to .025 inch, drum and donor site are cleansed with ether, and both are rapidly painted with a thin coat of dermatome cement. This cement must be thin; if too thick, it may be thinned with ether. After allowing the cement to dry for several minutes, the leading edge of the drum is held firmly against the skin for thirty seconds. The graft is then cut as the drum is rolled upward (fig. 2). Here again some practice will be necessary to cut a full drum of skin. The skin is grasped at its corners with hemostats and stripped from the drum. If cement remains on the skin, a little Biosorb will destroy its stickiness.

The graft may be kept in a sponge moistened with saline until ready for use.

3. Application of the graft

The graft is laid on the prepared bed without tension, and spread into position by gentle sweeps of the smooth handle of a thumb forceps. Interrupted or continuous fine silk is used to fix the graft to surrounding skin; some overlap of the graft beyond the recipient bed edge helps keep the graft in proper position. It is not necessary to "pie crust" the graft, that is, provide holes through which blood will presumably escape. The value of this procedure is strictly theoretical, and contributes nothing to a successful take. Much more important is frequent checking to be certain that flawless hemostasis is maintained.

A meticulously applied dressing will provide immobilization and maintain perfect contact between the graft and its bed. Fine mesh vaseline gauze is placed on the graft and covered with voluminous padding of mechanics' waste, fluffed gauze or abdominal pads. Moderate pressure is established by elastic or plain bandage, or Elastoplast if a circular bandage is not applicable. Immobilization and elevation of a grafted extremity are essential until the graft is well vascularized in its new bed.

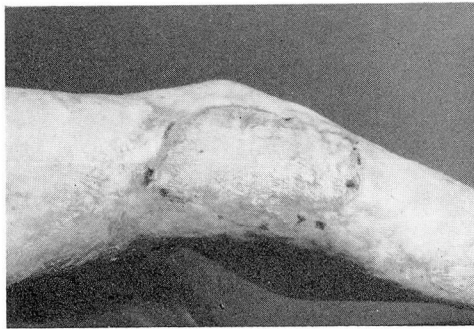
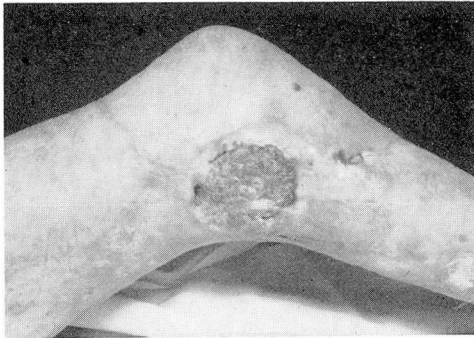The donor site is similarly dressed with considerable pressure. If left untouched, it will usually be completely epithelialized from the proliferation of hair follicle and gland epithelium within 2 weeks after operation.

4. Postoperative care

Antibiotics are administered prophylactically, at least until the first post-operative dressing. This is carried out on the third or fourth day if the grafted wound was dirty, or the fourth or fifth day if it was clean. Superficial blebs containing serum are opened, and small collections of blood, if any, beneath the graft are evacuated through small incisions. The graft is trimmed as necessary, cleansed gently with soap and water, and redressed with moderate

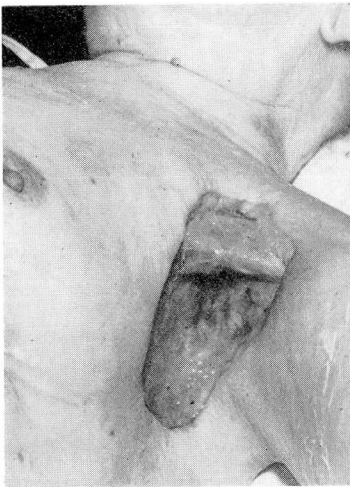SPLIT SKIN GRAFT

(a)

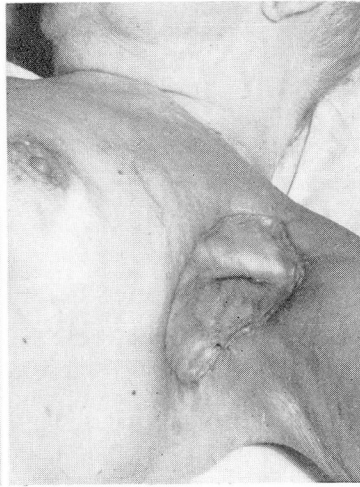

(b)

FIG. 6. (a) Preoperative view. (b) Postoperative view.



(a)



(b)

FIG. 7. (a) Preoperative view. (b) Postoperative view.

pressure. Meticulous care at this stage is just as essential as at the time of grafting.

Further dressings are done every other day or daily, with removal of sutures on the sixth or seventh day. By the tenth day the dressing usually can be reduced in size, and at 2 weeks need be no more than protection from accidental trauma. Once the dressing is off, daily soap and water cleansing, and a little lanolin or vaseline on the graft will be sufficient. If the grafted area is over or near a joint, motion is started on or about the tenth day unless the graft's survival is still in doubt.

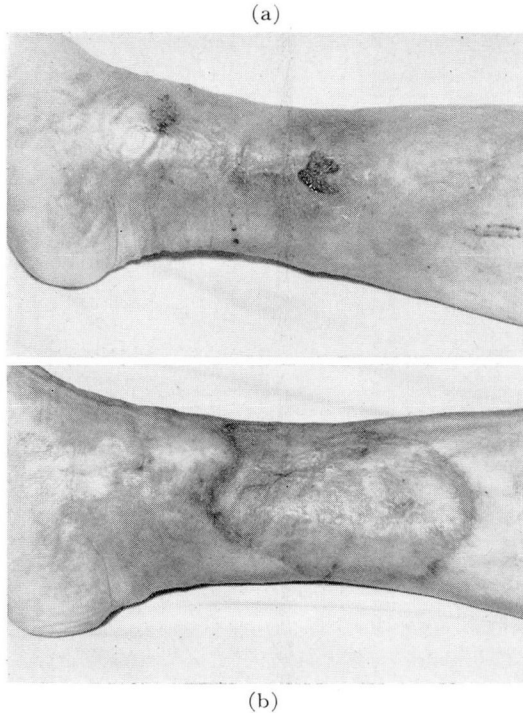


FIG. 8. (a) Shows incisions through which varicose veins had been previously excised, above and below the ulcer. (b) Postoperative view.

Specific Uses of Split Skin Grafts

The split graft may be used for the covering of any defect for which a protective pad of subcutaneous tissue is not essential. The sole of the foot, areas with exposed tendons or bony prominences which cannot be removed, fracture sites in which additional surgery will be carried out beneath a graft, and the like, are best repaired with pedicled skin flaps carrying their own soft tissue and blood supply. However, if the surgical situation is such that immediate coverage of a defect is necessary, even these areas may be grafted with split skin as a temporary expedient.

Applications of the split graft fall roughly into two general classifications: (1) The covering of large areas denuded of skin, in which the problem is the saving of life or prevention of major deformity rather than cosmetic; (2) the repair of defects, usually operative following removal of a scar or tumor, or post-traumatic, for which primary closure is either impossible or impractical.

In the first of these categories lie burns and massive avulsive injuries such as those seen in the condition known as "wringer arm."³ In these, while it might be preferable to provide better soft tissue replacement or to use full-thickness skin in potentially traumatized areas, the necessity of obtaining rapid coverage of raw surfaces takes precedence over functional and cosmetic considerations. If necessary, split grafts may be replaced by pedicled or full-thickness skin at a later date when the survival of the patient is no longer the primary problem. In the case of a third degree burn, grafting with split skin cannot be carried out until a satisfactory granulating bed is available, usually

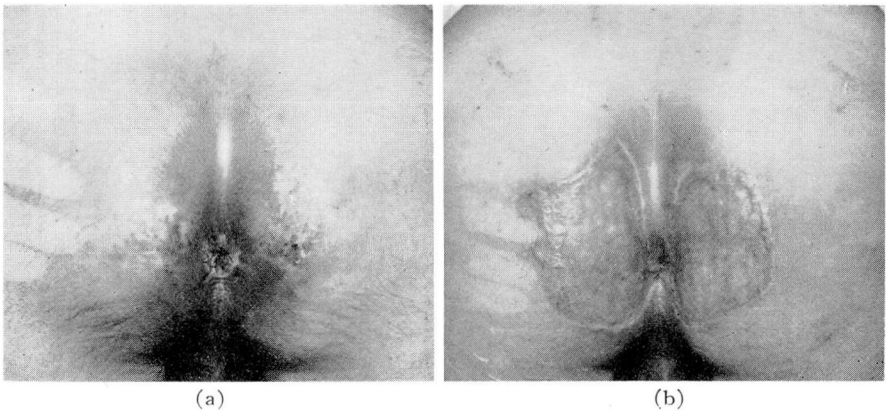


FIG. 9. (a) Initial lesion was pruritus ani for which considerable radiation therapy was given. Note prints in the skin of patient's fingers used to retract buttocks. (b) Postoperative view.

3 to 4 weeks after the initial injury. Grafts may be applied immediately to the healthy recipient site produced by avulsive trauma or surgery.

A typical example of this use of the graft is seen in figure 3. This child had an extensive cavernous hemangioma, rapidly approaching a size incompatible with life. Following excision, the defect which extended from axilla to groin and midline to midline was completely covered with split skin. It is interesting to note that this child's general condition, which was critical at the time of surgery, improved spectacularly as soon as skin replacement was carried out.

In the second group of uses of the split graft are found those instances in which the graft is the permanent covering material of choice. Figures 4 and 5 demonstrate the replacement of areas of radiation damage on the neck and face by split skin. In each case the results from both functional and cosmetic standpoints are considered satisfactory. Figure 6 shows an ulcerating carcinoma in a chronically irritated burn. A thin graft was placed on a rather poorly

vascularized base following radical excision of the lesion. The graft took well and has provided adequate coverage. In figure 7 is shown the defect remaining after radical excision of a tuberculous ulcer and associated deep scar. The function of the extremity returned to normal following skin graft and vigorous physiotherapy.

The treatment by split grafting of a typical postphlebotic leg ulcer is shown in figure 8. In this instance, the graft was laid directly on cancellous bone after removal of sclerotic cortex.

Split skin proves excellent replacement for damaged skin of the buttocks and perineum. Despite constant contamination there is little danger of infection, and grafts usually take without difficulty (fig. 9).

While defects of the palm are best covered with full thickness skin, an unusually thick split graft in many instances offers a comparable result and has a slightly better chance of surviving. Figure 10 shows such a graft in the palm;

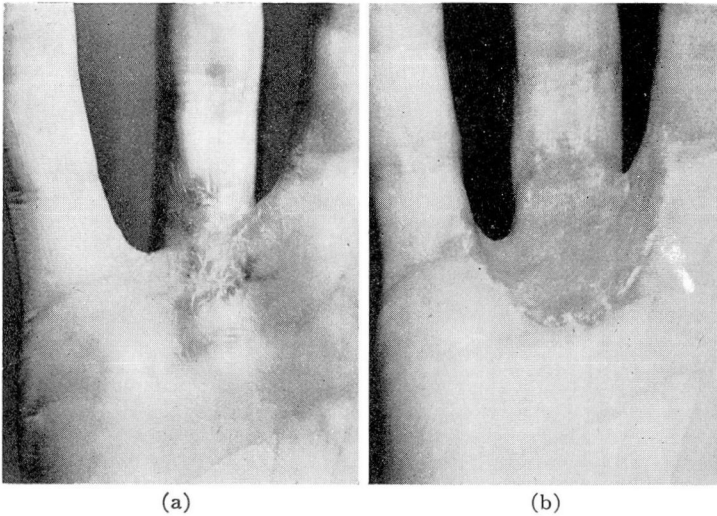


FIG. 10. (a) Preoperative view. (b) Postoperative view.

6 months postoperatively, the graft is soft and freely movable and does not interfere with the function of underlying structures.

Among less common applications of the split graft are its uses as lining for a buccal sulcus,⁴ covering for the serosal surface of the bowel in the construction of an ileostomy, and as replacement for lost mucous membrane of the orbit.

In brief, a split skin graft can be applied wherever its proposed bed has sufficient vascularity to provide nourishment for the graft. Specific functional and cosmetic considerations are the only limitations to its use.

Summary

1. The technics of cutting, applying and caring for the split skin graft have been described.
2. A brief survey of its various applications has been presented.

References

1. Blair, V. P. and Brown, J. B.: Use and uses of large split-skin grafts of intermediate thickness. *Surg., Gynec. and Obst.* **49**:82 (July) 1929.
2. Padgett, E. C.: Calibrated intermediate skin grafts. *Surg., Gynec. and Obst.* **69**:779 (Dec.) 1939.
3. MacCollum, D. W.: Wringer arm; report of 26 cases. *New England J. Med.* **218**:549 (March 31) 1938.
4. Brown, J. B. and McDowell, F.: *Skin Grafting*, ed. 2. Philadelphia, J. B. Lippincott Co., 1949.