

CANCER OF THE FACE AND MOUTH

ROBIN ANDERSON, M.D.
Department of Plastic Surgery

THE problems of diagnosis and treatment of malignancies of the face and mouth differ from those encountered in the management of neoplasms elsewhere in the body. Early diagnosis is the rule rather than the exception, since face and mouth lesions are usually noticed by the patient early in their course, and readily found by the examining physician. Therapy is complicated by the facial features and functioning organs whose involvement and removal may produce major cosmetic and functional deformity. Despite these differences, the application of sound surgical principles is the basis of treatment; the initial lesion must be eradicated as early in the course of the disease as possible, with removal of regional sites of metastasis when indicated. The only limitation to radical therapy is the production of cosmetic or functional deformity incompatible with a reasonably satisfactory existence.

Two modes of treatment are available: irradiation and surgery. These should not be considered antagonistic since the size, location and radiosensitivity of a given lesion may demand the use of one or the other, or both, to offer the best possibility of cure. For example, irradiation in the form of interstitial radon or radium gives excellent results when used for most intraoral lesions which, in general, are highly radiosensitive. Surgical removal of the same lesions may be difficult and often less satisfactory. In the management of metastatic cancer in the neck, however, the value of irradiation remains unestablished, and surgery is the treatment of choice. Many lesions, particularly of the face, may be adequately treated by either method with comparable results.

In the surgical excision of face and mouth neoplasms, the knife is usually preferable to the cautery, and is essential if any type of primary repair is to be carried out. However, the cautery may be useful in the removal of large tumors, particularly within the oral cavity where bleeding may be severe and difficult to control. While the third degree burn produced by the cautery makes primary wound closure impossible, it also provides a poor bed for the surgical implantation of tumor cells.

The general problem of diagnosis and treatment of cancer of the face and mouth may be divided into five categories. First, any patient over the age of forty with a lesion of the face or within the mouth, the identity of which is not obvious, should be presumed to have cancer until proved otherwise. He should be examined carefully, particular attention being given to possible sites of metastasis. An enlarged lymph node in the adult, in the absence of obvious infection, is probably not inflammatory. Second, a biopsy or, in the case of small tumors, biopsy excision, is a necessity requiring the assistance of an experienced pathologist. However, it must be remembered that a negative

biopsy report does not exclude the presence of cancer, since malignant tissue may occupy only a small portion of the lesion. Third, with the diagnosis of malignancy established, vigorous therapy is undertaken. If the primary disease is not controlled, one cannot expect to treat its metastases successfully. Fourth, an evaluation is made of the lymph nodes draining the area of the primary cancer. If there are palpable nodes, regional block dissection is probably indicated. If involved glands are clinically absent, a decision must be reached as to the advisability of regional dissection on the basis of possible undetected involvement, or the probability of future metastasis. Such prophylactic dissections are carried out most frequently for cancers of the tongue and floor of the mouth. Fifth, after the cancer and any existing metastases have been presumably destroyed, the patient is examined at monthly intervals for at least a year, and every 3 months for several years thereafter. Any departure from this follow-up program must be considered disastrous and is undoubtedly the cause of many avoidable deaths.

Cancer of the Skin

The statement is often made that cancer of the skin is not a serious disease. This is true only from the standpoint of its rate of progression when compared to most other cancers. If allowed to advance to the point of major local destruction or metastasis it becomes a ruthless killer. Fortunately in its early stages it is amenable to eradication and has an excellent chance of permanent cure. Excision of the entire lesion either by means of the knife or the cautery is adequate therapy. On the face, the most common type of neoplasm is the basal cell cancer, often preceded by a long history of roughness, scaliness and ulceration. The more dangerous squamous variety of carcinoma appears less frequently, although it is not uncommon in or near a mucocutaneous junction.

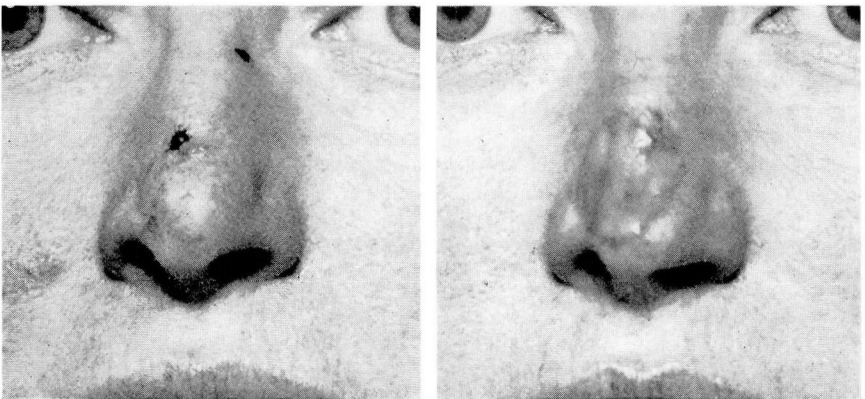

FIG. 1. Squamous carcinoma of nose with ulceration and invasion of cartilage. Lesion and cartilage excised; defect covered with full-thickness skin graft.

The rare "basal-squamous" or mixed carcinoma behaves like its malignant component.

Irradiation of a small, isolated face cancer is adequate in most cases, when carried out by a qualified radiologist. However, lesions of the ear or tip of the nose, where cartilage is close to the site of therapy, are best treated by surgical excision to avoid chondritis or necrosis of underlying cartilage. Tumors of the eyelids, the irradiation of which might produce associated eye damage, should also be excised. In any case, if irradiation is to be the treatment of choice, it must be limited to a single course of therapy. If control is not obtained, the chance of cure by a second attempt is slight and the probability of severe local radiation injury greatly increased. Furthermore, valuable time is lost during which uncontrollable extension or metastasis may take place.

Small lesions are usually amenable to surgical removal without the production of deformity. However large excisions, particularly those in which a prominent feature such as full-thickness cheek or the tip of the nose must be sacrificed, may leave serious cosmetic defects requiring secondary plastic procedures. In some cases the process may be extensive enough to demand neck dissection and jaw resection, removal of the entire nose, or excision of the bony orbit. Physicians often feel that such radical surgery is unjustifiable. It is important to keep in mind that a fatality is the only alternative. The final choice must be made by the patient; only rarely does the individual with far-advanced carcinoma refuse any procedure which offers a chance of saving his life.

One can expect almost 100 per cent cures following satisfactory treatment of small skin neoplasms. The prognosis becomes worse as the lesion grows, approaches mucosal surfaces, or metastasizes to regional lymph nodes.

Cancer of the Lip

Cancer of the lip is almost always squamous, and limited to the lower lip. It is ten times as common in men as in women, a phenomenon for which there is no completely satisfactory explanation. It is often preceded by a long period of chronic irritation, with prolonged exposure to sunlight a common etiologic factor. Any sore or crack in the vermillion, which remains unhealed despite reasonable therapy, should be presumed malignant.

For the early, previously untreated lesion of the lip, surgery and irradiation again provide equally good results. The type of surgical excision must be determined for each lesion. While the standard "V" makes possible a simple, cosmetic closure, it removes insufficient cancer-bearing tissue in some cases. Some lesions are so superficial that shallow removal of skin alone is adequate; others require the excision of a wide block of skin and soft tissue as far as the lower border of the mandible.

Extension and metastasis of lip cancer are not uncommon. Local progression of the disease may result in involvement requiring resection of a segment of the jaw. If the mental foramen is invaded, mandibular hemisection and disarticulation must be carried out to avoid extension through the alveolar canal. The

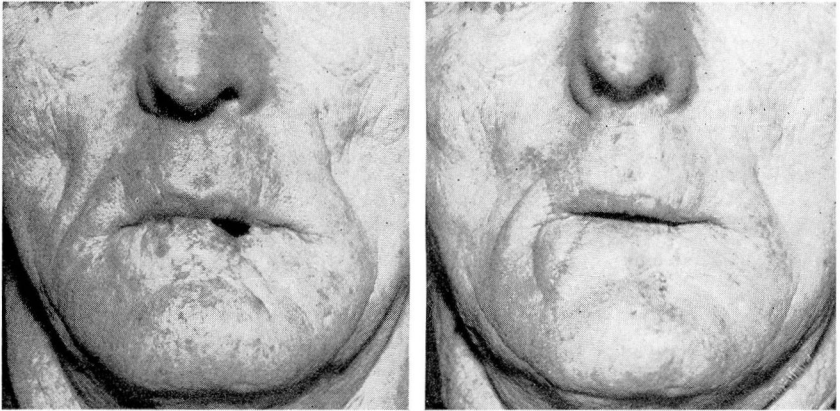


FIG. 2. Carcinoma of lip previously treated by intensive irradiation. More than half of lip excised; reconstruction carried out by transposition of pedicle from upper lip.

buccal lymph node lying near the facial artery where it crosses the mandible is often the first site of metastasis with later involvement of nodes in the neck. The treatment of such metastases is complete neck dissection. In view of the increasingly low morbidity and mortality associated with this type of neck dissection, there is little or no reason to do the more limited and questionably adequate suprahyoid or upper neck dissection.

The results of treatment of these lip cancers are excellent, with a survival rate of about 90 per cent of all treated patients for more than 5 years.

Cancer of the Oral Cavity

Cancers of the oral cavity fall into six anatomic groups: tongue; floor of the mouth; buccal mucosa; alveolar ridges; palate; maxilla and mandible. Except for tumors of the jaws, these lesions are predominantly primary squamous carcinomas. Jaw tumors may be primary, of dental or bone origin, or secondary, by extension or metastasis from other areas. The physician usually elicits the history of a sore within the mouth of relatively short duration, often associated by the patient with a tooth extraction or other disease. Syphilis, vitamin deficiencies, leukoplakia, previous irradiation, and other sources of chronic irritation such as the chewing of tobacco or heavy smoking, are frequent etiologic factors. Examination commonly reveals an ulcer with the firm edges and induration of a typical carcinoma, although ulceration may be absent. Metastatic lymph nodes are often found in the neck, particularly near the angle of the jaw.

Mouth cancers as a group progress by direct extension to adjacent structures or by metastasis. The first metastasis is usually to the deep cervical glands in the jugulo-digastric area, with subsequent metastases down the neck. Bilateral metastasis is noted occasionally, most often secondary to midline lesions of the tongue.

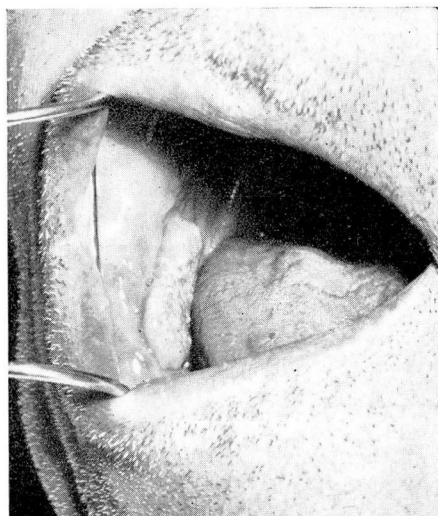


FIG. 3a. Carcinoma of buccal mucosa with extension to mandible and metastasis to neck

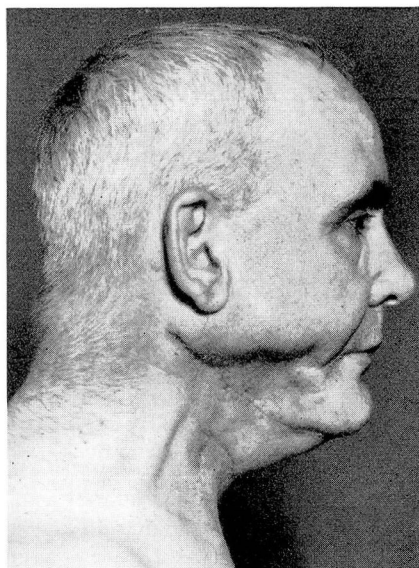
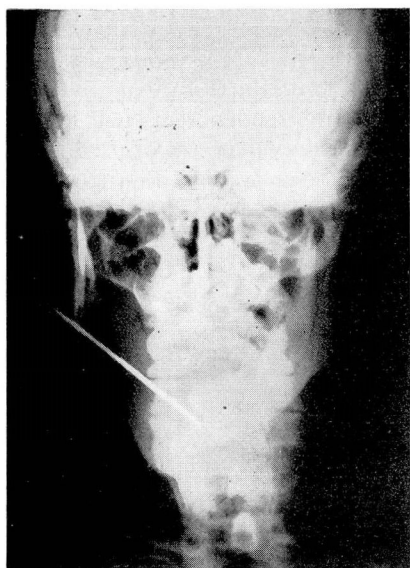


FIG. 3b. Patient treated by excision of lesion, jaw resection, and complete neck dissection in continuity. Resected segment of jaw replaced by stainless steel bar.

The treatment of these oral cancers varies with the size and location of the tumor, and the presence or probability of metastasis. Because of the difficulty of obtaining good visualization of the area of involvement, interstitial irradiation by means of radon seeds or radium needles is preferable to excision. The response of these neoplasms to such therapy is most satisfactory. Certain lesions of the jaws, or over the hard palate and alveolar ridges, are best excised or destroyed with the cautery to avoid necrosis of underlying bone. If neck metastases are already present, complete neck dissection on the involved side is indicated. Bilateral neck dissection, if necessary, carries little added risk for the patient if the internal carotid arteries are preserved. A proper neck dissection must extend from the upper border of the clavicle to above the lower border of the mandible, and from the ribbon muscles anteriorly back to the mastoid process and the trapezius muscle. The spinal accessory nerve is usually sacrificed; the hypoglossal is preserved if possible.

Prophylactic neck dissection, without palpable evidence of metastasis, is indicated for cancers of the tongue. Metastasis can be expected in 70 per cent of this group; of these, almost half will have metastasis at the time of initial examination without the presence of clinically involved glands. This alone would justify the prophylactic procedure. In addition, it has been shown repeatedly that one's chance of obtaining a cure is greater if the neck dissection is carried out prior to the clinical appearance of nodes. Other oral cancers, with a lower expected percentage of metastasis, can be followed for the development of neck nodes without significantly diminishing the possibility of cure.

Lesions involving multiple areas or contiguous structures may require radical procedures, with simultaneous removal of neck contents, jaw, floor of the mouth, full-thickness of the cheek, and the like. It is interesting to note that the rate of cure obtained by these massive procedures for extensive disease is better than expected, probably because of the tendency of such lesions to remain of low grade malignancy despite clinical evidence to the contrary.

If a segment of mandible must be resected, jaw conformation is preserved by means of a stainless steel bar to prevent collapse of the pharynx. This bar need not be removed if it is tolerated by the patient.

From the statistical standpoint, one can expect the 5 year survival of 50 to 60 per cent of all patients with cancers of the buccal mucosa, upper alveolar ridge and hard palate. The percentage falls sharply to not over 25 per cent of those with lesions of the tongue, floor of the mouth, and soft palate.

Cancer of the Salivary Glands

Approximately 20 per cent of parotid tumors are malignant, including malignant mixed tumors, adeno- and squamous carcinoma, cylindroma, and muco-epidermoid carcinoma. These cancers are usually diagnosed correctly preoperatively because of their tendency to involve the facial nerve, to be of relatively short duration, and to be fixed to adjacent structures. They only rarely metastasize to other than the regional nodes.

Surgical excision, with radical removal of the tumor including involved

filaments of the facial nerve, is the treatment of choice. The presence of metastatic glands may require complete neck dissection carried out in continuity with the primary excision. If the facial nerve must be sacrificed, a secondary suspension of the face by fascial strips gives satisfactory relief from the cosmetic and subjective difficulties of the resulting facial paralysis.

Malignant tumors of the submaxillary and salivary gland are treated similarly. Diagnostically, it must be kept in mind that the incidence of malignancy in these tumors is considerably higher than in those of the parotid and the preoperative diagnosis of cancer is made with less certainty.

The prognosis for salivary gland cancer is variable, depending on the histologic type and amount of progression of the tumor beyond the gland. In general, one can anticipate poor results even from radical surgery.