

IDIOPATHIC LETHAL GRANULOMATOUS ULCERATION OF THE NOSE AND FACE*

Report of Six Cases

C. C. WOODBURN, JR., M.D. and H. E. HARRIS, M.D.

Department of Otolaryngology

REPORTS have occasionally appeared in the literature concerning a group of unusual and ultimately fatal cases characterized by nonspecific granulomatous ulcerations of the upper respiratory tract and face. We shall review these clinical features and report 6 cases which we have observed at the Cleveland Clinic over a period of 15 years; 3 of these have terminated in death. In 2 of the 3 patients living the general course has been a gradual decline, characterized by symptoms strikingly similar in various stages to those cases in which the patients died. At the present time one of these patients is apparently well and entirely free from all symptoms. Another is entering the stage of early necrotizing lesions of the nasal septum, while the third is approaching the terminal phase.

In none of our cases has an etiologic agent been found which might possibly account for the severity and relentlessly progressive nature of this affliction despite exhaustive chemical, bacteriologic, and microscopic examinations. Thus we are unable to contribute further to previous investigations of the etiology of these peculiar and devastating lesions. Williams,¹ in his excellent presentation, has summarized the possibilities, many of which we have considered from time to time. That the disorder is perplexing is evidenced by the diversity and multiplicity of diagnostic procedures and therapeutic approaches which have been utilized in an effort to bring the lesions under control.

The onomatology applied to this affliction has varied with different authors. It has been termed "lethal granulomatous ulceration of the midline facial tissues" by Williams,¹ "granulomatous ulcer of the nose and face" by Hoover,² "chronic granulomatous ulcer of the nose of unknown cause" by Isbell,³ "chronic infectious granuloma of the nose" by Lierle,⁴ "gangrenous osteomyelitis of the paranasal sinuses" by Lewy,⁵ "progressive lethal granulomatous ulceration of the nose" by Stewart,⁶ "malignant granuloma of the nose" by Woods,⁷ and "mutilating granuloma of the nose and face with fatal ending" by Wood.⁸ We believe the term "idiopathic lethal granulomatous ulceration of the nose and face" represents the entity most accurately.

Stewart⁶ has given an edifying description of the course of the disease in which he classifies it into three phases based upon symptomatology and pathologic progression. He calls the first the prodromal stage; the second the stage of active disease and the third the terminal stage.

*Awarded first prize for residents at the annual Spring Meeting of the Cleveland Otolaryngological Society, April 4, 1951.

He observes that the prodromal stage is characterized by intermittent nasal obstruction often accompanied by postnasal discharge and a watery or serosanguineous rhinorrhea. Occasionally, however, the disease may be initiated by the appearance of a superficial ulceration in the nasal vestibule or nasal septum. In some patients a history of pre-existing infection of the paranasal sinuses can be obtained. Surgical procedures in the nose usually conclude unfortunately. A perforation of the septum may be anticipated following a sub-mucous resection. The prodromal stage may endure from several weeks to several years.

The "period of active disease" is Stewart's⁶ application to the second stage. In our experience this phase is usually of 10 to 18 months' duration. The characteristic feature is the appearance of a small, shallow ulcer on the nasal septum, inferior concha, floor of the nose or palate, covered with an inspissated crust which, on removal, reveals a denuded surface. The discharge has a fetid odor and is purulent or sanguinopurulent. In general, the lesions tend to invade the interior of the nose from the roof of the mouth, and from inside of the nose erode onto the face. Early in the involvement of the facial tissues, the nose and paranasal structures become indurated and swollen. As the lesion progresses, the palatal, nasal, and malar bones undergo necrosis and sequesterate. Abscesses may develop in the soft tissues. The temperature is irregular, being normal or slightly elevated. The blood condition is of little diagnostic aid. Leukocyte count may be normal, slightly elevated, or show a mild leukopenia; the differential count varies but it is usually normal or returns to normal on repeated examination. Agranulocytosis has never been found, and septicemia is uniformly absent. The most striking observation of this second phase is that, despite the apparent gravity of the destructive lesion, the patient enjoys a sense of well-being except for varying degrees of weakness and lassitude.

The prominent features of the terminal stage, as set forth by Stewart,⁶ are the evident exhaustion of the patient and the extreme mutilation of the advancing lesions. The eyelids are swollen with a purulent discharge exuding from between the lids. The face may be exceedingly disfigured with the development of a large central aperture, through which the violence of the destructive process is readily ascertained. The appearance of the involved area defies accurate description. A fetid odor of putrefaction exudes from the gaping lesion, the margins of which are indurated with rolled, heaped-up tissue. The nasal septum, nasal conchae, and the hard and soft palates may have been obliterated. Often the lateral walls of the nose have been completely eroded baring the pyriform aperture and malar bones. The pharynx and larynx may be extensively necrosed. In the central area of the face only a portion of the fleshy dorsum of the nose may remain; in other cases even this pedicle disappears. Only the tongue and basisphenoid are uniformly spared. The remaining exposed surfaces lining the ulcer are covered with a dirty brown or greenish-brown heavy crust. In most cases there is little oozing through this crust. Recurrent hemorrhage is often troublesome at this stage due to erosion through blood vessels, and this complication may cause sudden death. Usually, however, the fatality results from exhaustion and inanition with terminal temperatures ranging up to 106 or 107 F.

A constant, but unaccountable, observation throughout the entire course of the disease is the complete lack of effective resistance by the usual defensive mechanisms.

Williams¹ feels that the granuloma formation is the "stereotyped defensive mechanism by which the body resists invasion by micro-organisms which are poor toxin producers." He believes that dysfunction of the immunity mechanism with development of localized Arthus phenomena and periarteritis nodosa are the essential factors in granulomatous reaction.

Incidence

Idiopathic lethal granulomatous ulceration of the nose and face affects primarily the age groups between the late second and the seventh decades. Only 2 cases have been reported in children. Men are stricken in the proportion of 20:1 over women.² Our series consists of 4 men and 2 women with ages ranging from 17 to 53.

Pathology

The following report of a typical biopsy specimen taken for microscopic examination from the patient in Case 3 was given by Dr. John B. Hazard, pathologist at the Cleveland Clinic.

"Fragments present broad zones of necrosis. Viable tissue is comprised of a mucosal fragment, noticeably infiltrated by lymphocytes, plasma cells, some neutrophils and eosinophils, and with rather frequent histiocytes. The latter, in one section, appear to form variable-sized accumulations without the appearance of typical tubercles. Histiocytes and fibroblasts marginate zones of necrosis. Occasional mitoses are present, apparently in histiocytic cells. Giant cells of foreign body or Langhans' types are not evident. In one section there are occasional small epithelial islands as well as glandular structures. Necrosis is of infarct and coagulation types. There is deposition of fibrin or fibrinoid material in places.

"Examination of sections stained by Gram-Weigert, Giemsa, and acid-fast methods fail to reveal organisms.

"Diagnosis: Chronic granulomatous inflammation; necrosis. Etiologic agent not apparent. Note: Inflammatory response is rather unusual due to the frequency of histiocytes and the tendency to grouping of these cells. The process does not resemble any of the usual infectious granulomata."

It is interesting to note that, because of the unusual character of the microscopic picture, these sections were later sent to the departments of pathology at North Carolina, Vanderbilt, and Columbia Universities where they were examined by several members of each department. These pathologists were unable to agree on a definite diagnosis. Opinions varied between granulomatous inflammation of unusual type and neoplastic disease.

Diagnosis

Diagnosis of idiopathic lethal granulomatous ulceration of the nose and face is made by history, clinical findings, and exclusion of other diseases causing similar lesions. Those disorders to be eliminated are listed in the following table.

DISEASES TO BE EXCLUDED IN DIFFERENTIAL DIAGNOSIS

- | | |
|-------------------------|--------------------------------------|
| 1. Syphilis | 11. Leprosy |
| 2. Tuberculosis | 12. Glanders |
| 3. Malignant disease | 13. Anthrax |
| 4. Fungus infections | 14. Tularemia |
| 5. Histoplasmosis | 15. Myiasis |
| 6. Leukemia | 16. Yaws |
| 7. Agranulocytosis | 17. Leishmaniasis |
| 8. Diabetic gangrene | 18. Postencephalitic ulcer (trophic) |
| 9. Noma | 19. Mycosis fungoides |
| 10. Erythema multiforme | 20. Wegener's disease |

Report of Cases

Case 1. A white man, aged 31, was first seen in November 1942. He gave a history of recurrent generalized small skin lesions of 10 weeks' duration. About 5 weeks previously he noted the onset of purplish areas on his back which gradually increased in size.

Examination revealed a well-developed and nourished patient in no acute distress. His temperature was normal with a pulse rate of 86 beats per minute and blood pressure of 160/86. The only significant finding was a generalized papular skin rash in which some of the more advanced lesions had ulcerated with resultant serosanguineous discharge. These lesions were of match-head size. In addition there were two larger purplish ulcerations in the left subscapular area. The Kahn test was 4 plus. The patient gave a history of a penile lesion contracted 5 years previously. The papular ulcerations on the body, however, did not have the appearance of late syphilis. The condition was diagnosed as "tuberculids" after a tuberculin skin test proved positive. Antisyphilitic therapy in the form of bismuth subsalicylate and potassium iodide, and tuberculin therapy were initiated simultaneously. Roentgenographic examination of the chest was negative. Blood studies revealed an erythrocyte count of 5,150,000 per cu. mm., hemoglobin concentration of 89 per cent, leukocyte count 8000 per cu. mm. with differential proportions of neutrophils 64 per cent, lymphocytes 31 per cent, monocytes 4 per cent, eosinophils 1 per cent. The sedimentation rate was 0.27 mm. per minute.

The skin lesions appeared to progress despite therapy. Potassium iodide was discontinued, and topical applications of ammoniated mercury ointment were employed. When continued deterioration of the patient's conditions was noted, a biopsy specimen was taken from one of the lesions on the back. The pathologic diagnosis was "inflammatory tissue."

The patient was referred to the Department of Otolaryngology 1 month following his first visit. His complaints at that time were alternate nasal obstruction of 2 years' duration, chronic hoarseness for 3 months, a sensation of pressure beneath the right eye for 1 month, and daily epistaxis for 2 weeks. Examination of the nose and throat

revealed bilateral choanal obstruction due to hypertrophy of the posterior ends of the inferior turbinates. Granular, hemorrhagic areas covered with yellowish-green crusts were present in the nasopharyngeal vault. The vocal cords and subglottic area were diffusely injected and edematous. Clinically, the lesions appeared to be syphilitic or tuberculous in origin.

Mapharsen was added to the antisiphilitic regimen. Repeated sputum examinations were negative for acid-fast organisms. Stereoscopic x-rays of the chest were normal. Over a period of the next several months the patient failed to show general improvement, though there were short periods of mild remission between exacerbations. The entire mucosa in both nasal fossae gradually became involved with granulomatous lesions, and epistaxial episodes increased. A biopsy specimen was removed from the granulomatous area, but the pathologic report was inconclusive except for "inflammatory tissue." A skin test for histoplasmosis was negative. As the disease progressed the patient's throat became sore and he developed hemoptysis. Seven months following his initial visit the patient was admitted to the hospital for intensive sulfonamide therapy and 2 days later developed severe cramping pains with ecchymoses and edema in the legs, ankles, and feet bilaterally. The pain required heavy narcosis for adequate analgesia. The edematous ecchymotic areas on the lower extremities resembled "erythema multiforme" lesions measuring up to 1 cm. in diameter. The Frei test was negative. Sulfathiazole and sulfadiazine therapy were discontinued and neoprontisil was instituted. About 1 month after admission he developed severe diarrhea with temperature to 105 F. An unsuccessful attempt was made to obtain penicillin from the National Research Council.

By this time the patient had complete aphonia. He was given x-ray therapy to the larynx and, despite postirradiation nausea, showed rapid subjective improvement of his voice. His erythrocyte count was 2,800,000 cells per cu. mm. with a hemoglobin concentration of 44 per cent. After receiving two transfusions of whole blood his condition was so much improved that he was discharged from the hospital a few days subsequently following a confinement of about 10 weeks. Clinical examination 2 weeks later disclosed that the patient had experienced no further episodes of hemoptysis. Moderate crusting was still present in the nose, but the nasopharynx and larynx appeared almost normal. In the interim following discharge from the hospital the patient had developed polydipsia and polyuria without hematuria. Urine examination revealed a trace of albumin. Microscopic study showed many erythrocytes, leukocytes, and casts. The Kahn test was negative, and the red blood count was 3,500,000 per cu. mm.

Four weeks later the patient was again examined in the Department of Otolaryngology where he was found to have had a severe exacerbation of his previous upper respiratory symptoms. Intermittent hemoptysis and pronounced hoarseness had recurred. The crusting in the nose, pharynx, and larynx was heavy with a fetid odor. Despite his obvious deterioration the patient enjoyed a sense of well-being and had gained 25 pounds since his discharge from the hospital. He was placed on potassium permanganate nasal sprays every 2 hours. Two days later the patient was stricken with acute abdominal pain in the umbilical area with radiations to the epigastrium and hypogastrium. His temperature rose to 102 F. A spinal puncture was negative. Urine examination again revealed casts, red, and white cells in heavy concentrations. On readmittance to the hospital the diagnosis was chronic glomerulonephritis with secondary anemia. The purpuric lesions of the skin recurred. A gastrointestinal series revealed a "spectacular lesion consisting of generalized, soft infiltration, probably edema, of the upper small intestine, suggesting numerous possibilities." Studies of the sternal bone marrow were negative. Although he was given further whole blood

transfusions and neoarsphenamine his condition rapidly became hopeless and he died 3 weeks after admission.

A necropsy was performed, and the final pathologic diagnoses were: chronic glomerulonephritis with superimposed acute pyelonephritis; acute necrotizing arteritis involving kidneys, skeletal muscle, lungs, esophagus, and small intestine; nonspecific granulomatous ulcers of the nose, nasopharynx, pharynx, and larynx; acute pericarditis and terminal bronchopneumonia.

Case 2. A 26-year-old white man was first observed because of swelling, pain, and obstruction of the left nasal cavity, accompanied by headaches and fever.

Two years prior to admission, while stationed in the Azores, he had experienced daily febrile episodes. He was told that he had asthma and "bad nerves," and was discharged from service because of these complaints. He continued to have daily elevations of temperature to 104 F.; these had been accompanied by chills except when the fever exceeded 102 F. For one year previous to our examination he had noted headaches limited to the entire left side of the head, relieved by lying down for about 5 minutes. There were no associated episodes. Nasal swelling followed a blow on the nose one month prior to entry. Previously he had experienced partial nasal obstruction on the left which subsequently increased in severity. Constant right subcostal pain had been present for 4 years; cholecystograms and barium enema studies had been negative. There were no other complaints referable to the gastrointestinal system. He had experienced seasonal pollinosis.

Physical examination revealed a fairly well-developed man weighing 158 pounds (normal 165). His temperature was 100 F., pulse rate 108 beats per minute, blood pressure 120/88. The nose was enlarged externally and somewhat deformed, the swelling simulating a hematoma. On the left near the base a light red, poorly demarcated, scaly plaque was evident. The lesion extended over the bridge and for a slight distance on the right of the nose. There was chronic edema of infraorbital tissues. No rolled border was present on the inflammatory area. The nasal septum was noticeably deviated. The left naris was tender and completely obstructed with warty excrescences and granulation tissue; the right fossa was 90 per cent obstructed. The tonsils were enlarged and the soft palate injected. Several tender right submaxillary and right deep cervical nodes were palpable. There was slight tenderness to deep bimanual palpation of the right flank.

A urinalysis was negative. The erythrocyte count was 5,200,000 cells per cu. mm. with a hemoglobin concentration of 14. Gm. per 100 cc.; the leukocyte count was 13,850 cells per cu. mm. with 71 per cent neutrophils. A blood sugar was 112 mg. per cent. Serology test was normal; a lumbar puncture revealed normal dynamics and spinal fluid.

He was treated as an outpatient for 3 months and given local applications of hot magnesium sulfate packs. Two months before hospital entry he experienced pronounced pain, swelling, and warmth of both knees for which he was given sulfadiazine. Although the joint pains subsided, his temperature continued to reach 103 F. Quinine had no effect, and the swelling over the nasal bones persisted and became worse.

Three months after the first visit, the patient was admitted to the Cleveland Clinic Hospital for penicillin therapy for the fever and the verrucous lesion of the nose. At this time there was redness and swelling over the left side of the nose and infraorbital area without a break in the skin or rolled margins. The acute swelling of the infraorbital tissues had existed for 10 days. A large, nontender lymph node was present in the left submaxillary region and a similar node was palpated in the left axilla.

Urinalysis was again negative. The white cells numbered 11,900 per cu. mm. with 70 per cent neutrophils and the red cells 5,200,000 per cu. mm. Examination of the

feces was negative for ova or parasites. An agglutination test was negative for tularemia. A heterophil antibody test was positive at dilution 1:16. Blood culture was negative. No malarial parasites could be demonstrated. A brucellergen skin test was negative. Nasal cultures were positive for nonhemolytic streptococcus, *Staphylococcus albus*, and diphtheroid bacilli; on two occasions organisms reported as *K. L. bacilli* were found and in one instance pseudodiphtheria organisms, "*Hoffman's bacillus*," were cultured. Roentgenographic examination of the sinuses showed an increased density at the inferior angle of the right antrum. The left antrum, the sphenoid, ethmoid, and frontal sinuses were negative. Examination of the nose revealed a slight deviation of the nasal septum to the left without evidence of old fracture or osteomyelitis. The right antrum contained thickened membrane. Roentgenographic studies of the skull and chest were normal. Biopsy specimens taken from the skin of the left side of the nose and a lymph node in the right axilla were reported as "chronic inflammation, granulomatous type."

While in the hospital the patient received penicillin every 3 hours (50,000 units) for 1 week without effect on the fever, which followed a septic course. Two intravenous injections of neoarsphenamine were given at weekly intervals without relief. Fifty thousand units of diphtheria antitoxin were also administered without change. The patient's headaches continued, accompanied by stiffness of the neck. He gradually became worse with increased swelling and tenderness of the nose, enlargement and tenderness of the cervical, axillary, and inguinal nodes, and continued sepsis. The patient remained in the Cleveland Clinic Hospital for 6 weeks, at the end of which time he was transferred to a veterans' hospital. There he continued a febrile course with progression of the local lesion and ulceration of the nares. He died 3 weeks after admission. No autopsy was performed.

Case 3. A 17-year-old white girl was examined because of chronic nasal obstruction, excessive nasal crusting, and episodes of epistaxis which had been present since a severe case of scarlet fever at the age of 5. Two years previous to this visit she developed aphonia and extreme dyspnea. She was admitted to a hospital where her symptoms subsided under oxygen therapy. Her aphonia continued following discharge, and 3 months later she was again admitted to the hospital because of recurrent dyspnea. A tracheotomy was performed for tumor of the larynx. A biopsy of the laryngeal tumor was reported as squamous cell papilloma. Despite continued aphonia she was able to be decannulated after 2 months. Eleven months later she developed "flu and virus pneumonia" with subsequent dyspnea and was again hospitalized for 30 days. The vocal cords were extensively scarred, and the papillomatous process extended into the trachea. The laryngeal cicatrix was partially removed with immediate relief of the patient's dyspnea and she was referred to another hospital for evaluation. Her trouble was considered due to fungus disease because she responded well to potassium iodide therapy, whereas the laryngeal edema was not affected by sulfonamide or penicillin therapy. Three months prior to our examination the patient developed febrile episodes attributed to the apparent infectious process in the nose. Although there was no objective improvement in these lesions following bed rest, nasal sprays, and penicillin, the patient felt much better temporarily. Five weeks before she was referred to the Clinic a slightly tender and painful external swelling developed in the left ethmoidal area.

Physical examination revealed a slightly emaciated, but well-developed and nourished young woman in no acute distress. Her temperature was 98.6 F., pulse rate 80 beats per minute, blood pressure 120/70. Both nasal fossae contained boggy, granular-appearing turbinates covered by a greenish, tenacious crust which, when removed, revealed raw, denuded bleeding areas. A papillomatous type growth was evident in the left naris. Externally, a slightly reddened area of swelling without break in the skin was noted in the left ethmoidal region. Foul smelling purulent discharge was present in the

nasopharynx. The larynx was infantile and noticeably edematous and injected. The remainder of the general physical examination revealed no significant abnormalities.

A urinalysis was negative. Hematology studies revealed 4,100,000 erythrocytes per cu. mm. with a hemoglobin concentration of 11.5 Gm. per cent, 3,600 leukocytes per cu. mm. The differential proportions were: 45 per cent neutrophils, 37 per cent lymphocytes, 10 per cent monocytes, 1 per cent eosinophils, and 7 per cent nonfilamented neutrophils. The sedimentation rate was elevated to 1.35 mm. per minute. A blood sugar was 96 mg. per cent. The serology was normal. The Frei test was negative as were agglutination tests for tularemia, typhoid, and paratyphoid; tuberculin and histoplasmin skin tests were negative. Blood culture was sterile. Cultures from the nasal lesions revealed the presence of nonhemolytic streptococcus, *Staphylococcus albus*, diphtheroids, *Micrococcus catarrhalis*, spirochetes, and fusiform bacilli. A biopsy specimen removed from the nose was diagnosed as "chronic granulomatous inflammation; necrosis. Etiologic agent not apparent."

The patient was admitted to the Cleveland Clinic Hospital for further evaluation and treatment. She was given massive doses of penicillin and streptomycin together with sulfadiazine and urea (10 Gm. four times a day). Inflammatory doses of x-ray therapy were given to the facial and left cervical areas. The patient's condition continued to deteriorate with gradual increase of fever which spiked to 104 F. The nasal lesions showed no signs of regression. After 3 weeks in the hospital she had lost 18 pounds; her total weight was 88 pounds. At this time she had developed a severe leukopenia (1,500 white blood cells per cu. mm.) and anemia (9.0 Gm. per cent on hemoglobin concentration). She was given two whole blood transfusions, neoarsphenamine, and four injections of nitrogen mustard. The disease was refractive to all therapy, and the patient continued a rapid downhill course, showing evidence of complete exhaustion. Her terminal temperature rose to 106.4 F., and she died 6 weeks following admission (fig. 1a and b).

An autopsy was performed and the final diagnoses were: necrotizing and ulcerative rhinitis, nasopharyngitis, and laryngitis with necrosing lesion of the hard palate; chronic inflammation of the sphenoid and left ethmoid sinuses; pronounced granulopoietic hypoplasia of bone marrow; terminal bronchopneumonia of the right lower lobe and partial atelectasis of the left lower lobe. The internal organs were entirely normal, showing no evidence of primary or secondary manifestations which could explain the involved tissues of the face and upper respiratory tract.

Case 4. A 19-year-old white youth was referred to the Cleveland Clinic because of a history of recurrent head colds and a progressive swelling under the right eye and root of the nose, symptoms which had been present for 9 months; there was no history of illness or injury at onset. Three months prior to his first visit he had consulted a local physician for treatment of these symptoms after which a right intranasal antrotomy, ethmoidectomy and submucous resection were performed. A week later the patient underwent a tonsillectomy. Two hundred roentgen units of x-ray therapy were given on the face over the swollen area. Six weeks later the patient was readmitted to the local hospital because of sore throat, dysphagia, and odynophagia. He was found to have induration of the hard and soft palates and an ulceration in the oropharynx. A biopsy taken from the latter area was reported as "epidermoid carcinoma, grade I." Subsequent biopsy specimens were negative for neoplasm.

All blood studies had been negative. Cultures from the pharyngeal lesion had revealed the presence of "streptococci." He had been given penicillin, mercurochrome, and iodine drops without relief. There had been no febrile episodes.

Otolaryngologic examination disclosed crusting of the right nasal vestibule with

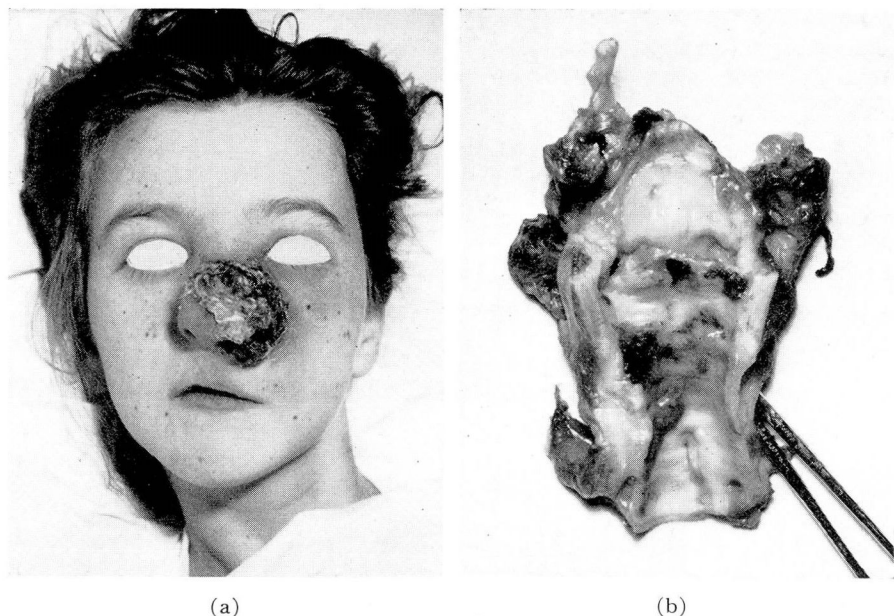


FIG. 1. Patient in terminal stage showing (a) extensive necrosis of nose and edema of facial tissues on left; three weeks prior to photograph patient had no ulceration on external surface; (b) ulceration and granulation of vocal cords in larynx opened posteriorly.

mucopurulent discharge in the right nasal cavity. The mucous membrane was significantly injected. Inspissated mucous filled the nasopharynx. In the tonsil fossae and oropharynx multiple, small, pitted, shallow, bluish-red ulcers were present. A large multiform ulceration of similar appearance was found on the hard palate and several smaller ulcerations involved the soft palate. Beneath the right eye and involving the inner canthus was a swollen area covered with a brownish crust. Nonpitting edema extended laterally to the lateral canthus along the lower eyelid and a slight edema of the upper lid was noted. The lesions were nonpainful but slightly tender. No lymphadenopathy was present. The temperature was 100 F., with a pulse rate of 160 beats per minute (fig. 2).

A urinalysis was negative. Blood studies revealed 5,500,000 red cells per cu. mm.; the hemoglobin content was 13.5 Gm. per cent; 6,700 white cells per cu. mm. with essentially normal differential proportions. The sedimentation rate was elevated to 0.96 mm. per minute. Serology was negative. Roentgenographic examination showed clouding of all sinuses on the right; the chest was normal. Agglutination series for undulant fever, typhoid, paratyphoid, and tularemia were negative, as were the Frei test, tuberculin and histoplasmosis skin tests. Blood culture was sterile. Smears and cultures from the lesions on the face and nasal mucous membrane revealed the presence of *Staphylococcus aureus* and diphtheroids. Biopsy specimens taken from the face and nasal areas were diagnosed as atypical granulomatous inflammation with pseudoepitheliomatous hyperplasia.

The patient was admitted to the Cleveland Clinic Hospital for antibiotic and chemotherapy consisting of dihydrostreptomycin, duomycin, and sulfadiazine. After

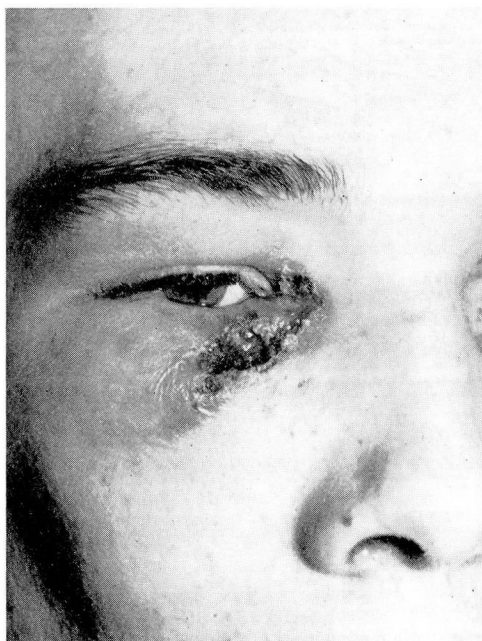

FIG. 2. Showing chronic ulceration of inner canthus and lower eyelid; ulcer of 6 weeks' duration.

6 weeks confinement the facial lesions had improved somewhat but the oral lesions appeared slightly worse. As the prognosis was apparently hopeless, he was discharged. After the patient returned home he consulted a local physician, who, by his own admission, has "cured several hundred cases of external cancer after surgery and x-ray treatments had failed." This doctor reported to us that he cured the facial lesion as follows: The skin surrounding the lesion was divided by sharp dissection "to a point one-half to two-thirds of the distance behind the ulcer. This leaves a flap behind which is placed cotton containing 30 per cent arsenous acid in diathane ointment. In a few days the entire ulceration sloughs away leaving healthy granulation tissue." He sent photographs to show the completely healed area which left only a minor cosmetic defect. The oral lesions proved much more refractive to therapy. The local doctor tried ultraviolet light and later zinc chloride ointment without success. Then he employed fuming nitric acid directly on the ulcers, but discontinued this form of treatment because of the intense irritation caused by inhalation of the fumes. He then applied 25 to 50 per cent lactic acid. This agent ate through the palate, but, according to the doctor, healthy granulation appeared here also with ultimate healing of the lesions; the palate, however, was largely destroyed. The patient was subsequently fitted with a prosthetic appliance. He gained 37 pounds in a short time. When last reported 2 years ago he was apparently well and entirely free from symptoms. We have been unable to obtain further progress records as contact has been lost, unfortunately, with both the patient and the local doctor.

Case 5. A 53-year-old white man was seen in the Department of Otolaryngology

with a history of chronic nasal obstruction and troublesome brownish and greenish crusting in the nose of 9 years' duration. The onset of his illness followed a gastro-enterostomy after which a Wangenstein tube was introduced through the nose and left in place for several days. Shortly afterwards he consulted his local physician who prescribed nose drops and nasal packs. He had no further treatment until 6 years later when he was treated with nasal irrigations and sprays. Two years subsequently and 1 year prior to his first Clinic visit, he experienced anosmia. Three months before entry a fetid odor developed which had gradually become increasingly offensive. One month later he underwent a right Caldwell-Luc procedure with removal of polyps. Chloromycetin was administered with no alleviation. Four days prior to our examination he developed epistaxis from the left nasal fossa.

Otolaryngologic examination revealed a foul smelling greenish-brown heavy crust covering the entire mucosal surfaces of both nasal fossae and the nasopharynx and a large anterior septal perforation with a posterior erosion extending along the vomerine ridge for a distance of about 2 cm. behind the larger anterior perforation. The right inferior turbinate and lateral nasal wall had been completely eroded baring the pyriform aperture on that side. A peculiar type of granulation tissue was present in the right side of the nasopharynx. The crusts were tenacious and when pulled away left bleeding areas in the underlying tissue. There was a slight swelling on the face lateral to the nose without discoloration or dehiscence of the skin. Despite the obvious gravity of his condition the patient was not uncomfortable. His temperature was normal (fig. 3).

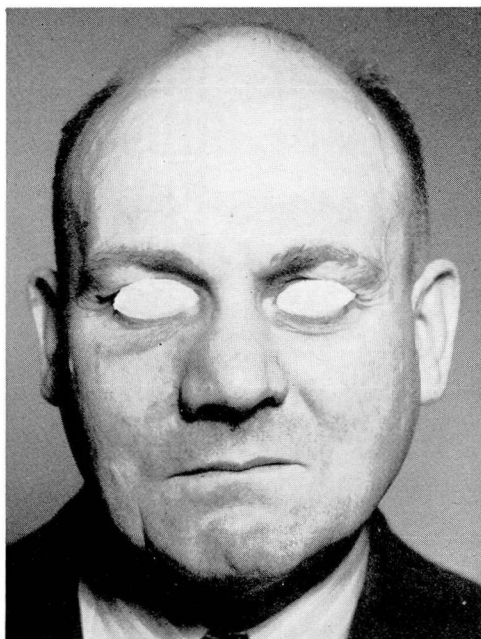


FIG. 3. External swelling of right lateral wall of nose. Internal ulceration extensive with erosion of nasal septum, middle and inferior turbinates, and lateral nasal wall baring the pyriform aperture.

Roentgenographic studies of the paranasal sinuses revealed a cloudy right antrum. The other sinuses were normal. Blood examination revealed 4,700,000 red cells per cu. mm. with a hemoglobin concentration of 11.5 Gm. per cent; 4,500 leukocytes per cu. mm. with normal differential proportions. Serology was negative, and blood sugar within normal limits. Cultures from the nose revealed the presence of *Streptococcus hemolyticus*, *Staphylococcus albus*, and the colon bacillus. A biopsy specimen was reported as "chronic inflammation."

The patient was treated with salt and soda nasal irrigations, oil of Thuja and Blandine compound sprays, and cortisone spray in the dilution of 1:4. He showed no improvement on this regimen. More recently he has been hospitalized and has improved noticeably on adrenocorticotrophic hormone (ACTH). At present, however, complete remission of the lesions has not occurred following 2 weeks of this therapy.

Case 6. A 42-year-old white woman was first seen in the Department of Otolaryngology because of chronic nasal congestion, postnasal discharge, pressure sensations over the bridge of the nose and frontal areas, and frequent head colds of 8 years' duration. All of these symptoms were aggravated by inclement conditions of the weather. Otolaryngologic examination revealed hypertrophy of the nasal conchae with pale, edematous mucosa, hypertrophy of the adenoid and a devitalized tooth. A diagnosis of perennial allergic rhinitis was made. The affected tooth was later removed by a local dentist. X-ray examination of the paranasal sinuses was negative. The patient returned to the Clinic about a year later with no improvement of symptoms and was referred to the Department of Allergy where she was found to react to household dust and inhalants. She was started on a course of desensitization injections which she voluntarily discontinued after a short period. We subsequently performed an adenoidectomy but this procedure also failed to offer relief. The patient was next seen 7 years later with a chief complaint of deafness which had occurred 7 weeks previously. A diagnosis of otosclerosis was made. Her nasal symptoms were still present. She was examined 3 months later at which time she gave a 3 weeks' history of serosanguineous discharge from the right nasal fossa. Nasal examination revealed bilateral ulceration on the basilar septal ridges.

Blood studies revealed 4,600,000 red cells with a hemoglobin concentration of 12.5 Gm. per cent; 9,950 leukocytes per cu. mm. with normal differential proportions. The serology was negative and blood sugar was well within normal limits. Smears and culture of the nasal lesion revealed colon bacillus and *Staphylococcus albus*. Sulfathiazole ointment, penicillin, and aureomycin were ineffectual, although Gantrisin seemed to improve the lesions.

Subsequently the patient suffered a relapse and was observed elsewhere. She was given nicotinic acid and experienced a rather long period of remission on this therapy. A few months later, however, the septal lesions recurred actively. She was given cortisone which resulted in almost immediate amelioration and apparent cure. Within several months, following discontinuance of this agent, the ulcerations again returned. She is once more receiving cortisone, but the general course of the disease has been one of deterioration.

We have observed an additional case in a 49-year-old white man who presents an unusual history of alternate ulcerative involvement of the right and left lateral pharyngeal walls. The ulcerations have been undergoing spontaneous remissions following unilateral involvement lasting several months, only to result in a breakdown of the same or opposite wall. His relapses have been recurring with increasing frequency and violence. The ulcers are shallow and

extend from the lower lateral nasopharynx to the vallecula and aryepiglottic fold, involving the ipsilateral half of the epiglottis. The ulcers are covered with a white pseudomembrane. Pain is present but not particularly aggravating. As a result of the repeated ulcerative episodes about 70 per cent of the epiglottis has been eroded. Biopsies of the lesions have been inconclusive on microscopic examination and diagnosed as "chronic granulomatous inflammation." His general condition has been one of gradual deterioration. After the failure of several forms of therapy, he has recently been given a course of cortisone with a partial remission. A small area behind the right posterior pillar still persists following several weeks of treatment with this agent. Because of the atypical nature we have not included this with the case reports. We believe, however, that it probably represents an instance of idiopathic lethal granulomatous ulceration involving only the pharynx and larynx.

The ultimate roles of cortisone and ACTH in the treatment of idiopathic lethal granulomatous ulceration of the nose and face must be more fully evaluated. To date this corticoid of the adrenal gland and the stimulating hormone yielded by the anterior lobe of the pituitary gland appear to offer the only effective remedial agents available to the clinician. Our brief experience with these agents, however, indicates that, though improvement may occur, a cure probably cannot be obtained even with these forms of therapy. Whether repeated courses can adequately control the lesions so that the patient may have a normal life span must be determined. Since all previous therapeutic approaches have failed to result in a cure of this unusual disorder, the prognosis should be regarded with extreme pessimism and, until the nature has been established, the treatment must, of necessity, be empirical.

Summary

The clinical features of idiopathic lethal granulomatous ulceration of the nose and face have been described; the etiology remains undetermined notwithstanding exhaustive diagnostic efforts to isolate a causative agent. Six cases which we have observed during the past 15 years have been reported. Three of these have terminated fatally; 2 patients are in a state of deterioration, and one with whom we lost contact was reported as well and symptom-free. Therapy has been discussed briefly. Cortisone and ACTH appear to be the only therapeutic agents of value at the present time and, since they may effect only temporary remission of the lesions, their significance has yet to be fully assessed. It is our impression that a therapeutic agent for effective cure remains to be discovered and, as other authors have pointed out, much investigative work must be done in establishing the etiology of this affliction.

References

1. Williams, H. L.: Lethal granulomatous ulceration involving midline facial tissues. *Ann. Otol., Rhin., and Laryng.* 58:1013 (Dec.) 1949.
2. Hoover, W. B.: Granulomatous ulcer of nose and face of unknown cause, usually progressive, gangrenous and fatal. *Arch. Otolaryng.* 34:865 (Nov.) 1941.

3. Isbell, D.: Chronic granulomatous ulcer of nose of unknown cause. *Ann. Otol., Rhin., and Laryng.* **52**:501 (June) 1943.
4. Lierle, D. M.: Chronic infectious granuloma of nose. *Arch. Otolaryng.* **36**:940 (Dec.) 1942.
5. Lewy, A.: Case of gangrenous osteomyelitis of paranasal sinuses. *Arch. Otolaryng.* **27**:91 (Jan.) 1938.
6. Stewart, J. P.: Progressive lethal granulomatous ulceration of nose. *J. Laryng. and Otol.* **48**:657 (Oct.) 1933.
7. Woods, R.: Malignant granuloma of nose. *Brit. M. J.* **2**:65 (July 16) 1921.
8. Wood, G. B.: Case of mutilating granuloma of nose and face with fatal ending. *Tr. Am. Laryng. A.* **53**:63, 1931.